

Congenital Cystic Adenomatoid Malformation (CCAM) of Lung in an Infant: A Case Report from Jammu & Kashmir, Northern India

Sudesh Singh¹, *Imran Gattoo², Sanjeev Digra¹, Saloni Bakshi¹

¹ Government Medical College, Jammu, J&K, India

² Government Medical College Srinagar, J&K India.

Abstract

Congenital Cystic Adenomatoid Malformation (CCAM) is a rare developmental abnormality of the lung occurring in 1-4 / 100,000 live births. In most cases the outcome of a fetus with CCAM is very good whereas in some cases it can be life threatening for the fetus. We report here a case of 40-day-old female baby with features of respiratory distress since birth and X-ray chest suggestive of large cystic lesion of left lung CCAM.

Key Words: CCAM, Cystic lesion, Respiratory distress.

***Corresponding Author:**

Imran Gattoo, MD, Government Medical College, Srinagar, J&K, India.

E-mail: immz24@gmail.com

Received date: Feb 12, 2015 Accepted date: Mar 22, 2015

Introduction

Congenital Cystic Adenomatoid Malformation (CCAM) is a rare abnormality of lung development. CCAM is cystic area within the lung that stems from abnormal embryogenesis (1). The fundamental pathological feature of the lesion is adenomatoid proliferation of bronchioles that form cysts at the expense of normal alveoli. CCAM is usually discovered in neonates because of respiratory distress and may occasionally be discovered in older children or adults who have recurrent infection (2).

Three histologic patterns have been described. Type 1 (50%) is macro cystic and consists of a single or several large (>2 cm in diameter) cysts lined with ciliated pseudostratified epithelium. The wall of the cyst contains smooth muscle cell and elastic tissue. One third of cases have mucus secreting cells. Cartilage is rarely seen in wall of cyst. This type has usually good prognosis for survival. Type 2 (40%) is micro cystic and consists of multiple small cysts with histology similar to that of the type 1 lesion. Type 2 is associated with other congenital anomalies and carries a poor prognosis. In Type 3 (40%) the lesion is solid with bronchiole like structures lined with cuboidal ciliated epithelium and separated by areas of non-ciliated cuboidal epithelium. This lesion carries poorest prognosis and can be fatal. Prenatal ultrasonographic findings are classified as macro cystic (single or multiple cysts >5mm) or micro cystic (echogenic cysts <5mm). The pathophysiologic effects of CCAM may be divided into prenatal and postnatal effects. Large lesions may be associated with the development of hydrops fetalis in as many as 40% cases and is a poor prognostic sign. Hydrops is thought to arise from compression of the inferior vena cava (3). Polyhydramnios has also been associated with CCAM. This develops as a result of elevated intrathoracic pressure that leads to

esophageal compression and the inability to swallow the amniotic fluid (4).

CCAM may remain undiagnosed until it is discovered as an incidental finding later in life, however it is usually detected postnatally and presents as respiratory distress in the newborn period. This may be due to pulmonary hypoplasia, mediastinal shift, spontaneous pneumothorax, and pleural effusions secondary to hydrops. Recurrent chest infections may be a feature later in life (5). A risk of malignant transformation in later year is also noted (6).

Case Report

A 40 days old female baby with weight was 3.5 kg, height 54 cm and head circumference 37 cm, presented with chief complaints of fast breathing since birth, which was gradual in onset and more during feeding and non-progressive in nature.

There was no history of cyanosis, vomiting, decreased feeding, loose motions, abnormal body movements, fever or bleeding from any site. There was no history of perinatal hypoxic insult, prolonged labour, meconium aspiration. Baby was admitted at 5 days of age for neonatal hyperbilirubinemia, and received phototherapy. Antenatal history of the mother was uneventful.

On examination, baby had respiratory distress (Respiratory rate >70/minute) and air entry was significantly decreased on left side of chest. Percussion note was hyper resonant. X-ray chest was done, and was suggestive of pneumothorax like picture on left side with mediastinal shift to right side. So a preliminary impression of pneumothorax was made and patient put on tube thoracostomy. Chest tube was kept in situ for week, but patient did not showed any significant improvement in respiratory distress or air entry. Repeat X-rays chest after chest tube removal was

similar to previous X-rays, with mediastinal shift. So computerised tomography (CT) chest was done, which was suggestive of cystic lesion in left lobe and was described by radiologist as congenital adenomatoid malformation Type 1. Patient was referred to Pediatric surgical side and was further managed there with lobectomy and removal of cystic lesion. Post operative course remained uneventful and patient showed marked improvement in respiratory distress and air entry on left side. Patient is in regular follow-up of our Pediatric Surgery Department (Figures 1, 2).

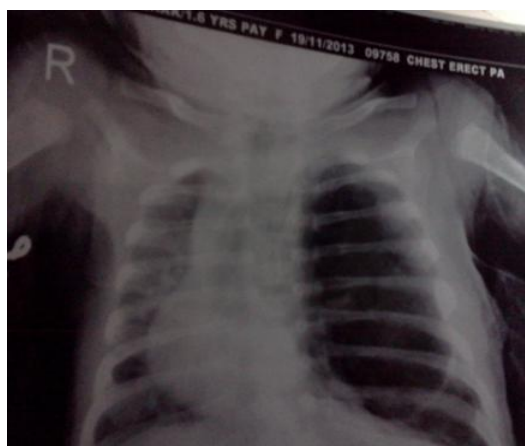


Fig.1: X-ray with large cystic lesion of the left lung

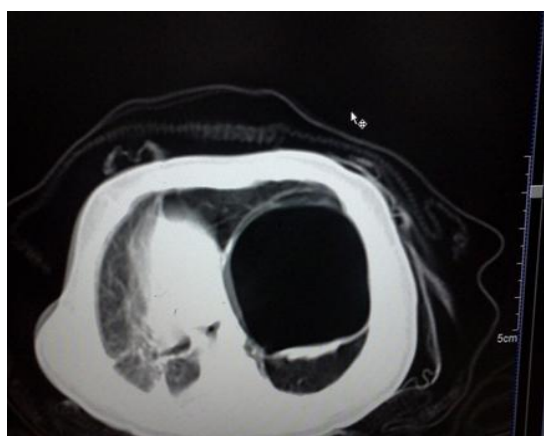

Fig.2: CT Scan with CCAM left lung involving entire lobe

Discussion

Congenital cystic adenomatoid malformation is an uncommon congenital malformation of the lung that arises from excessive disorganised proliferation of tubular bronchial structures excluding the alveoli. The left lung is involved as often as the right lung with single lobe disease observed four times more often than multilobe disease. Cases are typically identified prenatally by routine ultrasonography screening (7). Most postnatally identified cases present in the newborn period. The most common mode of presentation is acute respiratory distress secondary to the cyst expanding and compressing its surrounding structures. The distress occurs through a ball-valve mechanism leading to air trapping. This mode of presentation is common during the neonatal period. Child may also present with recurrent infection, hemoptysis, dyspnea, chest pain, cough, fever, failure to thrive and on examination tachypnea, pneumothorax, cyanosis, accessory muscle use, grunting may be present. It may remain asymptomatic and be discovered later in life on routine chest films or present after the neonatal period as recurrent pneumonia (8). CCAM may present in the older child and adults as an incidental finding or secondary to repeated infection (5,9). Complications like fetal death, premature delivery, recurrent pneumonia, hemothorax, malignant change can occur. In imaging studies chest radiography, CT scanning, Magnetic Resonance Imaging (MRI), prenatal ultrasonography and renal, cerebral ultrasonography and echocardiography in newborns may be done as indicated.

Pulmonary resection during infancy is associated with low morbidity and mortality rates and may prevent the late complications of infection and occult malignant transformation (10). In lobectomy the remaining lung grows and expands well enough so that the total lung

volume and pulmonary function tests return to normal. To conclude, early recognition and surgical treatment of CCAM is essential to prevent the consequences of recurrent pulmonary infections and the potential risk for malignant transformation. The treatment of CCAM is always surgical. Thoracotomy and delivery of the hyperinflated lobe into the wound brings immediate relief of the ventilatory and circulatory problems. Lobectomy is usually necessary, but segmental resection is occasionally feasible (11). There is agreement between surgeons regarding the treatment of symptomatic patients, but controversy exists about the management of asymptomatic neonates and infants with CCAM with respect to the decision and timing of an excision (12).

Conflicts of interest: None.

Authors Contribution

All authors contributed together in patient evaluation, doing investigations, data compiling and cross checking references. All authors read and approved the final manuscript.

Acknowledgment

Authors want to thank the parents who consented for the case reporting of their child. Written informed consent was obtained from the parents for allowing the case reporting of their child .

References

1. Wilson RD, Hedrick HL, Liechty KW, Flake AW, Johnson MP, Bebbington M, et al. Cystic adenomatoid malformation of the lung: review of genetics, prenatal diagnosis, and in utero treatment. *Am J Med Genet A* 2006; 140(2):151-55.
2. Kim WS, Lee KS, Kim IO, Suh YL, Im JG, Yeon KM, et al. Congenital Cystic Adenomatoid Malformation of the Lung: CT-Pathologic Correlation. *AJR Am J Roentgenol* 1997;168(1):47-53.
3. Adzick NS, Harrison MR, Crombleholme TM, Flake AW, Howell LJ. Fetal lung lesions: management and outcome. *Am J Obstet Gynecol.*179(4):1998;884-9.
4. Adzick NS. Management of fetal lung lesions. *Clin Perinatol* 2009; 36(2):363-76.
5. Luján M, Bosque M, Mirapeix RM, Marco MT, Asensio O, Domingo C. Late onset congenital cystic adenomatoid malformation of the lung. Embryology, clinical symptomatology, diagnostic procedures, therapeutic approach and clinical follow-up. *Respiration*2002;69(2):148-54.
6. Sauvat F, Michel JL, Benachi A, Emond S, Revillon Y. Management of asymptomatic neonatal cystic adenomatoid malformation. *J Pediatr Surg* 2003; 38(4): 2003; 548-52.
7. Laberge JM, Flageole H, Pugash D, Khalife S, Blair G, Filiatrault D, et al. Outcome of the prenatally diagnosed CCAM: a Canadian experience. *Fetal Diagn Ther* 2001;16(3):178-86.
8. Sindhwani G, Whig J, Gupta A, Rawat J. Tuberculosis in congenital adenomatoid malformation: a rare presentation. *Lung India* 2007;24(4):148-9
9. Parikh D, Samuel M. Congenital cystic lung lesions: is surgical resection essential? *Pediatr Pulmonol* 2005; 40(6): 533-7.
10. Miller JA, Corteville JE, Langer JC.. CCAM in the fetus; Natural History and Predictors of outcome. *J Pediatr Surg* 1996; 31(6):805-8
11. Heij HA, Ekkelkamp S, Vos A.. Diagnosis of CCAM of the lung in newborn infants and children. *Thorax* 1990; 45(2):122-5.
12. Gardikis S, Didilis V, Polychronidis A, Mikroulis D, Sivridis E, Bougioukas G, et al. Spontaneous Pneumothorax resulting from CCAM in a pre-term infant: Case report and literature review. *Eur J pediatr Surg* 2002;12(3):195-8.