

## Recurrent Ovarian Torsions in a Nine Months Period in a 7-year-Old Girl: A Case Report

Tahereh Behrozi-lak<sup>1</sup>, Haleh Ayatollahi<sup>2</sup>, \*Leila Zarei<sup>2</sup>

<sup>1</sup>Reproductive Health Research Center, Gynecology Department, Urmia University of Medical Sciences, Urmia, Iran.

<sup>2</sup>Solid Tumor Research Center, Urmia University of Medical Sciences, Urmia, Iran.

### Abstract

Ovarian torsion (adnexal torsion) is an uncommon disorder in pediatrics and should be considered as a differential diagnosis of abdominal pain in preteen girls. Almost 70% of ovarian torsions are seen in young girls older than 20 years, but it could also occur in preteen girls. Sonography is one of the most useful methods to diagnose ovarian torsion. In pediatrics, ovarian torsion should be treated laparoscopically by detorsion.

The case was a seven-year-old girl, who experienced ovarian torsion twice in one of her ovaries in the course of nine months. The main complaint of the patient was abdominal pain with vomiting. However, the fallopian tube was normal. Surgical procedure led only to detorsion of ovary.

**Key Words:** Children, Girls, Recurrent, Ovarian torsion.

\*Please cite this article as: Behrozi-lak T, Ayatollahi H, Cyrus Rezai N, Zarei L. Recurrent Ovarian Torsions in a Nine-Months Period in a 7-years Old girl: A Case Report. Int J Pediatr 2018; 6(2): 7039-44. DOI: **10.22038/ijp.2017.26422.2265**

---

### \*Corresponding Authors:

Leila Zarei, Solid Tumor Research Center, Urmia University of Medical Sciences, Urmia, Iran.

E-mail: leilazarei412@gmail.com

Received date: Oct.21, 2017; Accepted date: Dec.22, 2017

## 1- INTRODUCTION

Ovarian torsion is an uncommon disorder in pediatric ages. Approximately 15% of all ovarian torsions occur during childhood and more than 70% occur during the reproductive period of women from about 20–40 years of age. (1). Incidence of ovarian torsion is reported to be as low as 4.9 cases per 100,000 women between one to 20 years (2). The exact incidence of ovarian torsion in pediatric age is unknown. In 1996, less than 300 cases were reported worldwide (3).

The diagnosis of ovarian torsion is difficult because it has non-specific symptoms such as gastroenteritis, pelvic pain, ovarian cysts, and other abdominal differential diagnosis (4). Ovarian torsion in the pediatric age is not a common cause of acute abdominal pain and occurs in just 3% of all cases of acute abdominal pain (5). Ovarian torsion occurs widely in ovaries filled with masses such as cysts and neoplasms (6). Ovarian torsion happens more commonly in the right ovary and could arise from the reducing movement of the sigmoid colon on the left side along with the increasing movement of the cecum on the right side (7).

The importance of correct diagnosis is clear because the missed diagnosis of ovarian torsion may result in the tragic disaster of infertility (4). Ultrasound is one of the most useful and helpful methods to detect ovarian torsion (8). Although ovarian torsion is an uncommon disorder, it should be considered as a differential diagnosis in girls with abdominal pain regardless of their age. In the present case, we report a successful diagnosis and surgery of detorsion in a patient who underwent an urgent operation following an ovarian torsion detection.

## 2- CASE REPORT

The patient was a seven-year-old girl who had abdominal pain accompanied with

watery vomiting for some days. The patient did not have any familiar history. She was admitted to the pediatric ward and kept under observation by pediatricians who diagnosed her case as one of probable gastroenteritis. Serum therapy, acetaminophen, and ondansetron were used in the treatment process. The results of paraclinical examinations in the first visit included WBC: 8,800, HB: 11.8, ESR: 7, CRP: negative, U/A: normal, and electrolyte: normal.

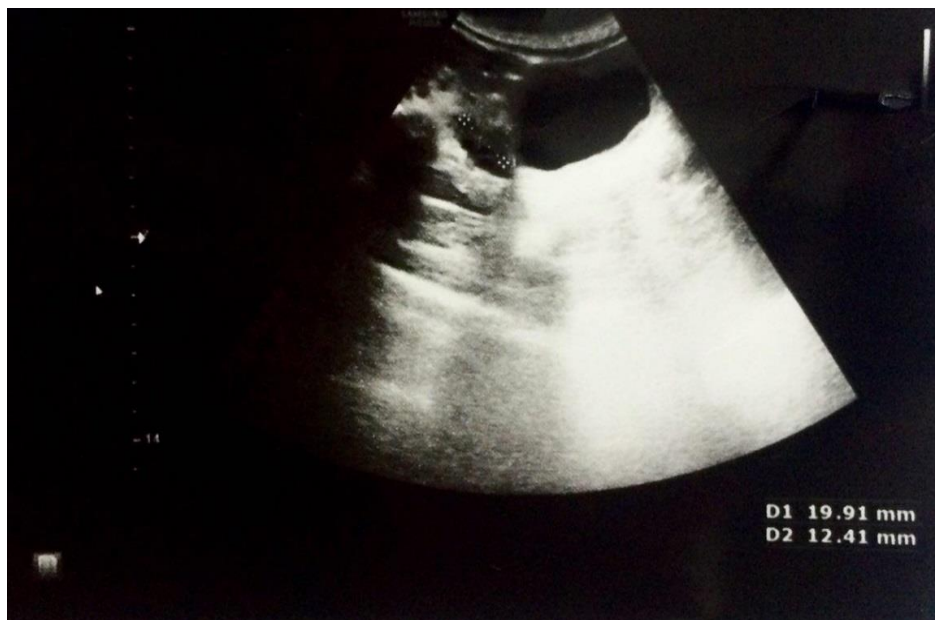
Finally, she was discharged with good general condition after two days of hospitalization. One day later, the patient was re-admitted with the same symptoms: The main complaints of the patient were abdominal pain and vomiting. Sonography revealed extension of the left ovary, and the patient was suspected of having ovarian torsion on her left side. Laparotomy was done, and torsion with the normal base of the ovary was seen. Because of the normal base of the ovary, the only possible surgical procedure was detorsion of ovary.

Cancer Antigen 125 (CA-125) was measured on the same day and there was no change from basement in the mentioned tumor-marker. The patient was discharged in a good general condition after two days of hospitalization. After six months, the patient was referred and checked by sonography. The patient's follow-up showed normal size of ovary by echo (RTO: 19×13 mm and LTO: 14×10 mm) (**Figures. 1 and 2**).

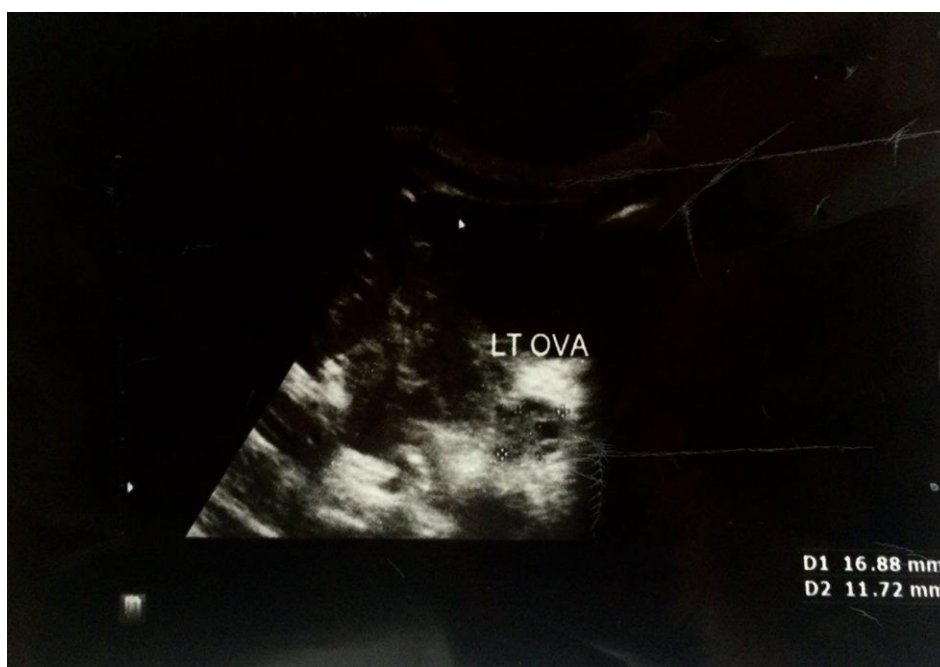
After 47 days, the patient was referred again with abdominal pain and repetitive vomiting. An ultrasound imaging of the abdomen showed extension of the left ovary again (**Figure.3**), and the patient was hospitalized to undergo laparoscopy. During laparoscopy, left torsion of ovary was identified. This torsion of ovary was detected along with three complete rotation. The only surgical procedure could be detorsion of the ovary because it was-

not necrotic. The uterus, appendix, and Surgery, the detorsed ovary was checked by sonography and no problem was seen. The patient was discharged in good

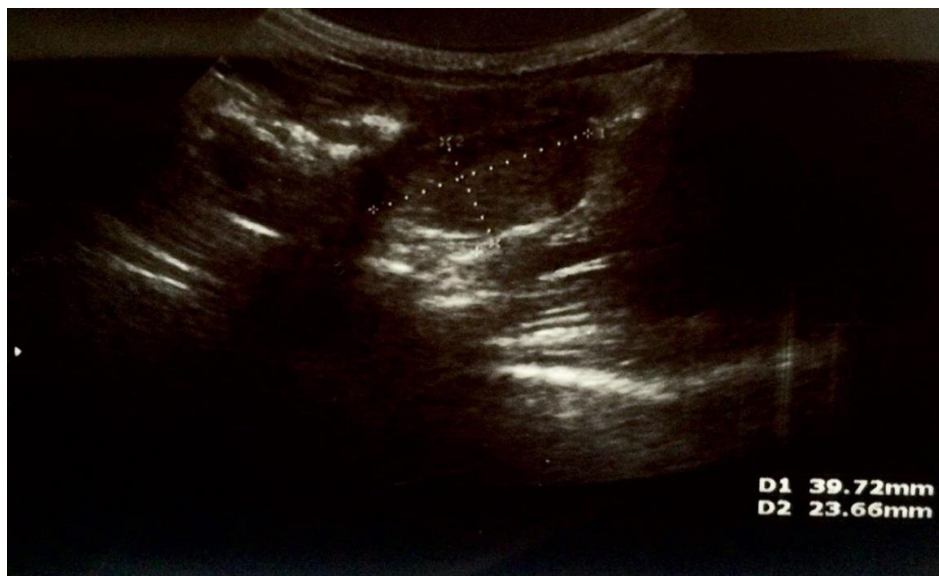right ovary were normal. A day after general condition after two days of hospitalization.



**Fig.1:** Sonography of the patient in follow-up with normal size of ovary by echo.



**Fig. 2:** Sonography of the patient in follow-up with normal size of ovary by echo.



**Fig. 3:** Sonography of the patient with extended left ovary before surgery.

### 3- DISCUSSION

Ovarian torsion (adnexal torsion) is the occlusion of the ovarian artery and/or vein caused by rotation of the ovary at its pedicle. It was described briefly first by Hasse in 1962 (9) and Mathiassen in 1965 (11) and reviewed by Alrabeeah *et al* in 1988 (10). Patients with ovarian torsion are often present with sudden onset of unilateral lower abdominal pain accompanied by vomiting and nausea (12).

Ovarian torsion accounts for about 3% of gynecological emergencies. Its incidence among women of all ages is 5.9 per 100,000 and among women at their reproductive age, it is a little higher (9.9 per 100,000 women) (13). Most of the diagnosis is done in adult ages (between 20 and 39 years of age). The risk is greater during pregnancy and in menopause. Risk factors include increased length of the ovarian ligaments, pathologically enlarged ovaries (more than 6 cm), ovarian masses or cysts, and enlarged corpus luteum in pregnancy. There is no brief study on the epidemiology of ovarian torsion in Iran. A study in Iran was conducted by Rostamzadeh *et al.* (14) on 323 women

with acute pelvic pain and highly suspected ovarian torsion signs and symptoms. The subjects attended Imam Reza Medical Center in Kermanshah between 2011 and 2012; they underwent a transabdominal sonography (2–5 MHz probes). The results of sonography showed 72.1% true positive, 27.9% false negative, and 0.4% false positive. The correlation between sonography and laparotomy with a kappa value was as high as 84.0%. The sensitivity of sonography was 72.1%; its specificity was 99.6%.

The development of an ovarian mass or tumor is related to the development of ovarian torsion. Ovarian torsion usually occurs with torsion of the fallopian tube. Ovarian torsions happen mostly unilaterally (80% of cases) and more often on the right (15). Regular growth of large corpus luteal cysts are a risk factor for this rotation (16). Although ovarian torsion is difficult to diagnose accurately; operations are often performed before diagnosis is certain; gynecologic ultrasonography, especially by using Doppler ultrasound in the diagnosis, could be helpful in this regard (17).

Specific flow features on Doppler sonography include: 1. Little or no intra-ovarian venous flow; 2. absent arterial flow; 3. absent or reversed diastolic flow; 4. enlarged hypoechogenic or hyperechogenic ovary; 5. peripherally displaced ovarian follicles; 6. free pelvic fluid in more than 80% of cases; 7. whirlpool sign of twisted vascular pedicle; 8. underlying ovarian lesions; and 9. maybe slight deviation of uterus toward the torsed ovary (18).

Treatment of ovarian torsion includes surgical laparoscopy to uncoil the torsed ovary, often with oophoropexy, to fixate the ovary so as not to twist again (19).

Ovarian torsion in pediatric ages is a difficult diagnosis because it has symptoms similar to gastroenteritis, pelvic pain, ovarian cysts, and acute appendicitis (4, 20). Ovarian torsion happens in children around their menarche period (21). Early detection of ovarian torsion is very crucial to save ovarian function because untreated torsion may result in necrosis of ovary and may affect all the aspects of a patient's life (8). As reported in many studies, ovarian torsion happens more commonly on the right side (22, 23).

But in our study, it happened on the left side. In the study of Mordehai et al. (24) which was done on 20 girls below 14 years of age, 30% had normal adnexa and 40% had diseased ovaries (mostly cysts), but our case has no background of any special disease related to gynecology. In ovarian torsion, the ovary twists on its pedicle, resulting in obstruction of venous and lymphatic drainages, leading to enlargement of ovary, which was detected in our case in **Figures 1, 2, and 3**. When ovarian torsion is identified before necrosis, the ovarian tissue may be saved by detorsion due to circulation of blood. Our case was somewhat different compared to other reported cases: The patient experienced two torsions and three complete rotations during nine months—

this issue fortunately was easily resolved by laparoscopy. The results of this study showed that torsion may occur twice in one ovary. The only way to prevent misdiagnosis is the use of radiographic methods to save the involved ovary. Although it is uncommon, ovarian torsion should be included in the differential diagnosis of abdominal pain in any girl regardless of her age and health condition. Sonography is very useful in making such a diagnosis. Early diagnosis is a critical factor in saving the ovary.

#### 4- CONCLUSION

Although it is uncommon, ovarian torsion should be included in the differential diagnosis of abdominal pain in any girl, regardless of her age and health condition. Sonography is very useful in making such a diagnosis. Early diagnosis is a critical factor to save ovary.

#### 5- ABBREVIATION

WBC: White blood cells,  
 HB: Hemoglobin,  
 ESR: Erythrocyte sedimentation rate,  
 CRP: C-reactive protein,  
 U/A: Urine analysis,  
 RTO: Right ovary,  
 LTO: Left ovary.

**6- CONFLICT OF INTEREST:** None.

#### 7- ACKNOWLEDGMENT

The authors are grateful to parents of patient who cooperated in the best manner.

#### 8- REFERENCES

1. Adelman S, Benson CD, Hertzler JH. Surgical lesions of the ovary in infancy and childhood. *Surg Gynecol Obstet.* 1975; 141(2):219-26.
2. Guthrie BD, Adler MD, Powell EC. Incidence and trends of pediatric

ovariantorsion hospitalizations in the United States, 2000-2006. *Pediatrics*. 2010;125(3):532-8.

3. Cohen Z, Shinhar D, Kopernik G, Mares AJ. The laparoscopic approach to uterine adnexal torsion in childhood. *J Pediatr Surg*. 1996;31(11):1557-9.

4. Houry D, Abbott JT. Ovarian torsion: a fifteen-year review. *Ann Emerg Med*. 2001;38(2):156-9.

5. Rody A, Jackisch C, Klockenbusch W, Heinig J, Coenen-Worch V, Schneider HP. The conservative management of adnexal torsion--a case-report and review of the literature. *Eur J Obstet Gynecol Reprod Biol*. 2002;101(1):83-6.

6. Sommerville M, Grimes DA, Koonings PP, Campbell K. Ovarian neoplasms and the risk of adnexal torsion. *Am J Obstet Gynecol*. 1991;164(2):577-8.

7. Dunnihoo DR, Wolff J. Bilateral torsion of the adnexa: a case report and a review of the world literature. *Obstet Gynecol*. 1984;64(3 Suppl):55S-9S.

8. Kokoska ER, Keller MS, Weber TR. Acute ovarian torsion in children. *Am J Surg*. 2000;180(6):462-5.

9. Hasse W. [Ovarian torsion cysts in newborn infants]. *Chirurg*. 1962;33:471-2.

10. Mathiassen P. [2 cases of ovarian torsion in children]. *Ugeskr Laeger*. 1965;127(16):539-40.

11. Alrabeeh A, Galliani CA, Giacomantonio M, Heifetz SA, Lau H. Neonatal ovarian torsion: report of three cases and review of the literature. *Pediatr Pathol*. 1988;8(2):143-9.

12. Ovarian Torsion. <http://emedicine.medscape.com/article/795994-overview>.

13. Yuk JS, Kim LY, Shin JY, Choi DY, Kim TY, Lee JH. A national population-based study of the incidence of adnexal torsion in the

Republic of Korea. *Int J Gynaecol Obstet*. 2015;129(2):169-70.

14. Rostamzadeh A, Mirfendereski S, Rezaie MJ, Rezaei S. Diagnostic efficacy of sonography for diagnosis of ovarian torsion. *Pak J Med Sci*. 2014;30(2):413-6.

15. Bsteh P. [Rare outcome of pedicle torsion in an ovarian tumor]. *Zentralbl Gynakol*. 1966;88(28):922-5.

16. Asfour V, Varma R, Menon P. Clinical risk factors for ovarian torsion. *J Obstet Gynaecol*. 2015;35(7):721-5.

17. Pena JE, Ufberg D, Cooney N, Denis AL. Usefulness of Doppler sonography in the diagnosis of ovarian torsion. *Fertil Steril*. 2000;73(5):1047-50.

18. Lee EJ, Kwon HC, Joo HJ, Suh JH, Fleischer AC. Diagnosis of ovarian torsion with color Doppler sonography: depiction of twisted vascular pedicle. *J Ultrasound Med*. 1998;17(2):83-9.

19. Lo LM, Chang SD, Horng SG, Yang TY, Lee CL, Liang CC. Laparoscopy versus laparotomy for surgical intervention of ovarian torsion. *J Obstet Gynaecol Res*. 2008;34(6):1020-25.

20. Tsai TC, Wong LY, Wu HP. Ovarian torsion caused by teratoma masquerading as perforated appendicitis in a 5-year-old girl. *Pediatr Neonatol*. 2011;52(1):51-4.

21. Cass DL. Ovarian torsion. *Semin Pediatr Surg*. 2005;14(2):86-92.

22. Lee CH, Raman S, Sivanesaratnam V. Torsion of ovarian tumors: a clinicopathological study. *Int J Gynaecol Obstet*. 1989;28(1):21-5.

23. Ward MJ, Frazier TG. Torsion of normal uterine adnexa in childhood: case report. *Pediatrics*. 1978;61(4):573-4.

24. Mordehai J, Mares AJ, Barki Y, Finaly R, Meizner I. Torsion of uterine adnexa in neonates and children: a report of 20 cases. *J Pediatr Surg*. 1991;26(10):1195-99.