

A Case of Empyema Necessitans: An Uncommon Presentation of Empyema

Sushanta Bhanja¹, Aritra Guha², Arnab Samanta², Hasen Ali Mia², Nitish Kumar³

¹ RMO cum Clinical Tutor, Department of Pediatrics, North Bengal Medical College and Hospital, Darjeeling, West Bengal, India.

² Post Graduate Trainee, Department of Pediatrics, North Bengal Medical College and Hospital, Darjeeling, West Bengal, India.

³ Assistant Professor, Department of Pediatrics, North Bengal Medical College and Hospital, Darjeeling, West Bengal, India.

Abstract

Background

Empyema is an accumulation of pus in the pleural space. Empyema necessitans occurs when pus extends through the parietal pleura into the surrounding tissues.

Case Report

We present here a 4 months old baby with severe respiratory distress and associated huge boggy swelling over the left side of his chest and back. Evaluation revealed pus accumulated in the pleural space which extended to the subcutaneous tissue; a case of empyema necessitans an uncommon occurrence with empyema. Early Intercostal drainage (ICD) insertion helped to save the baby.

Conclusion

Empyema can sometimes extend beyond the pleural space into the surrounding tissue leading to empyema necessitans. Early and prompt intervention is necessary which could significantly reduce morbidity and mortality.

Key Words: Empyema, Empyema necessitans, ICD.

*Please cite this article as: Bhanja S, Guha A, Samanta A, Mia AH, Kumar N. A Case of Empyema Necessitans: An Uncommon Presentation of Empyema. Int J Pediatr 2017; 5(7): 5351-55. DOI: 10.22038/ijp.2017.24070.2030

*Corresponding Author:

Sushanta Bhanja, Department of Pediatrics, North Bengal Medical College and Hospital, Darjeeling, West Bengal, India.

Email: Mojtaba53hashemi@yahoo.com

Received date: Apr.02, 2017; Accepted date: Apr. 22, 2017

1- INTRODUCTION

Empyema is accumulation of pus in the pleural space. Most commonly associated with Pneumonia caused by Streptococcus pneumoniae, although Staphylococcus aureus is the most common in the developing countries and Asia (1).

Empyema necessitans occurs when empyema extends through the parietal pleura into the surrounding tissues. Empyema necessitans has become a rare occurrence in present day due to routine drainage and antibiotic use (2). It is a rare and long term complication usually seen in poorly controlled or uncontrolled cases or often in patients with immunocompromised states as evidenced in most recent literature.

2- CASE REPORT

A male baby, resident of Dakshin Dinajpur, West Bengal- India, having uneventful perinatal period presented to us at 4 months of age with history of low grade fever for 7 days, respiratory distress for 3 days, and a boggy swelling over sides and back of left chest for 2 days.

On examination the baby had severe distress with respiratory rate 88/min, air entry on the left side grossly diminished, suprasternal suction and chest retractions. There was a pulsatile boggy swelling with engorged veins over the chest (**Figure.1**).

Oxygen Saturation (SpO₂) 84% with oxygen Chest X-ray showed a homogeneous opacity of the whole of the left lung field with no remarkable costophrenic or cardiophrenic angle, with the heart shifted to the right and gross midline shifting of the trachea to the right.

The homogenous opacity extended beyond the ribs and involved the subcutaneous space of the left hemithorax. An immediate intercostal drain was inserted within hours of admission following which the baby was stabilized in pediatric intensive care unit (PICU).

A repeat chest X-ray showed resolution. He was managed with IV antibiotics. Routine blood investigations were within normal range except leukocytosis. Pleural fluid study showed 20,000 cells/cumm with degenerated polymorphs, lymphocytes and histiocyte, protein 5.12 gm/dl, sugar 43 mg/dl, acid-fast bacteria (AFB) negative and no malignant cells were seen. Both blood and pus culture showed no growth.

High-resolution computed tomography (HRCT) chest showed collapse consolidation of left lower lobe and consolidation of right upper lobe, with empyema on the left side associated with pleural thickening.

Chest drain was removed eventually, and the baby was continued on antibiotics for 21 days. Baby was eventually discharged in a stable and active condition (**Figure. 2**) and referred to a cardiothoracic surgeon for further follow-up and management.

Prompt action and immediate intervention helped preventing what could have been a fatal outcome for this patient. Chest radiograph series (**Figure.3**) shows the evolution pattern of the empyema.

- On the day of presentation,
- 12 hours after chest drain insertion,
- After chest drain removal,
- 4 - After 21 day antibiotic.

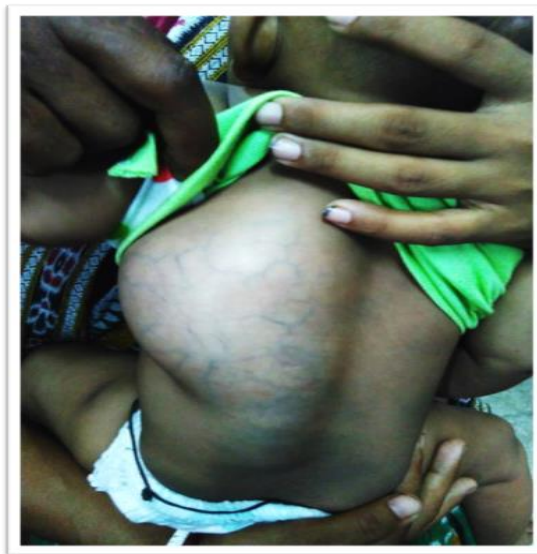

Fig.1: Child presenting with boggy swelling over chest with venous prominence.

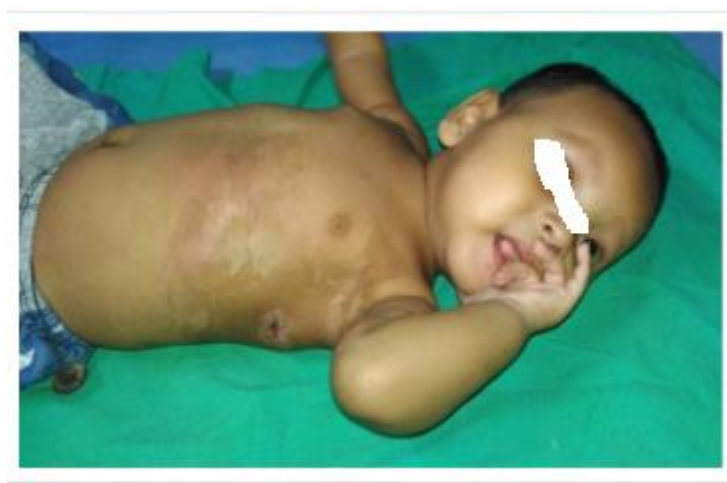

Fig.2: Baby at the time of discharge.

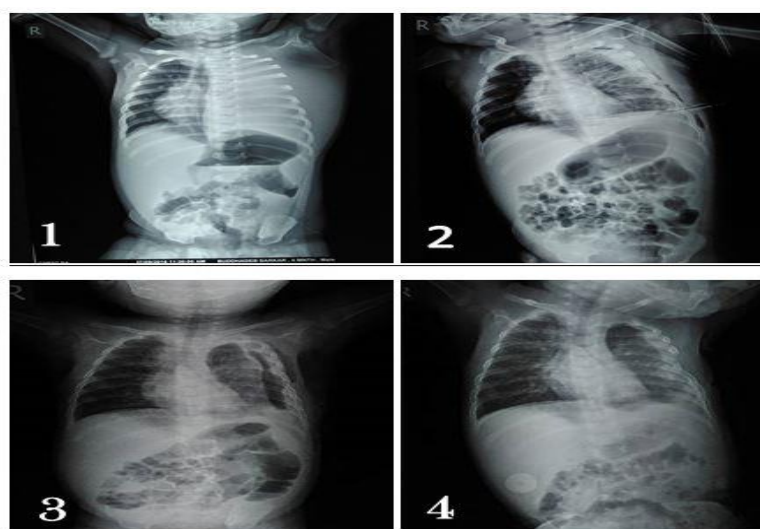


Fig.3: Chest radiograph series showing the evolution pattern of the empyema.

3- DISCUSSION

Empyema necessitans is one of the rare complications of empyema. It is a result of long standing underlying lung infection. Staphylococcal infections are now shown to outnumber streptococcal infections as the leading cause in countries where widespread pneumococcal vaccination occurs (3). Empyema occurs in 5-10% of children with bacterial pneumonia and in up to 86% children with necrotizing pneumonia (1). Bronchopleural fistulas and pyopneumothorax are common complications seen associated with empyema. Also associated are purulent pericarditis, pulmonary abscesses, peritonitis from extension through diaphragm and osteomyelitis of rib although rare. Empyema necessitans is one rare presentation. Especially in our set up this was 1st incidence of such a case, thereby suggesting the rarity of such a presentation. Several studies and case reports over the year have pointed to the fact that empyema necessitans is one of the rarest presentations of empyema (4).

Akgul et al. (5) found only nine cases of empyema necessitans in his study period of over a 4 years in Turkey. Hoffman (6), in his study reported a prevalence of 3.2% in United Kingdom. Not much data is available regarding the prevalence of empyema in our region, thereby suggesting the rarity of the presentation.

Empyema necessitans is a result of neglected or inadequately treated empyema. It presents in patients with underlying pulmonary disease and a swelling over the hemithorax. The goals of treatment of any empyema would include sterilizing the pleural cavity, controlling the infection, draining the fluid, thereby allowing the lung to expand and restore normal function (7). Failure to do so in appropriate time results in a presentation of Empyema necessitans where the uncontrolled effusion extends into the chest wall following the path of least

resistance. Parsons et al., recommend that most cases can be managed successfully with an intercostal chest tube insertion a drainage, along with appropriate antibiotic therapy. Based on available evidence, thoracotomy with decortication, in children, may provide the most effective treatment when compared with Video assisted thoracoscopic surgery (VATS) and chest tube drainage with or without intrapleural fibrinolytic therapy (8).

Delaying drainage increases the risk of occurrence of complications like Empyema necessitans and thereby increases morbidity and potentially mortality. The most challenging part of managing our case was to identify the disease as a case of empyema necessitans, early intervention and removing the pus by means of an ICD, thereby relieving the respiratory distress of the patient. Once the distress settled intravenous antibiotic regimen worked well in improving the baby.

4- CONCLUSION

Empyema if not diagnosed or treated at the right time, can present with an uncommon presentation like Empyema necessitans. Prompt management and intervention with proper antibiotic cover can prevent such occurrences and thereby reduce the morbidity and mortality associated with the disease.

5- CONFLICT OF INTEREST: None.

6- ACKNOWLEDGMENT

Authors thank the authorities of North Bengal Medical College and Hospital, Darjeeling, India for allowing us to report the case.

7- REFERENCES

1. Winnie GB, Lossef SV. Pleurisy, Pleural Effusions, and Empyema. In: Kliegman RM et al. editor. Nelson Text Book of Pediatrics, Volume 2, 20th ed. Elsevier; 2016. pp. 2134-5.

2. Kellie SP, Shaib F, Forster D, Mehta JP. Empyema Necessitatis. *Chest* 2010; 138(4):39A–1–39A–2. Available at: <http://dx.doi.org/10.1378/chest.9958>.
3. Schultz KD, Fan LL, Pinsky J, Ochoa L, Smith EO, Kaplan SL, et al. The changing face of pleural effusions in children: Epidemiology and Management. *Pediatrics* 2004; 113:1735-40.
4. Yauba MS, Ahmed H, Imoudu IA, Yusuf MO, Makarfi HU, Presentation C. Case Report Empyema Necessitans Complicating Pleural Effusion Associated with Proteus Species Infection : A Diagnostic Dilemma. *Case Rep Pediatr.* 2015; 2015:108174.
5. Akgül AG, Örki A, Örki T, Yüksel M, Arman B. Approach to empyema necessitates. *World Journal of Surgery* 2011; 35(5): 981–84.
6. E. Hoffman. Empyema in childhood. *Thorax* 1961; 16: 128–37.
7. Tamura L, Hasoon M, Bandlamuri M, Carlson RW. Empyema Necessitans (EN): Critical Care Importance of Appropriate Pleural Drainage. 2015; 17(1):10–3.
8. Parsons SJ, Fenton E, Williams M. Paediatric Empyema : A Case Report and Literature Review. *Critical Care and Resuscitation* 2005; 7: 102-6.