

Novel Presentation of Complete Coronal Urethral Duplication: a Case Report

Amrollah Salimi¹, Shervin Rashidinia², Seyed Shahin Eftekhari², *Sara Shahmoradi²

¹Department of Pediatric Surgery of Hazrat Masoume Hospital, Qom University of Medical Sciences, Qom, Iran.

²School of Medicine, Qom University of Medical Sciences, Qom, Iran.

Abstract

Urethral duplication is a rare condition occurs as a congenital malformation either independently or in the setting of other congenital malformations such as caudal duplication syndrome. Its prevalence becomes even rarer if it manifests as two side-by-side tracts in coronal plan.

Nonetheless, we introduce a unique presentation of complete coronal urethral duplication accompanied by astounding manifestations of gastrointestinal malformations different from what is expected for a normal hind gut or caudal duplication syndrome. A 6-year-old boy with complete coronal duplication of urethra along with duplication of appendix, sigmoid and rectum as well as developmental delay, attracted our attention to report.

Key words: Appendix, Child, Fistula, Urethra.

*Please cite this article as: Salimi A, Eftekhari SS, Rashidinia Sh, Shahmoradi S. Novel Presentation of Complete Coronal Urethral Duplication: a Case Report. Int J Pediatr 2017; 5(4): 4707-12. DOI: **10.22038/ijp.2017.22681.1895**

Corresponding Author:

Dr. Sara Shahmoradi, MD, School of Medicine, Qom University of Medical Sciences, Qom, Iran.

Email: Sr.shahmoradi@gmail.com

Received date Jan.23, 2017; Accepted date: Feb.22, 2017

1- INTRODUCTION

Caudal duplication syndrome is a rare condition which includes partial or complete duplication of the organs originated from hindgut, embryonic cloaca and neural tube (1). It encompasses different clinical manifestations in genitourinary, gastrointestinal, neurological or skeletal systems. Its prevalence at birth is less than 1 per 100,000 (2). We propose to report a case of 6 years boy with developmental delay and complete coronal duplication of urethra, appendix, sigmoid, rectum and rectourethral fistula (RUF) as a very rare presentation.

2- CASE REPORT

A 6-year-old boy presented to our hospital (Hazrat-e- Masumeh Pediatrics Hospital, Qom- Iran) with a complaint of fecaluria and abdominal distention. His symptoms got started approximately since 1 year old, which were gradually intensified. The parents, nonetheless, noted no particular problem from birth till then

except for a penis with two orifices (**Figure.1**). Thus, the child has not received any medical review up to 5 years old, once his complaints became more frequent and severe. Subsequently, they were evaluating by a Voiding cystourethrography (VCUG). Interestingly, the results demonstrated two completely open urethras which enter separately to a septated urinary bladder as well as grade II vesicoureteral reflux in right side, with no evidence in the left. However, there found no obvious leakage of contrast into the rectum suggestive of rectourethral fistula (**Figure.2**).

Through cystoscopy, then, it observed that both urethrae are opened to the bladder and the right urethra is connected to the rectum through a rectourethral fistula below the bladder neck. There was nothing noticeable suggestive of divided bladder, but the higher placement of the ureters compared with their normal position as well as a septum dividing the bladder into two interrelated parts.

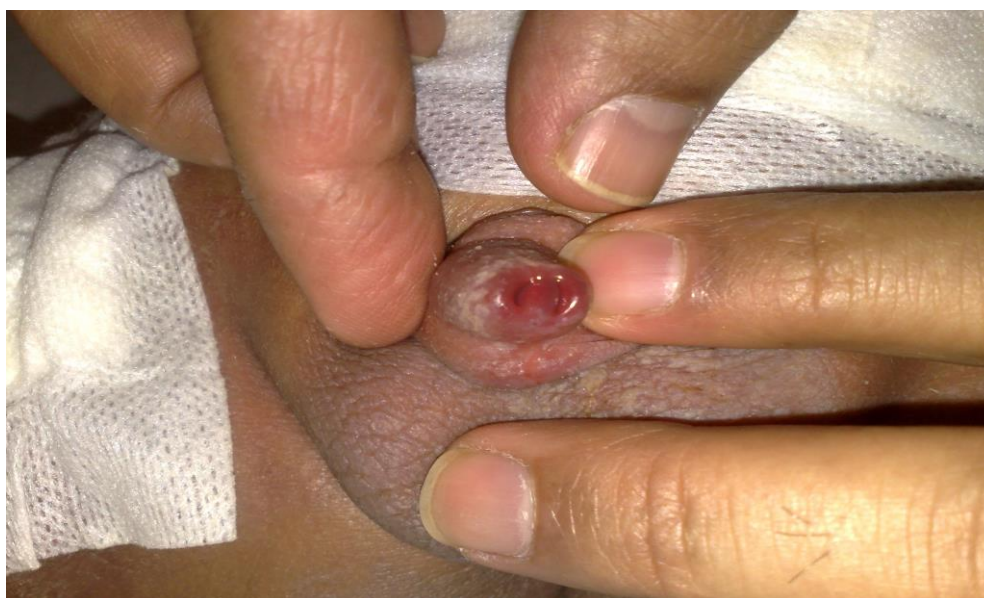

Fig.1: Coronal duplicated urethra open to a single penile glans.

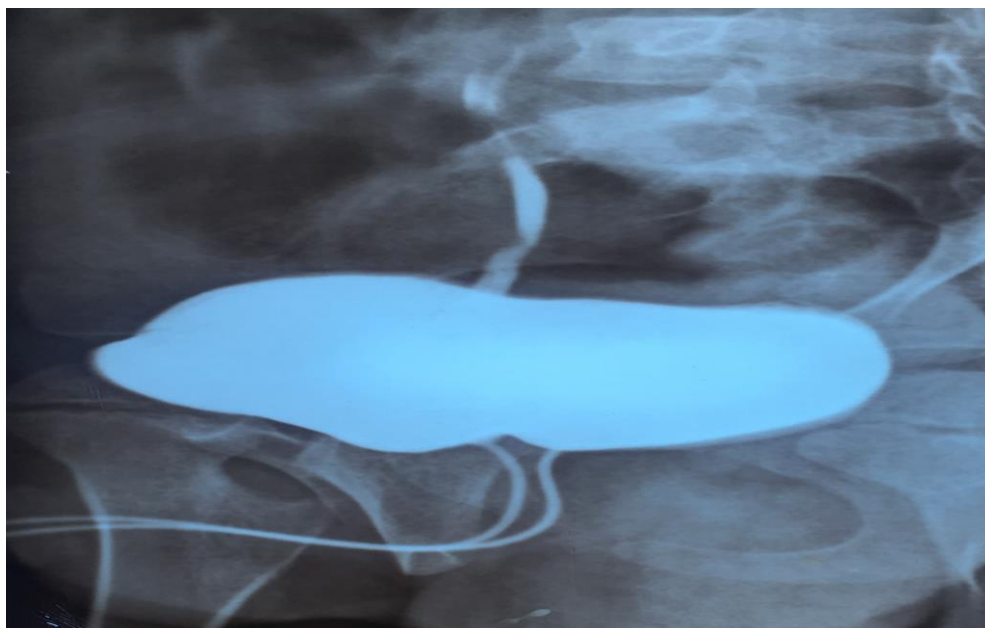


Fig.2: Voiding cystourethrogram indicating two completely open urethras which enter separately to a single urinary bladder. Graphy is also show a grade II vesicoureteral reflux in right side.

Finally, the patient has referred to our hospital for further measures and follow-up. It is worth mentioning that he is the first-born son from consanguineous marriage with no family history of congenital disorder or malformation. After the first 6 months of his life, he suffered from developmental delay and hypotonia, whereas he never had such a complaint before that. He is also yet unable to walk and talk acceptably.

He had a cataract surgery within his 15th months and underwent herniorrhaphy for his right inguinal hernia when he had 3 months old. At presentation, a penis with 2 orifices, which had both lain side-by-side and opened separately to the urinary tract, drew attention through the primary examination of the genitalia. The patient appeared abnormal developmentally, and beside hypotension along with two episodes of hypoglycemia (dropped glucose level to 30 mg/dl), and hyponatremia (serum Na level of below 120 mEq/L) (120 mmol/L), prompted our suspect to a probable metabolic disorder. So, the samples have sent for metabolic evaluations and yielded no definite

diagnosis, except for Glucose-6-Phosphate Dehydrogenase Deficiency (G6PD) and sickle cell anemia. For this patient anorectal malformation with duplication of urethra was a provisional diagnosis. Patient underwent exploratory laparotomy to find any concomitant defect as well as to close the rectourethral fistula and removing urinary bladder septum. During the operation, sigmoid and rectum were seen to be totally dilated, duplicated and stick together with muscular wall up to descending colon (**Figure.3**).

Right sigmoid and rectum were found being full of stool. Right rectum was connected to the right urethra below the bladder neck through a fistula (**Figure.4**).

Colon and cecum were intact and have not had duplicated, but two separate appendixes have found to be originated from similar cecum. The bladder separated into two interrelated parts by a septum, that each of which led to a urethra drawn to the meatus tip. Ureter insertions were also seen to be placed higher compared with normal position have to be (**Figure.5**).

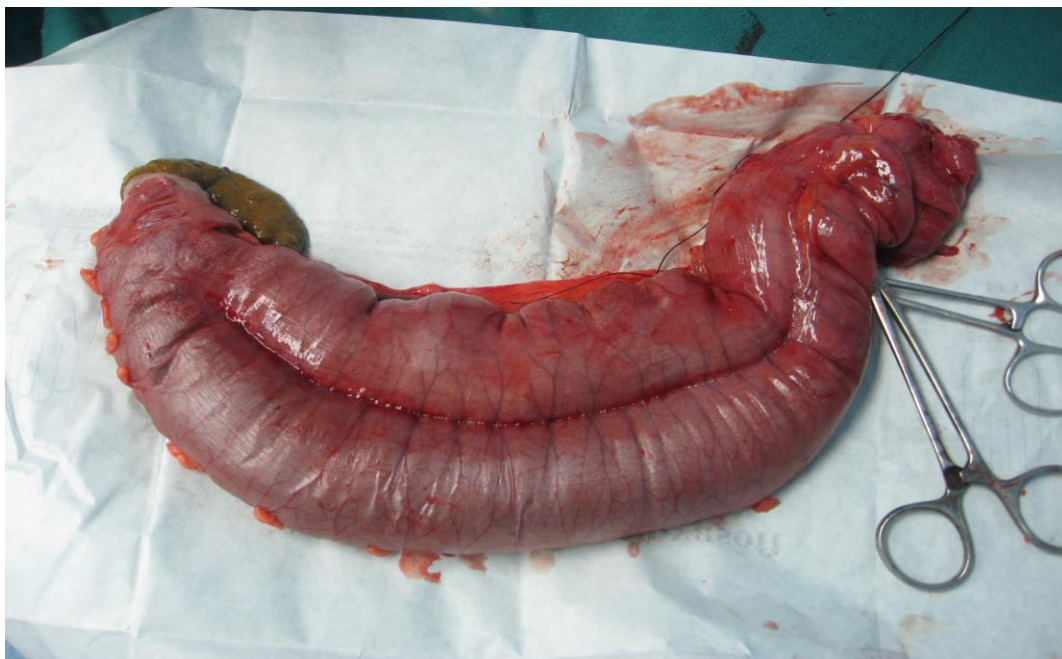

Fig.3: Operative image showing the resected duplicated sigmoid and rectum, which stick together with a muscular layer in between.

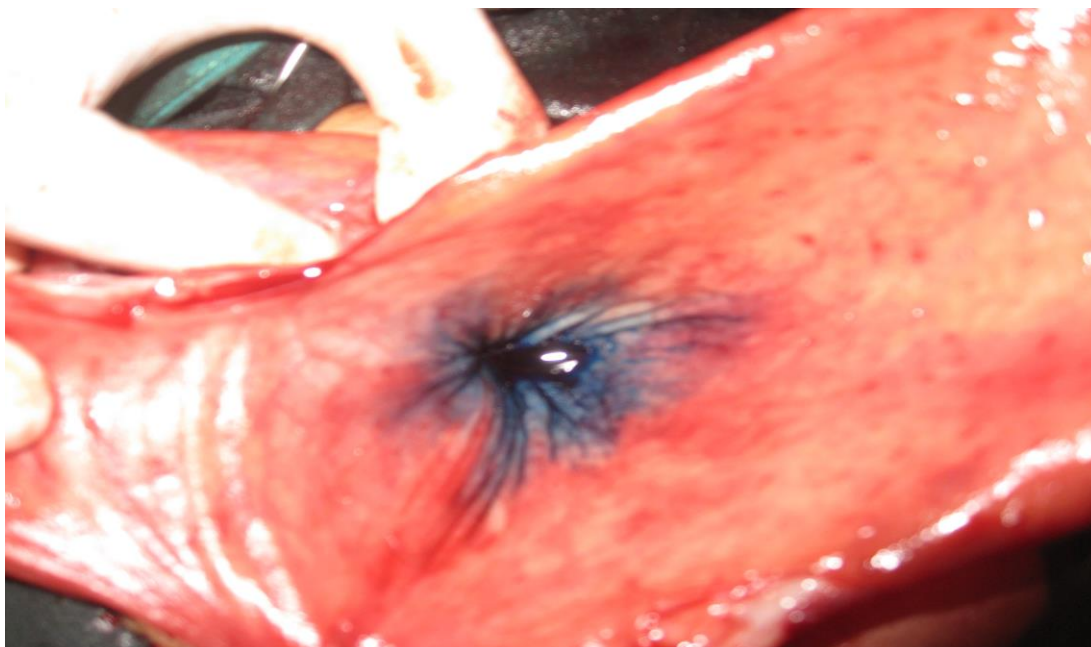


Fig.4: Intra-operative dye injection to confirm the opening of rectourethral fistula.

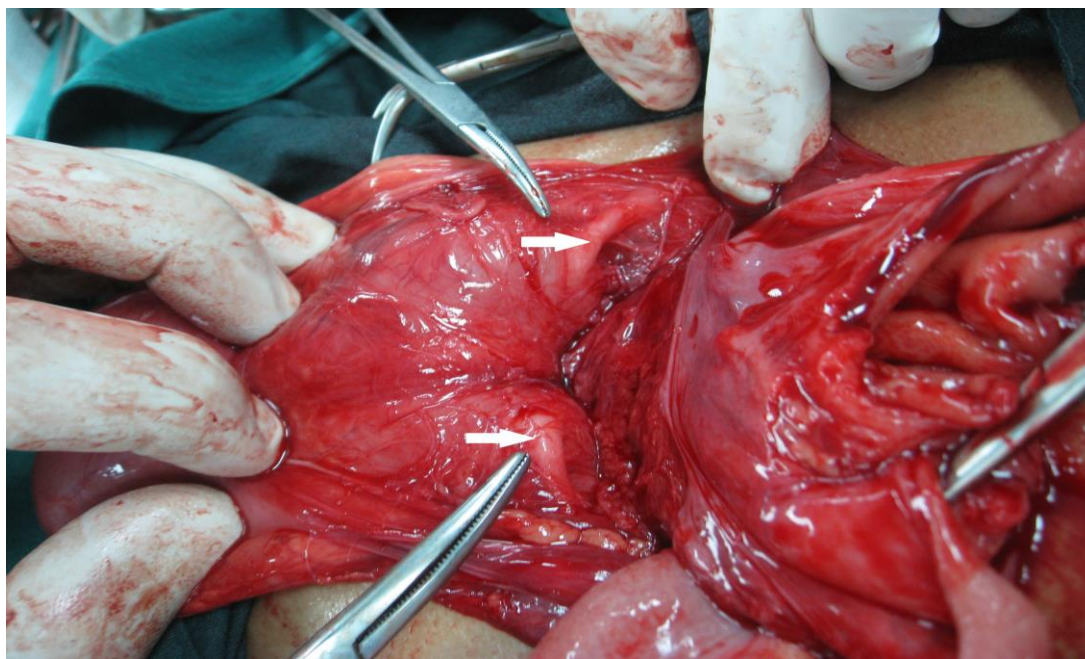


Fig.5: Operative image showing the septate urinary bladder with higher set ureters (arrows). No evidence of duplicated urinary bladder is found.

3- DISCUSSION

Complete urethral duplication is an uncommon anomaly and generally occurs in males. Furthermore urethral duplication in coronal plan (side by side) is more rare (3), and the patients usually have two external genitalia (4, 5), or two hemiphallus (1), that known as caudal duplication syndrome. Accordingly, Juao luiz et al. (6), reported only one patient with type c coronal urethral duplication in a single penile tip based on Effman classification in 2000. Patients are often asymptomatic in sagittal urethral duplication or present with Urinary Tract Infections (UTI) two streams urination or other urinary complications, notwithstanding the coronal type of urethral duplication is associated with other extra genitourinary complications and anomalies (3).

We present here a case of coronal urethral duplication that is associated with duplication of appendix, sigmoid and rectum but, interestingly, a single colon and an en bloc bladder which had divided

in two parts with a septum. We suggest this is more likely due to hindgut duplication or an unusual presentation of caudal duplication syndrome. However, Dominiquez et al. (7), proposed the term caudal duplication syndrome to describe the association between gastrointestinal, genitourinary, and distal neural tube malformations. Although, Incesu et al. (8), found that some patients can neurologically be normal. Sweta et al. presented a 3-day- old male neonate with duplication of bladder and urethra, 2 hemiphallus, colon, rectum with two stenotic anal orifice that show a complete caudal duplication (1), but in our case we had an escaped area in lower gastrointestinal (GI) duplication and complete coronal duplication with two side by side orifice in tip of glans. In 2016, Tianshen Hu et al. (9), presented a 28-year-old female, Gravid 2 with caudal malformation. Imaging and surgical finding reveal duplication of bladder, entire colon, uterus didelphys with separated cervixes and vaginal canal, external genitalia and spinal dysraphism. There is also a literature by

Mark et al. (1953), in which 20 patients (12 females and 8 males), were reviewed for hind gut duplication (10). Entire colon has been reported to be duplicated in 15 cases, and 5 cases have been reported to have terminal ileum duplicated as well as appendix in half of 20 cases all of those were duplicated from cecum or ileum to rectum or anus. Noteworthy is that neither of them had escaped area pattern of involvement nor two side by side complete urethral duplications, in contrast to ours.

Therefore, this is the first report of caudal twinning presented with escaped area of GI duplication; single colon and two appendixes, duplicated sigmoid and rectums along with a single anus orifice. There is also one penile shaft with two side-by-side orifices (complete coronal urethral duplication), with rectourethral fistula from right rectum to right urethra, without any complication of spinal cord defect. Nevertheless, the association of developmental delay, in our patient, with this condition still remains ambiguous.

4- CONCLUSION

Finally, we supposed to introduce a strange presentation of caudal duplication syndrome with eminent symptoms of urinary manifestations. This particular patient reminds us the importance of having mindfulness in putting the signs and symptoms together to achieve an early diagnosis of the disease.

5- CONFLICT OF INTEREST: None.

6- REFERENCES

1. Swaika S, Basu S, Bhadra RC, Sarkar R, Maitra SK. Caudal Duplication Syndrome—Report of a Case and Review of

Literature. *Indian Journal of Surgery* 2013 Jun 1;75(1):484-7.

2. Sur A, Sardar SK, Paria A. Caudal duplication syndrome. *Journal of clinical neonatology* 2013; 2(2):101.

3. Wang YG, Davies N, Desai D, Yap HW. Complete urethral duplication in a 66-year-old male. *Journal of Clinical Urology* 2016;2051415816646699.

4. Bandré E, Wandaogo A, Kabre SM, Ouedraogo I, Napon M. Challenges in the management of a rare case of caudal duplication syndrome in a poor resource setting. *Journal of Pediatric Surgery Case Reports* 2015; 3(11):508-11.

5. Karaca I, Turk E, Ucan AB, Yayla D, Itirli G, Ercal D. Surgical management of complete penile duplication accompanied by multiple anomalies. *Canadian Urological Association Journal* 2014; 8(9-10):E741.

6. Salle JL, Sibai H, Rosenstein D, Brzezinski AE, Corcos J. Urethral duplication in the male: review of 16 cases. *The Journal of urology* 2000; 163(6):1936-40.

7. Dominguez R, Rott J, Castillo M, Pittaluga RR, Corriere JN. Caudal duplication syndrome. *American Journal of Diseases of Children* 1993; 147(10):1048-52.

8. Incesu L, Karaismailoglu TN, Selcuk MB. Neurologically normal complete asymmetric lumbar spine duplication. *American journal of neuroradiology* 2004 ; 25(5):895-6.

9. Hu T, Browning T, Bishop K. Caudal duplication syndrome: imaging evaluation of a rare entity in an adult patient. *Radiology case reports* 2016;11(1):11-5.

10. Ravitch MM, Scott WW. Duplication of the entire colon, bladder, and urethra. *Surgery* 1953;34(5):843-58.