

A New Nonsense Mutation in CDKL5 Gene in a Male Patient with Early Onset Refractory Epilepsy: a Case Report

Soudeh Ghafouri-Fard¹, Shadab Salehpour², *Vahidreza Yassaee³,
*Mohammad Miryounesi³

¹ Department of Medical Genetics, Faculty of Medicine, Shahid Beheshti University of Medical Sciences, Tehran, Iran.

² Department of Pediatrics, Mofid Children Hospital, Faculty of Medicine, Shahid Beheshti University of Medical Sciences, Tehran, Iran.

³ Genomic Research Center, Shahid Beheshti University of Medical Sciences, Tehran, Iran.

Abstract

Background

The X-linked cyclin-dependent kinase like 5 (CDKL5/STK9) gene has been shown to be responsible for a severe encephalopathy condition characterized by early onset of epilepsy and severe developmental delay. *CDKL5* mutations have been shown to be more frequent among female patients.

Results

Here we report a 6-month male patient, second child of a healthy non-consanguineous Iranian population. He has been affected by early onset epileptic refractory seizures and developmental delay. Whole-exome sequencing (WES) has revealed a base substitution c.173T>A in *CDKL5* gene, resulting in the formation of stop codon p.L58X. This mutation resides in the catalytic domain of the corresponding protein and is expected to result in premature RNA break down with no CDKL5 resulting protein.

Conclusion

The present report highlights the importance of *CDKL5* mutation analysis in male patients affected with early onset refractory epilepsy.

Key Words: CDKL5, Epilepsy, Mutation.

*Please cite this article as: Ghafouri-Fard S, Salehpour Sh, Yassaee V, Miryounesi M. A New Nonsense Mutation in CDKL5 Gene in a Male Patient with Early Onset Refractory Epilepsy: a Case Report. Int J Pediatr 2016; 4(2): 1315-18.

*Corresponding Author:

Vahidreza Yassaee, Mohammad Miryounesi, Genomic Research Center, Shahid Beheshti University of Medical Sciences, Tehran, Iran.

Email: v.yassaee-grc@sbmu.ac.ir and miryounesi@sbmu.ac.ir

Received date Dec27, 2015 ; Accepted date: Jan 12, 2015

1-INTRODUCTION

The X-linked cyclin-dependent kinase like 5 (*CDKL5*, OMIM 300203) gene (previously called STK9, serine/threonine kinase 9) has been shown to be responsible for a severe encephalopathy condition (ISSX, OMIM 308350) (1). The main features are an early onset of epilepsy usually starting before 2 months of age and severe developmental delay in spite of any period of regression (2). The phenotype resembles an atypical Rett syndrome (3) combining autistic characteristics, lack of speech, motor deficiency, severe mental retardation, early epilepsy and infantile spasms (2). Early occurrence of the epileptic seizures in the first six months differentiates the patients with *CDKL5* mutations from patients with typical Rett syndrome due to a *MeCP2* mutation. Mutations in *CDKL5* are responsible for about 10% of the female patients affected with early onset of a severe refractory seizure disorder or infantile spasms with severe hypotonia and girls with Rett-like phenotype and early onset seizures. Such mutations are seen rarely in male patients (4). Although no distinctive electroencephalogram (EEG) pattern has been correlated to *CDKL5* mutations, epileptic spasms are a common seizure type illustrated in patients with *CDKL5* mutations (5).

2-CASE PRESENTATION

Here we report a 6-month male patient, second child of a healthy non-consanguineous in the Iranian population. The pregnancy was uneventful and he was born at term. Prenatal history revealed no complications and no documented exposure to medications or other teratogens. His birth weight, height and head circumference were on 50th percentile. His Apgar scores were 9 and 10 at one and five minutes respectively. He

was affected with tonic flexion seizures since 20th days after birth. Although treated with phenobarbital, clobazam, vigabatrin and topiramate, he suffered from refractory seizures. His psychomotor development was severely delayed. He did not develop any communication skills and cannot support his head and neck. He had no dysmorphic facial appearance. EEG showed multifocal interictal spikes particularly in posterior quadrants during sleep. His video-EEG monitoring showed a severe symptomatic epilepsy syndrome with tonic-clonic seizures. Brain magnetic resonance imaging (MRI) revealed no structural malformation. His audiography test, electroretinography (ERG) and visual evoked response (VER) were normal. No evidence of a storage disorder or a detectable metabolic or neurodegenerative disorder was demonstrated in laboratory investigations. In order to find the underlying genetic cause, peripheral blood samples were obtained from patient and his parents in ethylenediamine tetraacetic acid (EDTA) tubes after getting approval of the study protocol by the ethics committee of the institution and informed consent from parents. DNA was extracted from peripheral blood of the patient using salting out method. Whole exome sequencing was carried out using illumina's Genome Analyzer for the patient with focus on 2752 Online Mendelian Inheritance in Man (OMIM) disease genes (BGI-Clinical Laboratories, Shenzhen, China). The sequence analysis showed a base substitution c.173T>A in *CDKL5* gene, resulting in the formation of stop codon p.L58X. The results were verified by Sanger sequencing using the ABI Prism3130 Genetic Analyzer (Applied Biosystems, Foster City, CA, USA). Targeted sequencing on the mother showed that she did not carry the detected variant (Figure.1).

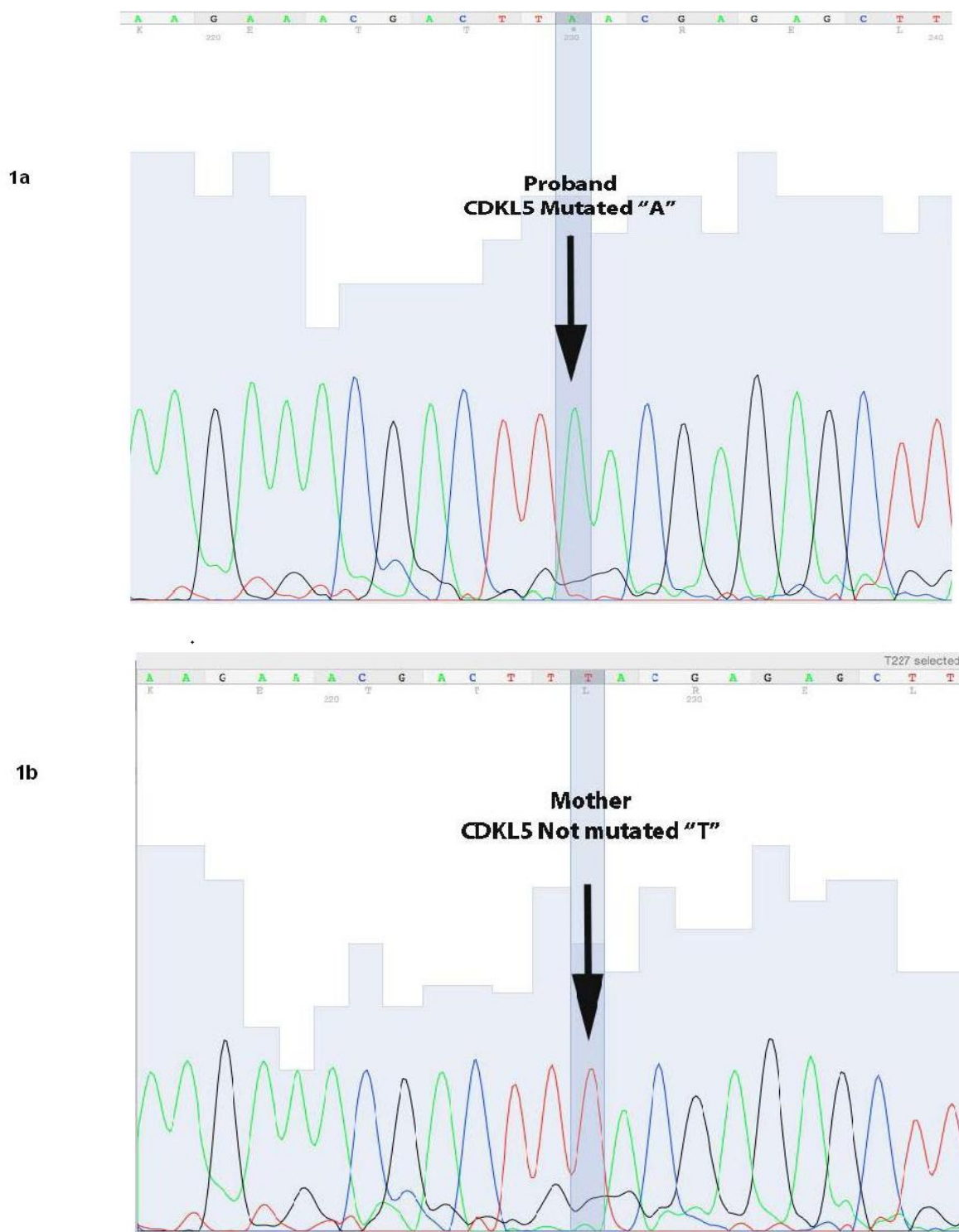


Fig.1: Nucleotide change in proband (1a) and his mother (1b).

3-DISCUSSION

Mutations in the *CDKL5* gene demonstrated in patients with early onset epileptic seizures. These mutations have

been shown to affect mostly females (6). Although recurrent mutations have been reported, most mutations have been detected in single patients (5). The detected mutation in this study (p.L58X)

has not been reported previously. However, an adjacent codon has been shown to be affected by a nonsense mutation, resulting in p.R59X. This mutation has been reported in 2 independent female patients with early onset epileptic encephalopathy, but distinct dysmorphic features (5, 7). The reported mutation in the present study resides in the catalytic domain of CDKL5. Mutations in such location have been demonstrated to associate with earlier onset refractory infantile spasms and more rigorous late onset multifocal and myoclonic epilepsy than mutations affecting C terminal location (2). The early stop codon produced by the mutation p.R59X would result in transcription termination and subsequent RNA break down with no CDKL5 protein (7). Such events are expected occur following p.L58X mutation as well. Previous studies have revealed that *CDKL5* mutations are considerable etiological factors for neurodevelopmental disorders especially in female patients with early onset epileptic encephalopathy and have suggested mutation screening of this gene for such patients (5).

4-CONCLUSION

Mutations in the *CDKL5* gene have been supposed to be less frequent in males and have been shown to be associated with genomic deletions in few cases (5, 8). However, in the present study, we have demonstrated a *de novo* nonsense mutation in a male patient. The present report highlights the importance of this analysis in male patients affected with early onset refractory epilepsy as well.

5-CONFLICT OF INTERESTS: None.

6-ACKNOWLEDGMENT

We thank patient's family for their cooperation in providing clinical data of patient.

7-REFERENCES

1. Kalscheuer VM, Tao J, Donnelly A, Hollway G, Schwinger E, Kubart S, et al. Disruption of the serine/threonine kinase 9 gene causes severe X-linked infantile spasms and mental retardation. *American journal of human genetics* 2003;72(6):1401-11.
2. Bahi-Buisson N, Kaminska A, Boddaert N, Rio M, Afenjar A, Gérard M, et al. The three stages of epilepsy in patients with CDKL5 mutations. *Epilepsia* 2008;49(6):1027-37.
3. Gharesouran J, Khalili AF, Azari NS, Vahedi L. First case report of Rett syndrome in the Azeri Turkish population and brief review of the literature. *Epilepsy & behavior case reports* 2015;3:15-29.
4. Bahi-Buisson N, Nectoux J, Rosas-Vargas H, Milh M, Boddaert N, Girard B, et al. Key clinical features to identify girls with CDKL5 mutations. *Brain : a journal of neurology* 2008;131(Pt 10):2647-61.
5. Castren M, Gaily E, Tengstrom C, Lahdetie J, Archer H, Ala-Mello S. Epilepsy caused by CDKL5 mutations. *European journal of paediatric neurology : EJPN : official journal of the European Paediatric Neurology Society* 2011;15(1):65-9.
6. Nemos C, Lambert L, Giuliano F, Doray B, Roubertie A, Goldenberg A, et al. Mutational spectrum of CDKL5 in early-onset encephalopathies: a study of a large collection of French patients and review of the literature. *Clinical genetics* 2009;76(4):357-71.
7. Ricciardi S, Kilstrup-Nielsen C, Bienvenu T, Jacqueline A, Landsberger N, Broccoli V. CDKL5 influences RNA splicing activity by its association to the nuclear speckle molecular machinery. *Human molecular genetics* 2009;18(23):4590-4602.
8. Van Esch H, Jansen A, Bauters M, Froyen G, Fryns JP. Encephalopathy and bilateral cataract in a boy with an interstitial deletion of Xp22 comprising the CDKL5 and NHS genes. *American journal of medical genetics Part A* 2007;143(4):364-69.