

Preserving Pediatric Maxillofacial Growth and Function after Trauma: A Narrative Review of Innovative Surgical Strategies and Long-Term Outcomes

Faezeh Rasouli¹, * Mojtaba Zaeimdar¹

¹ Department of Oral and Maxillofacial Surgery, School of Dentistry, Dental Research Center, Avicenna Institute of Clinical Sciences, Avicenna Health Research Institute, Hamadan University of Medical Sciences, Hamadan, Iran.

Abstract

Pediatric maxillofacial trauma is a unique clinical condition characterized by distinct anatomical, developmental, and biomechanical features. The growing facial skeleton, mixed dentition, and active growth centers contribute to age-dependent fracture patterns and influence treatment strategies. Epidemiological data show a higher incidence in male patients, with adolescents being the most affected age group. Common causes include falls, sports-related injuries, and motor vehicle accidents, with fracture distribution varying by age and mechanism of injury. Treatment approaches must balance immediate fracture stabilization with preserving facial growth, occlusal development, and long-term functional and aesthetic outcomes. Non-displaced or minimally displaced fractures are usually managed conservatively, while displaced or functionally compromising injuries often require surgical intervention, such as open reduction and internal fixation. Growth-preserving techniques, minimally invasive approaches, and the use of bioabsorbable fixation materials have shown positive outcomes with low complication rates. However, the literature is limited by retrospective designs, single-center experiences, heterogeneous patient populations, and inconsistent long-term follow-up data, especially regarding craniofacial growth and functional recovery. Multidisciplinary care and prospective, multicenter studies with standardized reporting are necessary to enhance evidence-based guidelines. By combining conservative and surgical strategies tailored to the patient's age and developmental status, clinicians can optimize functional restoration, aesthetic results, and long-term quality of life for children who have experienced facial trauma.

Key Words: Facial Bones, Growth and Development, Maxillofacial Injuries, Pediatrics, Treatment Outcome, Wounds and Injuries.

* Please cite this article as: Rasouli F, Zaeimdar M. Preserving Pediatric Maxillofacial Growth and Function after Trauma: A Narrative Review of Innovative Surgical Strategies and Long-Term Outcomes. J Ped Perspect 2026; 14 (3):20009-20018. DOI: [10.22038/jpp.2026.95316.5646](https://doi.org/10.22038/jpp.2026.95316.5646)

*Corresponding Author:

Mojtaba Zaeimdar; Postgraduate student, Department of Oral and Maxillofacial Surgery, School of Dentistry, Dental Research Center, Avicenna Institute of Clinical Sciences, Avicenna Health Research Institute, Hamadan University of Medical Sciences, Hamadan, Iran. E-Mail: Mojtabazaeimsrg@gmail.com

1- INTRODUCTION

Maxillofacial trauma in the pediatric population represents a distinct clinical domain that fundamentally differs from adult facial injuries. Although facial fractures in children make up a small percentage of overall traumatic injuries, they present significant diagnostic and therapeutic challenges due to the unique anatomical, developmental, and biomechanical characteristics of the growing facial skeleton (1). In early childhood, a higher cranial-to-facial volume ratio and increased elasticity of facial bones provide natural protection against fractures. However, as craniofacial growth progresses, the face becomes more prominent and susceptible to injury, leading to age-dependent shifts in fracture patterns and causes (2). These developing structures, combined with the presence of mixed dentition and active growth centers, require clinicians to adopt management strategies that balance immediate fracture stabilization with the preservation of normal skeletal development and long-term function (3). Epidemiological evidence shows that the incidence of pediatric facial fractures increases with age, with low rates in infants and pre-school children and higher rates in adolescents, often reflecting behavioral exposure and participation in higher-risk activities (4). Falls, sports-related injuries, motor vehicle collisions, and interpersonal violence have all been identified as leading causes of trauma in this age group, with regional variations depending on demographic and socioeconomic factors (5). While mandible and nasal fractures are frequently reported in studies, the distribution of injury types may vary, underscoring the importance of individualized diagnostic protocols tailored to patient age and mechanism of injury (6). The management of pediatric maxillofacial trauma must consider more than just anatomical reduction. Unlike

adults, children's facial bones have higher osteogenic potential and a greater proportion of cancellous bone, which facilitates rapid healing but also increases the risk of growth disturbance if interventions are poorly timed or improperly executed (7). Therefore, the decision-making process often requires a careful evaluation of the risks and benefits of conservative versus surgical approaches, with the overarching goal of minimizing iatrogenic damage to growth centers, preserving occlusal development, and preventing long-term functional or aesthetic issues (8). Despite advances in imaging and surgical techniques, there remains considerable heterogeneity in clinical practice regarding diagnostic pathways, surgical indications, and long-term outcome assessment in pediatric patients with facial trauma. Additionally, much of the current evidence comes from retrospective single-center studies, highlighting the need for a comprehensive synthesis and critical analysis of available data (9). Therefore, the primary aim of this narrative review is to consolidate current evidence on innovative, growth-preserving surgical strategies for pediatric maxillofacial trauma and evaluate their long-term functional and aesthetic outcomes. By integrating epidemiological trends, diagnostic challenges, treatment modalities, and clinical outcomes, this review aims to inform evidence-based clinical decision-making and identify gaps in the literature that require further investigation.

2- METHODS

This narrative review was conducted following a structured yet flexible approach designed to synthesize current evidence on pediatric maxillofacial trauma while allowing for a comprehensive, qualitative integration of findings. The review aimed to identify, summarize, and critically evaluate studies addressing surgical strategies that preserve

growth and long-term function in children following facial trauma. Literature Search Strategy A systematic search of electronic databases, including PubMed, MEDLINE, Embase, Scopus, Web of Science and Google Scholar, was performed to identify relevant studies published up to March 2026. The search strategy combined Medical Subject Headings (MeSH) and free-text terms related to pediatric facial trauma, maxillofacial fractures, growth-preserving surgery, and long-term outcomes. Examples of search terms included:

((("Maxillofacial Injuries"[Mesh] OR "Facial Injuries"[Mesh] OR "Wounds and Injuries"[Mesh] OR maxillofacial trauma[tiab] OR facial trauma[tiab]) AND ("Child"[Mesh] OR "Infant"[Mesh] OR "Adolescent"[Mesh] OR "Pediatrics"[Mesh] OR pediatric*[tiab] OR paediatric*[tiab] OR child*[tiab]) AND ("Surgical Procedures, Operative"[Mesh] OR "Reconstructive Surgical Procedures"[Mesh] OR "Fracture Fixation"[Mesh] OR "Minimally Invasive Surgical Procedures"[Mesh] OR "Computer-Assisted Surgery"[Mesh] OR "3D Printing"[Mesh] OR "Tissue Engineering"[Mesh] OR surg*[tiab] OR reconstruct*[tiab] OR innovat*[tiab]) AND ("Growth and Development"[Mesh] OR "Craniofacial Development"[Mesh] OR growth[tiab] OR development[tiab] OR function*[tiab]) AND ("Treatment Outcome"[Mesh] OR "Prognosis"[Mesh] OR "Quality of Life"[Mesh] OR long-term[tiab] OR outcome*[tiab])).

References of retrieved articles were also screened manually to capture additional relevant publications. Eligibility Criteria Studies were included if they met the following criteria: [1] focused on patients aged 0–18 years; [2] reported on surgical or conservative management of maxillofacial trauma; [3] provided information on outcomes related to

growth, function, or aesthetics; and [4] were published in English. Review articles, case series, retrospective and prospective cohort studies, and clinical guidelines were considered. Exclusion criteria were studies on isolated dental trauma, non-traumatic congenital facial deformities, or animal models. Data Extraction and Synthesis Data were extracted independently by two reviewers using a standardized extraction form, capturing study characteristics, patient demographics, fracture type, treatment modality, follow-up duration, and reported outcomes. Discrepancies were resolved through discussion or consultation with a third reviewer. Given the heterogeneity of study designs and outcome measures, a qualitative synthesis was performed. Findings were organized thematically, focusing on [1] epidemiology and injury patterns, [2] diagnostic and imaging considerations, [3] surgical techniques and growth-preserving strategies, and [4] functional and aesthetic outcomes. Quality Assessment Although narrative reviews do not typically involve formal meta-analysis, included studies were critically appraised for methodological rigor, sample size, follow-up adequacy, and potential biases. Emphasis was placed on the reliability and generalizability of reported outcomes to provide clinically meaningful insights for practitioners. This approach ensured a comprehensive yet critical overview of current evidence, highlighting both established practices and emerging innovations in the management of pediatric maxillofacial trauma, with a particular focus on strategies that safeguard growth and long-term facial function.

3-RESULT

The literature on pediatric maxillofacial trauma demonstrates consistent epidemiological and clinical patterns across diverse geographic settings.

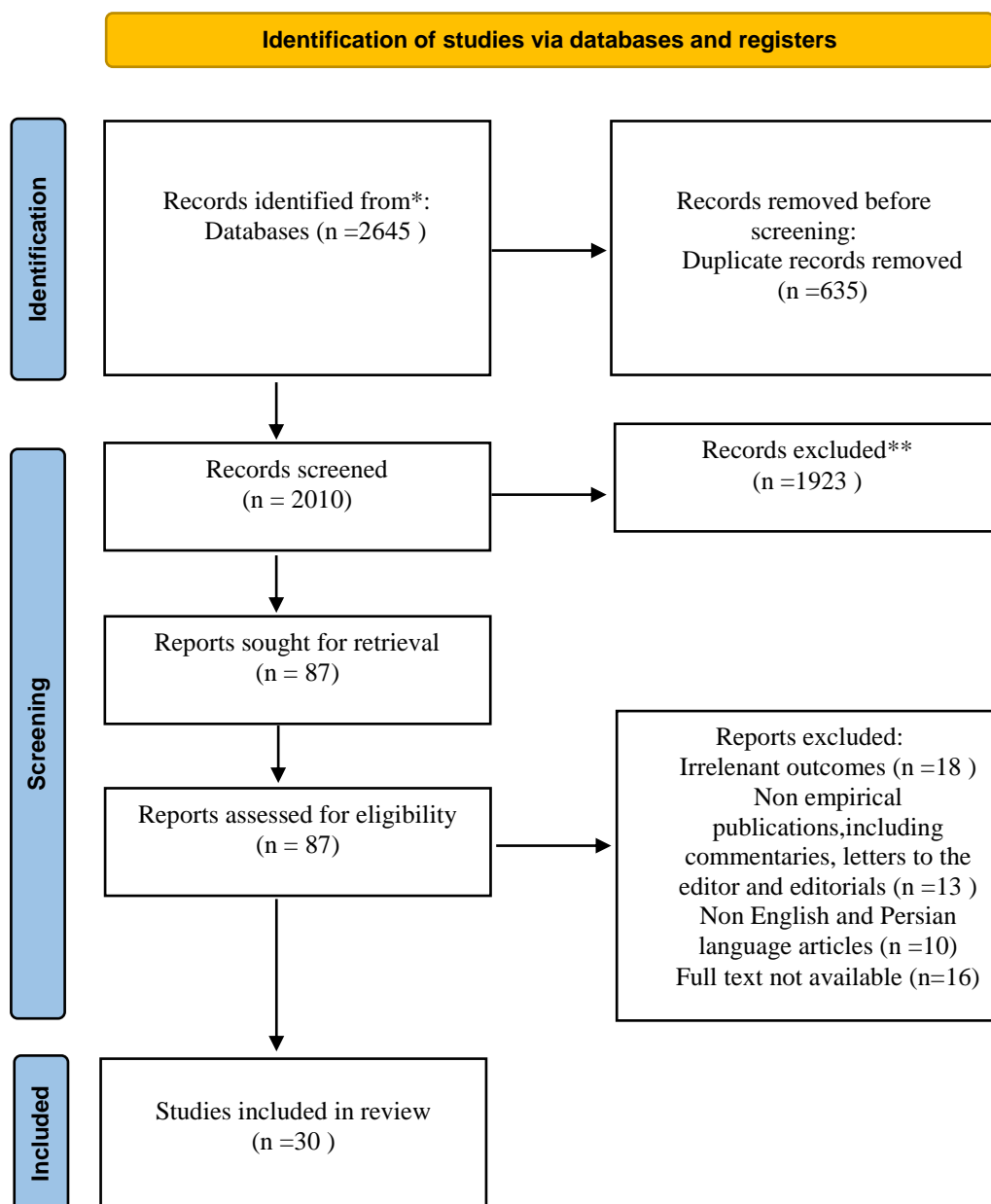


Figure-1: Search flow diagram (10).

Multiple large series and retrospective cohorts indicate that the incidence of facial fractures increases with age, with adolescents comprising the largest proportion of injured patients (11). This trend is attributed to increased participation in high-energy activities, such as sports and road traffic exposure, compared to younger children who more commonly sustain injuries from falls or domestic accidents. In most clinical cohorts, male predominance is evident,

with male-to-female ratios substantially greater than 1:1, particularly in older age groups (12). Furthermore, midfacial fractures frequently account for a majority of cases, with orbital floor fractures emerging as the single most commonly diagnosed injury in certain institutional series (13). Mandibular fractures, including those affecting the condylar region, are also prevalent and represent a significant focus for treatment planning. Mechanisms of injury vary with age and

activity patterns (14). Traffic accidents are often reported as the most frequent cause overall, followed by falls, sports-related impacts, and interpersonal violence in older children. These etiological patterns correlate with both fracture distribution and the need for surgical intervention, highlighting the importance of considering contextual risk factors in trauma prevention and clinical assessment (15). From a treatment standpoint, management strategies are highly individualized based on fracture type, displacement severity, occlusal disruption, and the presence of associated injuries. Non displaced or minimally displaced fractures with preserved occlusion are generally managed conservatively through observation, soft diet protocols, or maxillomandibular fixation when indicated (16). Conversely, open reduction and internal fixation (ORIF) remain the principal surgical modality for displaced or unstable fractures, particularly in the mandible and orbital regions, where functional deficits such as diplopia or extraocular muscle entrapment may occur. Age adapted surgical approaches are also reported, with transconjunctival access commonly used for orbital floor reconstruction to minimize external scarring and preserve periocular function (17). Reconstruction of bony defects often entails autologous bone grafting, though donor site selection must account for developing dentition and growth centers in younger children. In some instances, alternative graft sites such as calvarial bone are preferred to avoid disruption of dental development (18). Across multiple clinical reports, postoperative complications remain relatively low when appropriate surgical principles are applied. Minor transient nerve dysfunction and device removal for growth considerations are among the most frequently documented events, while infection and long term functional deficits are uncommon when treatment is individualized and growth preserving

techniques are prioritized (19). Finally, analysis of trauma patterns over extended periods suggests that major societal disruptions, such as the COVID 19 pandemic, do not substantially alter the underlying mechanisms of pediatric facial trauma, reinforcing the notion that age specific activity exposures remain the dominant determinants of injury trends (20).

4- DISCUSSION

The findings from current literature emphasize that pediatric maxillofacial trauma encompasses a spectrum of injuries that are clinically and epidemiologically distinct from those seen in adults, primarily due to the ongoing development of the pediatric craniofacial skeleton and its biomechanical properties (21). Children's facial bones exhibit increased elasticity and a greater ratio of cancellous to cortical bone, which often leads to unique fracture patterns and a higher incidence of greenstick or minimally displaced fractures compared with adults (22). These characteristics partially explain why conservative treatment remains a mainstay in many pediatric cases, particularly when occlusion is maintained and displacement is minimal. One consistent pattern across multiple studies is the age-dependent variation in both incidence and type of injuries (23). Younger children frequently sustain injuries from low-energy mechanisms, such as falls, whereas adolescents are more often exposed to high-energy trauma, including motor vehicle collisions and sports-related impacts. This age stratification influences not only fracture distribution but also the necessity for surgical intervention; older children and adolescents exhibit higher rates of operative management due to increased displacement and complexity of fracture configurations (24).

Table-1. Characteristics of Selected Key Studies.

First Author (Year)	Study Design	Sample Size	Focus Area	Treatment Approach	Key Findings
Hofmann (2023) (1)	Clinical study	112	Mandibular fractures	Conservative & surgical	Emphasizes age-adapted treatment and growth preservation
Cleveland (2021) (2)	Retrospective	124	Mandibular fracture site	Mixed	Age strongly associated with fracture pattern
Kelimu (2024) (4)	Retrospective	211	Epidemiology	Mixed	incidence increases with age; males predominant
Juncar (2023) (5)	Retrospective	123	Clinical patterns	Mixed	Treatment depends on fracture type and displacement
Patidar (2024) (7)	Retrospective	312	Pediatric trauma patterns	Conservative focus	Highlights high healing potential in children
Laforgia (2025) (11)	Epidemiological	221	Dental/maxillofacial trauma	Preventive + clinical	Supports early intervention and tailored care
Bottini (2024) (12)	Multicenter retrospective	180	Condylar fractures	Conservative vs surgical	Functional outcomes comparable when properly selected
Jenkyn (2023) (13)	Systematic review	178	Condylar fractures	Mixed	No consensus; individualized treatment required
Ohayon (2025) (14)	Comparative study	160	Condylar fractures	Conservative vs surgical	Decision depends on displacement and function
Irgebay (2024) (15)	Large cohort	3334	Injury patterns	Mixed	Mechanism influences fracture type and management

Gender differences have also been recurrently observed, with male children demonstrating a higher overall incidence of maxillofacial fractures compared to females. This disparity may reflect behavioral and activity-related risk factors rather than inherent biological differences, which underscores the role of preventive strategies tailored to high-risk groups (25). From a treatment perspective, the principle of growth preservation remains a central theme in pediatric trauma management. The literature indicates that while conservative methods such as observation, soft diet, or closed reduction with

maxillomandibular fixation are effective for non displaced or minimally displaced fractures, open ORIF is necessary when functional deficits such as malocclusion, occlusal disturbance, or ocular muscle entrapment are present. Importantly, contemporary surgical approaches aim to minimize disruption of facial growth centers, using age appropriate fixation devices and bioabsorbable materials when feasible to reduce long term sequelae. Multicenter retrospective analyses further support a function oriented rather than anatomy driven surgical decision-making paradigm (26). For instance, midfacial and

orbital floor fractures often necessitate surgical exploration due to the risk of extraocular muscle entrapment or diplopia conditions that can significantly impair long term function if left untreated. In contrast, nondisplaced upper third

craniofacial fractures often respond well to nonoperative strategies, aligning with the concept that minimizing intervention can allow natural remodeling facilitated by the pediatric osteogenic potential (27).

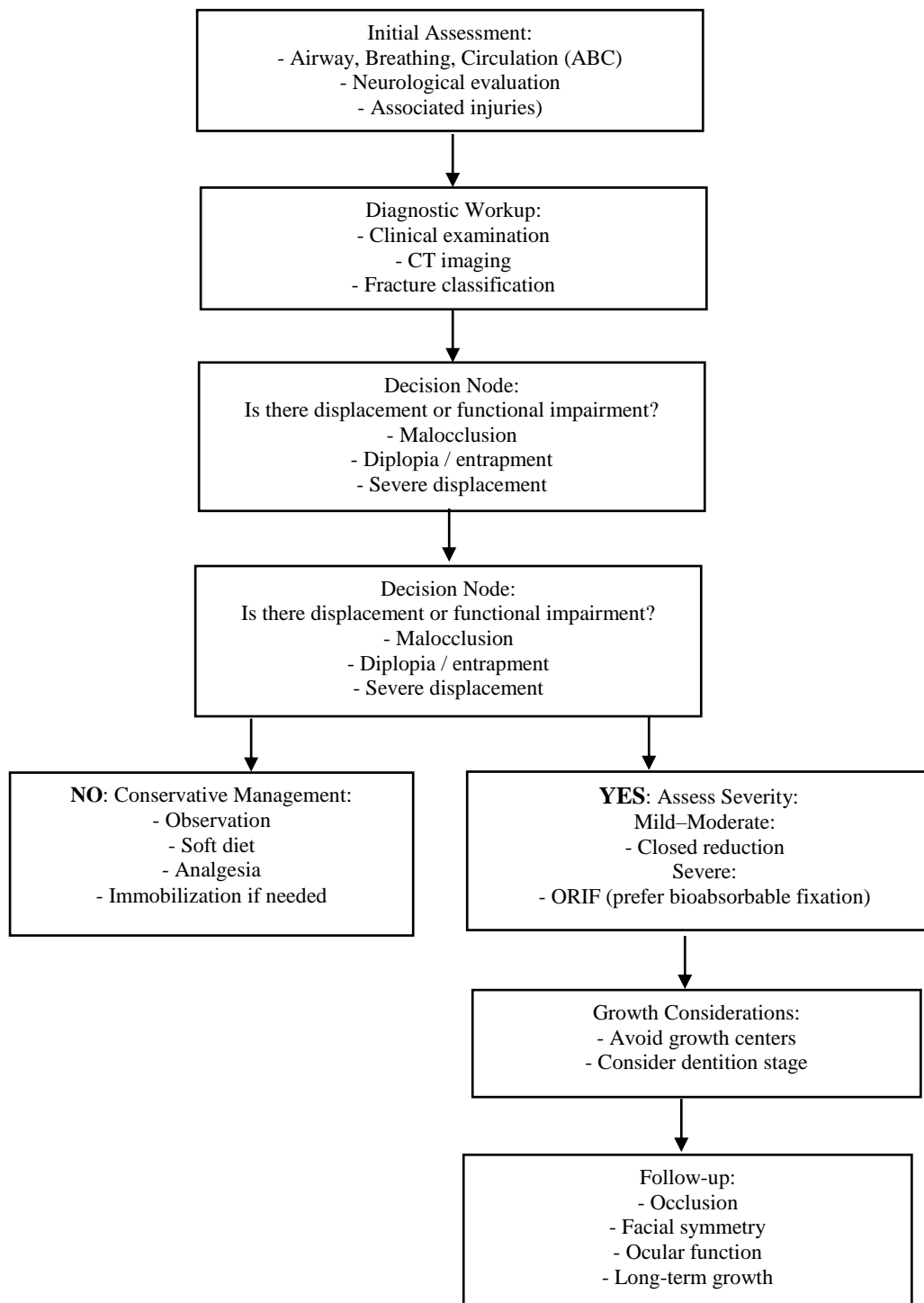


Figure-2: Clinical Decision-Making Algorithm for Pediatric Maxillofacial Trauma.

Despite the progress in understanding pediatric maxillofacial trauma, the heterogeneity of study designs and outcome measures represents a notable limitation in the existing evidence. Many studies are retrospective and single center, with variable follow up durations, making it challenging to draw definitive conclusions on long term growth and aesthetic outcomes. As a result, there remains a pressing need for prospective, multicenter research to establish robust, evidence based guidelines that can standardize care across institutions and inform risk stratification (28). Clinically, these findings reinforce the importance of a multidisciplinary approach to pediatric facial trauma, involving pediatric surgeons, maxillofacial specialists, and rehabilitation teams to ensure comprehensive care that addresses both immediate functional needs and the preservation of normal craniofacial development (29). Early identification of high risk injuries and thoughtful integration of conservative and surgical strategies tailored to each patient's age and developmental status are critical to optimizing outcomes.

4-1. Limitations

This review is limited by the predominance of retrospective, single-center studies with heterogeneous patient populations, fracture types, and follow-up durations. Long-term growth and functional outcomes are often inconsistently reported, and variability in surgical techniques and outcome measures limits direct comparison across studies. Additionally, as a narrative review, the methodology is susceptible to selection and interpretation bias, highlighting the need for prospective, multicenter research with standardized reporting to strengthen the evidence base.

5- CONCLUSION

Pediatric maxillofacial trauma presents unique clinical challenges due to the ongoing growth and development of the facial skeleton, age-dependent fracture patterns, and the presence of mixed dentition. Evidence from the current literature indicates that treatment strategies must be individualized, balancing the need for anatomical reduction and functional restoration with preservation of growth centers and long-term craniofacial development. Conservative management remains appropriate for non-displaced or minimally displaced fractures, whereas surgical intervention including open reduction and internal fixation should be reserved for displaced, unstable, or functionally compromising injuries (30). The review highlights that age-adapted, growth-preserving surgical approaches including the use of bioabsorbable fixation devices and minimally invasive techniques can achieve favorable functional and aesthetic outcomes while minimizing long-term complications. Moreover, a multidisciplinary approach that incorporates pediatric, maxillofacial, and rehabilitation expertise is essential for optimizing clinical outcomes and ensuring comprehensive care. Despite these advancements, significant gaps remain in the literature, particularly concerning standardized outcome measures, long-term follow-up data, and multicenter prospective evidence. Future research should focus on developing evidence-based guidelines that integrate epidemiological trends, surgical innovations, and long-term functional outcomes to provide clinicians with robust, age-specific recommendations. By emphasizing growth preservation, functional restoration, and individualized care, clinicians can improve both immediate and lifelong outcomes for children sustaining facial trauma.

6- REFERENCES

1. Hofmann E, Koerdt S, Heiland M, Raguse JD, Voss JO. Pediatric maxillofacial trauma: insights into diagnosis and treatment of mandibular fractures in pediatric patients. *International journal of clinical pediatric dentistry*. 2023 May;16(3):499.
2. Cleveland CN, Kelly A, DeGiovanni J, Ong AA, Carr MM. Maxillofacial trauma in children: Association between age and mandibular fracture site. *American Journal of Otolaryngology*. 2021 Mar 1;42(2):102874.
3. Massenburb BB, Lang MS. Management of panfacial trauma: sequencing and pitfalls. In *Seminars in plastic surgery* 2021 Nov (Vol. 35, No. 04, pp. 292-298). Thieme Medical Publishers, Inc..
4. Kelimu K, Wusiman P, Li W, Huang B, Wu J, Zhan J, et al. Epidemiology and pattern of pediatric maxillofacial trauma: a 5-year retrospective study. *Journal of Craniofacial Surgery*. 2024 Jan 1;35(1):150-3.
5. Juncar RI, Moca AE, Juncar M, Moca RT, Țenț PA. Clinical patterns and treatment of pediatric facial fractures: a 10-year retrospective Romanian study. *Children*. 2023 Apr 28;10(5):800.
6. Singh P, Mishra P, Tiwari T, Singh GP. Airway consideration in maxillofacial trauma. *The Traumaxilla*. 2022 Dec;4(1-3):19-25.
7. Patidar D, Sogi S, Fry RR, Patidar DC, Malhotra A. Maxillofacial Trauma in Pediatric Patients: A Retrospective Study. *Journal of maxillofacial and oral surgery*. 2024 Feb;23(1):99-106.
8. Forrester JD, Wolff CJ, Choi J, Colling KP, Huston JM. Surgical infection society guidelines for antibiotic use in patients with traumatic facial fractures. *Surgical infections*. 2021 Apr 1;22(3):274-82.
9. Alhabshi MO, Taweel DM, Alahmary HM, Al-Suhaymi OH, Al-Bander MR, Al-Suroor TA, et al. The role of orthodontics in the management of maxillofacial fractures in children: a review on contemporary approaches. *Cureus*. 2024 Jun 25;16(6).
10. Page MJ, McKenzie JE, Bossuyt PM, Boutron I, Hoffmann TC, Mulrow CD, et al. The PRISMA 2020 statement: an updated guideline for reporting systematic reviews. *bmj*. 2021 Mar 29;372.
11. Laforgia A, Inchingolo AM, Inchingolo F, Sardano R, Trilli I, Di Noia A, et al. Paediatric dental trauma: insights from epidemiological studies and management recommendations. *BMC Oral Health*. 2025 Jan 2;25(1):6.
12. Bottini GB, Hitzl W, Götzinger M, Politis C, Dubron K, Kordić M, et al. Management of mandibular condyle fractures in pediatric patients: a multicentric retrospective study with 180 children and adolescents. *Journal of Clinical Medicine*. 2024 Sep 14;13(18):5455.
13. Jenkyn I, Bosley R, Jenkyn C, Basyuni S, Fowell C. Management of mandibular condyle fractures in paediatric patients: a systematic review. *Journal of Oral & Maxillofacial Research*. 2023 Jun 30;14(2):e2.
14. Ohayon C, Perelman A, Katz Biton A, Krasovsky A, Zeineh N, Ginini JG, et al. Conservative vs. Surgical management of condylar fractures in pediatric populations: complications and factors for consideration. *Children*. 2025 Mar 3;12(3):323.
15. Irgebay Z, Glenney AE, Beiriger JW, Smetona J, Dixon AN, Kass NM, et al. Pediatric facial fractures: demographics, injury patterns, and associated injuries in 3334 patients. *Journal of Craniofacial Surgery*. 2024 Sep 1;35(6):1783-7.

16. Rashid A, Feinberg L, Fan K. The application of cone beam computed tomography (CBCT) on the diagnosis and management of maxillofacial trauma. *Diagnostics*. 2024 Feb 8;14(4):373.
17. Wolfs E, Arzi B, Guerrero Cota J, Kass PH, Verstraete FJ. Craniomaxillofacial trauma in immature dogs—etiology, treatments, and outcomes. *Frontiers in Veterinary Science*. 2022 Aug 15;9:932587.
18. Rador MC, Çiçek Ç, Uğurlu Y, Filinte GT. Pediatric mandibular condyle fractures: A decade of experience. *Journal of Cranio-Maxillofacial Surgery*. 2026 Mar 1;54(3):104455.
19. Yesantharao PS, Lopez J, Reategui A, Jenny H, Najjar O, Yu JW, et al. Combined symphyseal and condylar fractures: considerations for treatment in growing pediatric patients. *Plastic and reconstructive surgery*. 2021 Jul 1;148(1):51e-62e.
20. Shenoi R, Rajguru J, Sangani S, Kolte V, Bhave I, Karmarkar J, et al. Changing patterns of Oral & Maxillofacial injuries before and during COVID-19 pandemic: A retrospective study. *Journal of oral biology and craniofacial research*. 2022 Sep 1;12(5):651-5.
21. Kocaaslan ND, Ünal BK, Özkan MÇ, Karadede B, Çelebiler Ö. Comparison of different treatment techniques in the mandibular condyle fracture. *Turkish Journal of Trauma & Emergency Surgery*. 2022 Jan 3;28(1):99.
22. Piccini GB, Sfondrini D, Tomulescu SA, Esposito C, Piccioni A, Caputo G, et al. Modern management of maxillofacial trauma in the emergency department. *World Journal of Emergency Medicine*. 2026 Jan 1;17(1):15.
23. Chung CY, Peterson RB, Howard BM, Zygmunt ME. Imaging intracranial aneurysms in the endovascular era: surveillance and posttreatment follow-up. *Radiographics*. 2022 May;42(3):789-805.
24. Alghamdi Jr FS, Alsabbali DM, Qadi YH, Albugami SM, Lary A, Alsabbali D, et al. Patterns and impact of traumatic brain injury at King Abdulaziz Medical City in Jeddah, Saudi Arabia: a retrospective cohort study. *Cureus*. 2021 Dec 7;13(12).
25. Iyer J, Hariharan A, Cao UM, Tran SD. Acquired facial, maxillofacial, and oral asymmetries—a review highlighting diagnosis and management. *Symmetry*. 2021 Sep 9;13(9):1661.
26. Van der Cruyssen F, Forrest M, Holmes S, Bhatti N. A systematic review and meta-analysis of fracture-related infections in maxillofacial trauma: incidence, risk factors, and management strategies. *Journal of clinical medicine*. 2025 Feb 17;14(4):1332.
27. Sameh S, Mekhaeel M, Andrey P, Nada T, Mohamed A, Noureldin S. Outcomes of a Pediatric Facial Fracture Reconstruction. *Case Report. Archiv EuroMedica*. 2024;14(6):5.
28. Aksoyler D, Doğan F, Bolletta A, Sengenc E, Sönmez T, Yavan MA. Management of medially displaced subcondylar mandibular fractures in pediatric population using novel atraumatic approach. *Journal of Craniofacial Surgery*. 2021 May 1;32(3):851-4.
29. Sha X, Jin L, Han J, Li Y, Zhang L, Qi S. Comparison between periapical radiography and cone beam computed tomography for the diagnosis of anterior maxillary trauma in children and adolescents. *Dental Traumatology*. 2022 Feb;38(1):62-70.
30. Kumar R, Singh V, Dutta KD. Paediatric Maxillofacial Trauma: An Overview of Incidence, Challenges and Management. *Advances in Human Biology*. 2024 Apr 1;14(2):148-52.