

## Efficacy of Point Of Care Ultrasound in Detecting Central Line Tip Position in Neonates

Shobana Sridhar <sup>1</sup>, \* Kanimozhi Thandapani <sup>2</sup>, Bharath Kumar Thirunavukarasu <sup>3</sup>

<sup>1</sup> Post Graduate, Department of Paediatrics, Sri ManakulaVinayagar Medical College and Hospital, Puducherry-605107, India.

<sup>2</sup> Associate Professor, Department of Paediatrics, Sri ManakulaVinayagar Medical College and Hospital, Puducherry-605107, India.

<sup>3</sup> Professor, Department of Paediatrics, Sri ManakulaVinayagar Medical College and Hospital, Puducherry-605107, India.

### Abstract

**Background:** This study attempted to compare radiographic findings with that of the ultrasound in locating the central line tip and evaluate the agreement between these two diagnostic modalities.

**Methods:** This hospital-based Prospective Observational Comparative Diagnostic Accuracy Test study was conducted on 51 neonates, in the NICU of a tertiary health care centre. A consecutive sampling technique was used for the neonates included in this study. The central catheter (umbilical vein catheter / peripherally inserted central catheter) was inserted. After the central line insertion, a thoracoabdominal X-ray was done to identify the catheter tip position as the standard protocol. USG assessment of the central line tip position was also done.

**Results:** Out of the 51 central lines studied, 49 were UVC and 2 were PICC line insertion. USG was able to identify all the malpositioned (n=38) and optimally placed central line tips (n=10) as in X-ray and also additionally identified the three doubtful tips on X-ray as malpositioned (n=1) and optimally placed (n=2). X-ray showed that 78.5% of UVCs were low lying and 66.6% were in intrahepatic IVC as identified by USG. Among the procedure-related complications, post X-ray more complications were noted, the most common being hypothermia.

**Conclusion:** Our study results show that Point Of Care Ultrasound is a safer, more efficacious, and quick bedside diagnostic test compared to the conventional radiography in detecting central line tip position in neonates, helping pediatricians to quickly confirm the central line tip position before starting infusions.

**Key Words:** Central Line Tip Position, Neonates, Malposition, Point of Care Ultrasound, Radiography.

\* Please cite this article as: Sridhar S, Thandapani K, Kumar T B. Efficacy of Point Of Care Ultrasound in Detecting Central Line Tip Position in Neonates. Int J Ped Perspect 2024; 12 (06):18851-18858. DOI: [10.22038/ijp.2024.73226.5305](https://doi.org/10.22038/ijp.2024.73226.5305)

### \*Corresponding Author:

Kanimozhi Thandapani. Associate Professor, Department of Paediatrics, Sri ManakulaVinayagar Medical College and Hospital, Puducherry-605107, India. Email: [drkani88@gmail.com](mailto:drkani88@gmail.com)

Received date: Mar.10,2023; Accepted date:Oct.06,2024

## 1- INTRODUCTION

Central lines like Umbilical Vein Catheter (UVC) and Peripherally Inserted Central Catheter (PICC) placement are among the commonly performed procedures in NICU. They are highly essential for the administration of drugs, nutrition, and transfusion of blood and blood products in neonates. Identifying the catheter tip position is necessary to ensure that the catheter is optimally placed because the malpositioned catheter tip can be even fatal to life by not delivering the drugs due to kinking, coiling, or complications associated with their malposition like thrombosis of the portal vein, hepatic necrosis (1). The routine standard protocol to identify tip position is a plain radiograph of the thoracoabdominal region. It has disadvantages like radiation exposure, time delay, unnecessary handling and movement of the baby, contact with a person who may be unsterile, and repeat radiation exposure in case of malposition. The following is the course of the umbilical vein catheter, it enters the umbilical vein, then into the left portal vein, into ductus venosus, into the right or middle hepatic vein near the entry into the inferior vena cava just below the diaphragm. The last part of this complex course is in the sagittal plane; therefore, it is not visualized properly on the AP view on a plain radiograph of the thoracoabdominal region. The recent advances in imaging modalities provide us with high-resolution transducers with which we can visualize the intrahepatic portion of the catheter (2). So, Point of Care USG (POCU) is gaining interest as an emerging bedside tool in the management of sick neonates to locate catheter tips during and after the procedure (1-6). POCU has no radiation emission, is easily available at the bedside, doesn't need any movement of the baby, can be repeated without any harm, can be done by doctors themselves

in a sterile way and with utmost care in handling fragile and critically ill babies. It has the advantage over radiography in detecting hepatic lacerations, abscesses, and other subtle findings. Several studies have very well documented the malposition-related complications in neonates (7-9). Recent studies have also documented that these malpositions have been missed on the initially done radiography but have been detected by the ultrasound done later while evaluating the cause for the signs and symptoms associated with the complications (10). Thus, we attempted to compare radiographic findings with that of the ultrasound in locating the central line tip and evaluate the agreement between these two diagnostic modalities.

## 2- MATERIALS & METHODS

This hospital-based Prospective Observational Comparative Diagnostic Accuracy Test study was conducted in the Neonatal Intensive Care Unit in a tertiary health care centre. All neonates admitted to the NICU who underwent central line catheter placement during the study period were included. Neonates with abdominal wall defects, NEC, GI obstruction, pneumo-peritoneum, and abdominal distention obscuring the visualization by USG and those whose Parents refused to give consent were excluded from the study. Using the sensitivity of 96.5% for ultrasound imaging based on the findings of Telang et al. published in 2017, the sample size was calculated to be 51 at a 95% confidence interval and absolute precision of 5% using the software master 2.0 version 30 (11). A consecutive sampling technique was used for the neonates included in this study.

All neonates fulfilling the inclusion criteria were enrolled in the study after obtaining written informed consent from their parents. The central catheter (umbilical vein catheter / peripherally inserted central catheter) was inserted by

the consultant on duty using standard techniques. For UVC insertion, the weight based Shukla formula was used (12). For the PICC line in the upper and lower limb, the length of insertion was measured from the point of insertion along the venous pathway to the suprasternal notch, then down to the right, and third intercostal space till the level of xiphisternum, respectively.

After the central line insertion, a thoracoabdominal X-ray was done to identify the catheter tip position as the standard protocol. On X-ray UVC and lower limb PICC, the tip was considered optimal if the tip was at the level of the diaphragm or slightly above or at the level of T8 to T9. For upper limb PICC, the tip is optimal, if within the superior vena cava within 1- 2 vertebral units below carina (1).

USG assessment of the central line tip position was done by a Radiologist or by the principal investigator under the guidance of a radiologist. Fujifilm Sonosite machine with a curvilinear probe of 2 to 5 MHz covered with a sterile glove was used with minimal contact time. Proper hand hygiene measures were followed, also personal protective equipment like a mask, cap, sterile gloves, and apron was worn by the Radiologist and Principal Investigator. The local part to be examined was sterilized with an alcohol-based sanitizer. A subxiphoid right parasagittal view was used to assess the tip position of UVC and lower limb PICC and a high parasternal view for upper limb PICC.

If the catheter tip was not visible using standard techniques of 0.5 to 1 ml of normal saline was flushed through the catheter to locate the tip which was seen as a point of origin of the jet. For UVC and PICC line through the lower limb, the optimal position was defined as the catheter tip at the Inferior Vena Cava –

right atrial junction (i.e. the level of the diaphragm at Inferior vena cava) or 0.5 – 1 cm proximal to it. For the PICC line through the upper limb, the optimal position was defined as the tip position at the superior vena cava – right atrial junction or 0.5 to 1 cm proximal to it. After completion of the USG assessment, the local part was cleaned with alcohol-based sanitizer and the neonate's normothermic state was ensured (1).

### 3- RESULTS

Out of 51 neonates included in our study, the majority (56.9%) were female babies (n=29), based on gestational age, most of the babies (54.9%) belonged to the 34 to 36 weeks category (n=28). 58.8% (n=30) were low birth weight babies and the majority were delivered by emergency LSCS (78.4 %). The requirement for antibiotics and IV fluids were the most common indications (86.3%) and in 96.07 % of the babies UVC was done in this study. Table 1 shows the baseline data of study participants.

Analyzing the central line tip position on X-ray, 74.5% (n=38) were malpositioned, only 19.6% (n=10) were optimally positioned and the remaining three were doubtful. Whereas USG identified, 76.4% (N=39) as malpositioned, 23.5% (n=12) as optimally positioned (Fig. 1).

Among the malposition sites based on X-ray, 78.9% (n=30) were low lying and 21.05% (n=8) were high lying. Based on USG, 66.6 % (n=26) were in intrahepatic IVC followed by 12.6% (n=6) in thoracic IVC. Table 2 shows malpositioned sites based on X-ray and USG. Among the 39 central line tips which were found to be malpositioned (as per POCU) in our study only 8 were repositioned as only 8 were high lying (as advancing a low-lying central line further inside is associated with sepsis). The repositioned tip position was confirmed to be optimally placed by both the USG and X-ray.

**Table-1:** Baseline data of the study participants (n=51)

Variables		N (%)
Gender	Male	22 (43.1 %)
	Female	29 (56.9 %)
Gestational age	28 to 33 weeks	13 (25.5 %)
	34 to 36 weeks	28 (54.9 %)
	37 to 41 weeks	10 (19.6 %)
Birth weight	Normal (2.5 to 4.0 kg)	13 (25.5 %)
	LBW (1.5 to 2.49 kg)	30 (58.8 %)
	VLBW (1.0 to 1.49 %)	8 (15.7 %)
Mode of delivery	Normal vaginal delivery	8 (15.7 %)
	Elective LSCS	3 (5.9 %)
	Emergency LSCS	40 (78.4 %)
APGAR score at 5 minutes	Severely depressed (zero to three)	3 (5.9 %)
	Moderately depressed (four to six)	3 (5.9 %)
	Excellent (seven to ten)	45 (88.2 %)
Central line indication	Antibiotics and IV fluids	44 (86.3%)
	IV fluids alone	2 (3.9 %)
	Inotropes	4 (7.84 %)
	Partial exchange transfusion	1 (1.96 %)
Central line type	UVC	49 (96.07 %)
	PICC	2 (3.9 %)

**Table-2:** Malposition sites based on Xray (N=38) and USG (N=39)

Malposition sites	Value	N (%)
On Xray (n=38)	Low lying	30 (78.9 %)
	High lying	8 (21.05 %)
On USG (n=39)	Right atrium	2 (5.12 %)
	Thoracic IVC	6 (12.82 %)
	Intrahepatic IVC	25 (66.66 %)
	Portal vein	2 (5.12 %)
	Hepatic vein	4 (10.3 %)

Comparing USG against Xray in identifying the tip of the catheter shows that there was a statistically significant ( $p < 0.001$ ) difference between the findings of the two diagnostic methods in the chi-square test. USG identified all catheter tip positions including the three which were doubtful on X-ray (Table 3).

The Measure of Agreement (Cohen's Kappa inter-rater Agreement) between the

two diagnostic methods for identifying the central line tip position revealed that there was a good agreement between the x-ray-based and USG-based methods for identifying catheter tip malpositions [K(95% CI) - 0.735 (0.624 to 0.846)] and this finding was statistically significant (&lt; 0.0001) (Table 4).

In our study, we found that the sensitivity and specificity for USG (POCU) as

compared to X-Ray were 94.7% (95% CI: 80.9 to 99.0) and 76.9% (95 % CI: 45.9 – 93.8), respectively. The positive and negative predictive values were 92.3% (95

% CI: 78 .0 – 97.9) and 83.3 % (95 % CI: 50.8 to 97.0), respectively for USG (POCU) (Table 5).

**Table-3:** Comparison of USG (test method) method against X-ray (gold standard) method for identifying malpositions of catheters

Variable		X-ray Identification N=51		P value
		Malposition* n (%)	Normal n (%)	
USG Identification	Malposition (N=39)	36 (94.7)	3 (23.1)	<0.001
	Normal (N=12)	2 (5.3)	10 (76.9 )	
Totals		38 (100)	13 (100)	

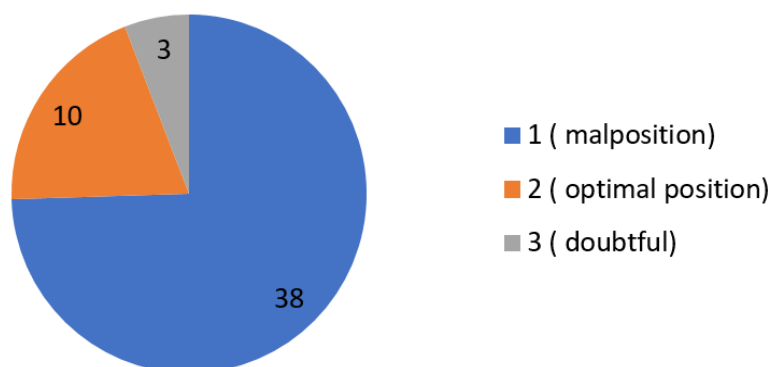
\* For bivariate analysis purpose, category “doubtful” was recorded to be included in the malposition group

**Table-4:** Cohen’s Kappa inter-rater Agreement between the two methods (N=51)

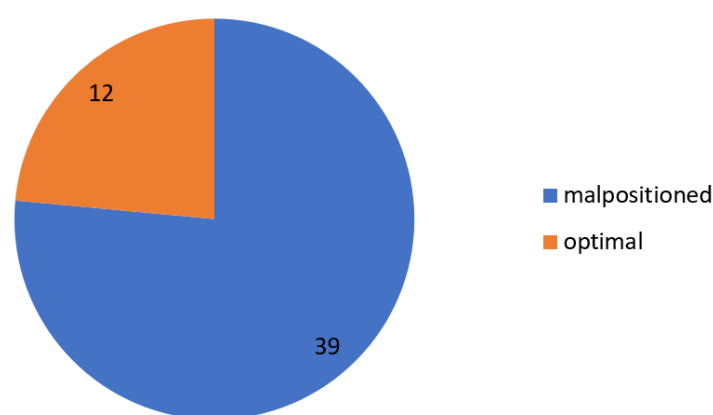
Variable		Value	Asymptotic Standardized Error	95% CI for Kappa	Approximate Significance
Measure of Agreement	Kappa	0.735	0.111	(0.624 - 0.846)	<0.001

**Table-5:** Accuracy parameters of USG method for identifying catheter malpositions as against X-ray method

Test Accuracy Parameters	Estimated Value	95% Confidence Interval	
		Lower Limit	Upper Limit
Sensitivity	0.947	0.809	0.990
Specificity	0.769	0.459	0.938
Positive Predictive Value (PPV)	0.923	0.780	0.979
Negative Predictive Value(NPV)	0.833	0.508	0.970



**Fig. 1:** Central line tip position on X-ray



**Fig. 2:** Central line tip position on USG

#### 4- DISCUSSION

Out of the 51 central lines studied, 49 were UVC and 2 were PICC line insertion. USG was able to identify all the malpositioned (n=38) and optimally placed central line tips (n=10) as in X-ray and also additionally identified the three doubtful tips on X-ray as malpositioned (n= 1) and optimally placed (n=2). X-ray showed that 78.5% of UVCs were low lying and 66.6% were in intrahepatic IVC as identified by USG. Among the procedure-related complications, post X-ray more complications were noted, the most common being hypothermia.

Among the baseline characteristics, the common gestational age category requiring a central line was related to preterm babies, especially late preterms (34 to 36 weeks). The studies done by Thakur et al., El-Maadawy et al., and Telang et al. revealed that the most common gestational age category requiring central line included the preterm babies (1, 11, 13). Among the birth weight category, the majority were low birth weight babies (1.5 kg to 2.49 kg) and the studies mentioned above also quoted the same. In our study, the major proportion comprised female babies which were 56.9% (n=51), and in the study done by Telang et al., fifty percent (n=31) were males (11). In our study, 78.4% (n=51) of

babies were delivered by emergency LSCS and similarly, Telang et al.'s study also had the majority of babies, i.e., 86% (n=31) delivered by cesarean section (11). In our study, the most common indication for the central line were antibiotics and IV fluids (86.3 %) and Telang et al. revealed that the indication for the central line in their study was the total parenteral nutrition – hundred percentage (11).

In our study we used the Shukla formula for UVC insertion length estimation and anatomical landmark-based estimation for PICC line insertion, whereas Dunn shoulder umbilical length nomogram was used for UVC and UAC insertion; and anatomical landmark-based estimation was used for PICC line insertion by Thakur et al. (1). On analyzing the central line position, 38 out of the 51 central lines were identified as malpositioned (74.5 %) by X-ray and 39 out of 51 central lines as malpositioned (76.5 %) by USG. X-ray identified 10 central line tips (19.6 %) as optimally placed and USG identified 12 central line tips (23.5 %) as optimally placed out of the 51 central lines. The three central line tips (5.9 %) which were doubtful on X-ray were also correctly identified by USG and were also confirmed by a saline jet providing us with a real-time analysis and confirmation of central line tips. El-Maadawy et al.

analyzed 23 (30.7%) central line tips as optimally placed by both X-ray and USG (13). Whereas X-ray identified 52 (69.3%) as incorrectly placed but USG identified only 51 (68 %) as incorrectly placed 31. Thus in their study, USG could not identify the central line tip in one case due to the oblique positioning of the baby for ventilation-related pneumothorax. Thakur et al. found that USG was able to identify central line tips in ninety-five percent (n=62) but in our study USG identified central line tips in all 51 cases; i.e., hundred percent of the cases. The most common malposition site in our study was intrahepatic IVC whereas in the study by El- Maadawy et al., it was the right atrium (13).

Mean ( $\pm$ SD) time taken for central line tip identification (in minutes) by X-ray was 3.96 ( $\pm$ 1.85) (95% CI - 3.44 to 4.48) and median (IQR) time taken for central line tip identification by X-ray was 4 ( $\pm$ 2). The mean ( $\pm$ SD) time taken for central line tip identification by USG was 1.28 ( $\pm$ 2.54) (95% CI - 1.46 - 2.89) and the median (IQR) time taken for central line tip identification by USG was 2 ( $\pm$ 1). Thus, the above findings reveal that the time required for the identification of the central line tip position by POCU is less than that for an X-ray.

Analyzing the accuracy parameters for diagnostic tests, our study found that USG has a sensitivity of 94.7 %, specificity of 76.9 %, PPV of 92.3 %, and NPV of 83.3 %. Telang et al. revealed almost a similar sensitivity of 96.5 % but the specificity in their findings was 100 %, PPV and NPV of 100 % and seventy-five percent respectively for USG in identifying central line tip position 30. El- Maadawy et al. revealed an almost similar sensitivity of 91.3 %, but their specificity was higher compared to that in our study which was 94.2 %; NPV and PPV were 87.5 % and 96.1%, respectively (13).

In our study, we found that the most common complication was hypothermia occurring during X-ray [n (%) = 10 (90.9%)], but post USG-related complications were nil. The Hypothermia related to X-ray is due to removing the temperature sensor probe and also moving the head unit of the radiant warmer away from the baby.

Strengths of our study include good sample size and inclusion of procedure timing and complications. Limitations were the use of only two PICC lines.

## 5- CONCLUSION

Our study results show that Point Of Care Ultrasound is a safer, more efficacious, and quick bedside diagnostic test compared to the conventional radiography in detecting central line tip position in neonates, helping pediatricians to quickly confirm the central line tip position before starting infusions. This paves the way for better neonatal healthcare by reducing radiation exposure, timely detection of malposition, and avoiding malposition-related complications at its earliest.

## 6- REFERENCES

1. Thakur A, Kumar V, Modi M, Kler N, Garg P. Use of Point of Care Ultrasound for Confirming Central Line Tip Position in Neonates. *Indian Pediatrics*. 2020 Sep; 57:805-7.
2. Oppenheimer DA, Carroll BA, Garth KE, Parker BR. Sonographic localization of neonatal umbilical catheters. *American Journal of Roentgenology*. 1982 Jun 1; 138(6):1025-32.
3. Simanovsky N, Ofek-Shlomai N, Rozovsky K, Ergaz-Shaltiel Z, Hiller N, Bar-Oz B. Umbilical venous catheter position: evaluation by ultrasound. *European radiology*. 2011 Sep; 21:1882-6.
4. Greenberg M, Movahed H, Peterson B, Bejar R. Placement of umbilical venous

catheters with use of bedside real-time ultrasonography. *The Journal of pediatrics*. 1995 Apr 1; 126(4):633-5.

5. Ohki Y, Tabata M, Kuwashima M, Takeuchi H, Nako Y, Morikawa A. Ultrasonographic detection of very thin percutaneous central venous catheter in neonates. *Acta paediatrica*. 2000 Nov; 89(11):1381-4.

6. Madar RJ, Deshpande SA. Reappraisal of ultrasound imaging of neonatal intravascular catheters. *Archives of Disease in Childhood-Fetal and Neonatal Edition*. 1996 Jul 1; 75(1):62-4.

7. Lim-Dunham JE, Vade A, Capitano HN, Muraskas J. Characteristic sonographic findings of hepatic erosion by umbilical vein catheters. *J Ultrasound Med* 2007; 26:661-6.

8. Lam HS, Li AM, Chu WC, Yeung CK, Fok TF, Ng PC. Mal-positioned umbilical venous catheter causing liver abscess in a preterm infant. *Biol Neonate* 2005; 88:54-6.

9. Goh SS, Kan SY, Bharadwaj S, Poon WB. A review of umbilical venous

catheter-related complications at a tertiary neonatal unit in Singapore. *Singapore medical journal*. 2021 Jan; 62(1):29.

10. Khaladkar SM, Gujarathi A, Kulkarni VM, Singh A. Hepatic necrosis due to the umbilical vein catheter malposition: A case report with review of literature. *Medical Journal of Dr. DY Patil University*. 2014 Nov 1; 7(6):793.

11. Telang N, Sharma D, Pratap OT, Kandraju H, Murki S. Use of real-time ultrasound for locating tip position in neonates undergoing peripherally inserted central catheter insertion: a pilot study. *The Indian journal of medical research*. 2017 Mar; 145(3):373.

12. Shukla H, Ferrara A. Rapid estimation of insertional length of umbilical catheters in newborns. *Am J Dis Child*. 1986; 140:786-8.

13. El-Maadawy SM, El-Atawi KM, Elhalik MS. Role of bedside ultrasound in determining the position of umbilical venous catheters. *Journal of Clinical Neonatology*. 2015 Jul 1; 4(3):173.