

Caustic Cleaning Agent ingestion: a Case Presentation and Review of the Literature

Marjan Kouhnavard¹, Mehri Najafi², * Maliheh Kadivar³

¹ Assistant Professor, Department of Pediatrics, School of Medicine, Urmia University of Medical Sciences, Urmia, Iran.

² Professor, Division of Pediatric Gastroenterology, Department of Pediatrics, Children's Medical Center, School of Medicine, Tehran University of Medical Sciences, Tehran, Iran.

³ Professor, Division of Neonatology, Department of Pediatrics, Children's Medical Center, Tehran University of Medical Sciences, Tehran, Iran.

Abstract

Background: Caustic ingestion in the pediatric population usually occurs accidentally in children under five years due to insufficient care or negligent household depositing of caustic substances. Neglectful behavior of parents while preparing formula for a neonate can lead to this rare condition in newborns.

Case Presentation: We are reporting the case of a four-day-old newborn that was accidentally given house cleaning liquid mixed with formula by his mother, who mistook it for water to dilute the milk. This led to the development of extensive oral and esophageal lesions.

Conclusion: This report highlights the importance of providing education for parents on how to prevent such accidents and avoid neglectful behaviors while caring for their children.

Key Words: Caustics; Child Neglect; Newborn.

* Please cite this article as: Kouhnavard M, Najafi M, Kadivar M. Caustic Cleaning Agent ingestion: a Case Presentation and Review of the Literature. Int J Pediatr 2023; 11 (10):18348-18354. DOI: [10.22038/ijp.2023.74600.5362](https://doi.org/10.22038/ijp.2023.74600.5362)

*Corresponding Author:

Maliheh Kadivar, Professor, Division of Neonatology, Department of Pediatrics, Children's Medical Center, Tehran University of Medical Sciences, Tehran, Iran. Email: kadivarm@tums.ac.ir

Received date: Sep.01,2023; Accepted date: Oct.21,2023

1- INTRODUCTION

Corrosive ingestion by children is one of the serious public health problems throughout the world (1). Every year in the US, more than 100,000 children suffer from corrosive burns in their esophagus (2). In the developing world, similarly, the rate of alimentary canal burns due to caustic substances is increasing; they are usually caused by defective prophylaxis as well as social, economic, and educational factors (3, 4). Ingestion of caustic substances can cause different complications due to tissue and organ damages (5).

The majority of pediatric injuries caused by accidental ingestion occur in or near the home (6). The group at higher risks for accidental caustic substance intake includes toddlers younger than five (7). In neonates, however, caustic ingestion is

quite rare and is mostly caused by erroneous practices or neglectful behaviors of parents (5). There is limited information in the literature regarding corrosive injuries during the neonatal period.

Hereby, we are reporting the case of a four-day male newborn with the ingestion of a house cleaning agent, accidentally given by his mother who made the formula by mistake using the liquid kept in the bottle of mineral water. The case report is drafted according to case-reporting guidelines (9).

2- CASE PRESENTATION

A four-day term neonate was brought to the emergency department of Children's Medical Center affiliated to Tehran University of Medical Sciences, in Tehran, Iran, because of intractable irritability and several episodes of cyanosis a few hours prior to the presentation (**Fig. 1**).

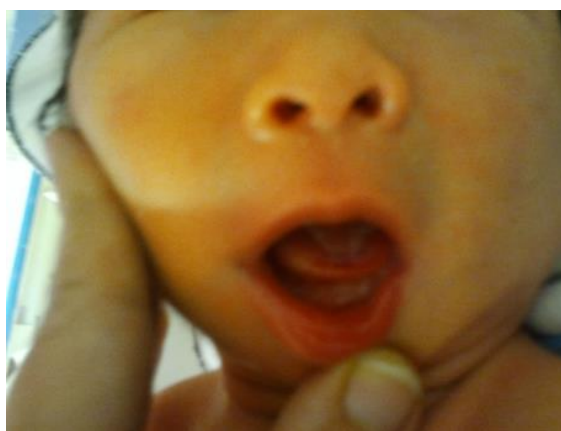


Fig. 1: Bullous lesions in the oral cavity with erythematous mucosa in the infant's mouth

His mother expressed that the baby started crying after his last feeding with formula and it was difficult to calm him down. His cries were also followed by several episodes of cyanosis which lasted for two to three 3 minutes. As his irritability continued, the mother noticed erythematous lesions in his mouth, and when checked the formula, she realized that she had accidentally made the formula using a liquid from the mineral water

bottle supposed to be water; but surprisingly it was diluted household detergent alkaline based multipurpose cleaning agent with brand name of Domestos NaOCl (containing sodium hypochlorite) and NaOH (sodium hydroxide).

2-1. Birth History

He was a term neonate born with the birth weight of 3300 grams through vaginal

delivery with appropriate Apgar scores at 40 weeks of gestational age. The mother was a 17-year-old lady with no medical problems throughout the pregnancy as well as the labor.

2-2. Physical Examination:

On physical examination, he was an ill appearing irritable neonate, with several bullous lesions in the oral cavity along with erythematous mucosa in his mouth (**Fig. 1**). His vital signs on admission were as follows: HR: 150/min, RR: 55/min, Axillary Temperature: 37.2 °C. The neonatal reflexes including Moro and Grasp were normal except for the sucking reflex which was slightly decreased. On his chest auscultation, lung sounds were clear but a holosystolic murmur with the severity of 3/6 was heard prominently at the left sternal border. The rest of the physical examinations were normal.

2-3. Management

The neonate was hospitalized at NICU. The patient was supposed not to be fed by mouth until the upper gastrointestinal endoscopy was done. The emergent

pediatric gastrointestinal consultation was considered after initial stabilization. Therefore, he became NPO (Nothing by Mouth), and underwent intravenous fluid therapy with antibiotics (ampicillin and amikacin). Primary laboratory tests including complete blood count and biochemistry evaluations as well as chest x-ray were requested. Fentanyl (0.5 micgr/kg/hr IV (intravenous) infusion by close monitoring of vital signs, and irritability of the patient) and Ranitidine (1.5 mg/kg/Q8h slow IV infusion initially continued by 0.2 mg/kg PO (per os, orally) Q8h after discharge) were also administered to reduce his irritability and gastric irritation, respectively.

The initial laboratory tests showed no abnormal results. The chest x-ray revealed some reticular infiltrations in the right lung. He underwent emergent endoscopy which revealed grade 2 A and B injuries in the proximal and distal parts of esophagus respectively (8). Due to the severity of the lesions, endoscope was not proceeded to gastroesophageal junction and more distal parts (**Fig. 2**).

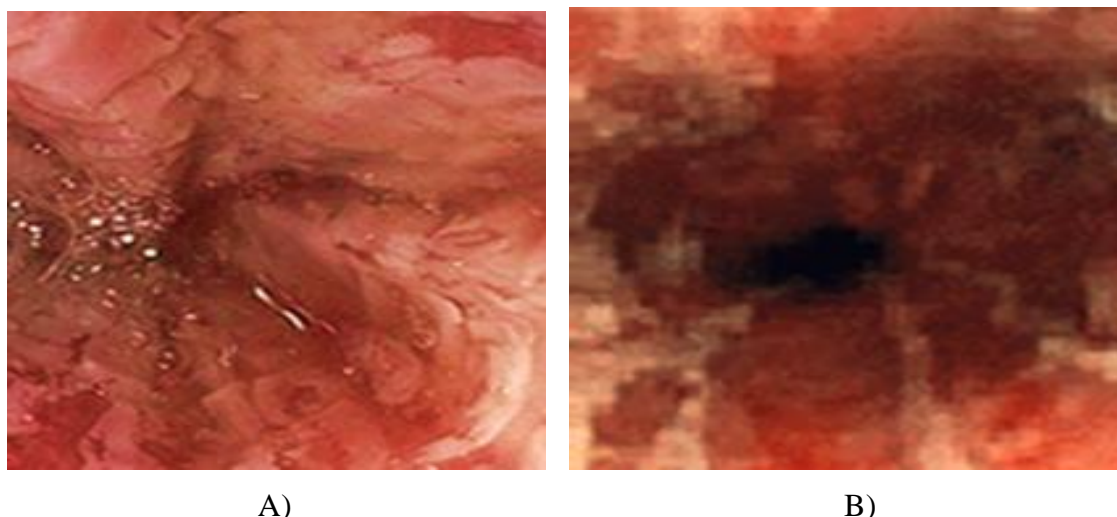


Fig. 2: The emergent endoscopy had revealed A) grade 2A with erythema, erosion and superficial injury accompanied with hemorrhage, and B) grade 2B with circumferential involvement in the proximal and distal parts of esophagus respectively.

After the pediatric cardiology consultation, the echocardiography revealed small VSD (Ventricular Septal Defect) and PFO (Patent Foramen Ovale), and mild TR (Tricuspid Regurgitation) along with mild pulmonary hypertension that needed no interventions at this stage. The pediatric cardiologist recommended referring to the follow-up clinic for further evaluations, believing that most probably the problem will be resolved.

2-4. Case Progress

The neonate was kept NPO for a total duration of four days, and then was gradually breastfed. As the neonate tolerated the feeding, the intravenous fluids gradually decreased. On the seventh day, all antibiotics and the fentanyl drip were stopped. The neonate was then transferred to the neonatal ward and was finally discharged on the eighth day of admission with syrup of ranitidine; and regular visits to pediatric, cardiology, gastroenterology, and neonatal clinics were recommended. The infant was followed by the pediatric cardiologist, and the echocardiography revealed normal pulmonary blood pressure and further follow-up had been recommended only after infancy. This baby had also visited the pediatric gastroenterology clinic which requested barium swallow at the second month of age, hoping that it will not reveal stricture. This infant had one other follow-up visit with appropriate growth and development at three months of age.

3- DISCUSSION

Intake of substances highly alkali or acidic can lead to high morbidity and mortality (10), and children younger than five years old consist the majority of these cases (2). In newborns, however, it occurs infrequently compared to the other pediatric age groups (5).

There are only a few case reports on caustic substance ingestion in neonates. Abdulkadir et al. reported a newborn with

unintentional sulphonic acid ingestion a few hours after birth. The acidic substance was confused with holy water, Ruwan Zam Zam and had been given to the baby by his grandmother who had taken him home to be bathed (11). Kushiro et al., in Lagos, also, documented acid ingestion by a neonate 48 hours after birth. (12) In Turkey, in a review of ten years, esophagus corrosive injuries involving eight newborns due to benzalkonium chloride and trichloroacetic acid ingestion was documented (13). Rather similar to our case, Hassan et al. have lately recorded a case of a corrosive substance ingestion in a four-day-old newborn who was given a liquid bleach mixed with formula milk by mother considering the liquid bleach as water for the dilution of milk which led to gastric perforation (14).

There are various types of corrosive agents in different countries. The two major substances are alkali and acids which consist of the main groups, and the latter is very rare (11). In Sierra Leone, a review of data about children's corrosive ingestion demonstrated that the most common ingested corrosive substance was caustic soda, while kerosene, sodium hypochlorite, and other alkaline household chemicals were the next most common ones (15). A study by Dehghani et al. on caustic intake in children living in South of Iran demonstrated that most caustic ingestions cases were in the kitchen and male children were most commonly inflicted (16).

Detergents (bleaching substances or disinfectants) ingestion or aspiration can cause serious pulmonary and gastrointestinal damages (5). Caustic ingestion in children can lead to different clinical manifestations ranging from no injury to death. There is strong evidence that the clinical presentations of caustic ingestion damages cannot sufficiently reflect of the magnitude of injury to the esophagus (2).

The extent and severity of the caustic esophagus injury is dependent on the interplay of four factors: the corrosiveness of the substance ingested, its amount and concentration, the contact duration, and potential subsequent secondary infection. Additionally, alkaline agents cause liquefaction necrosis in the esophagus facilitating more in-depth penetration which can intensify injuries compared to acidic ingestions (2).

The presented newborn in this case report had ingested a house cleaning agent mostly consisting of sodium hydroxide, which is an alkaline substance. Lye (sodium hydroxide) in domestic cleaner liquids caused significant problems in terms of caustic injuries after the turn of the 19th century. Sodium hydroxide ingestion is responsible for about a third of esophageal strictures. Depending on its concentration, strictures were found in 10% to 75% of children who had ingested this corrosive (10).

Severe chemical burns in the esophagus of children who ingested caustic agents with pH lower than two or greater than 12 are reported (11). Thus, solid substances usually cause a localized burn whereas liquid ones lead to more extensive injury patterns (17). In our patient, pH of the ingested liquid was 12, leading to an extensive injury to the mouth and the esophagus of the newborn.

Clinical management of ingestion of caustic agents includes steroids, antibiotic agents, and H₂-blocker medications. Antibiotics significantly reduce the risk of stricture. There are different opinions on the administration of steroids in caustic esophagitis (17). Vomiting induction, gastric lavage and the use of active Cole are discouraged because they can expand the injury. For diagnosis and treatment, it is recommended that a prompt gastroscopy within the first 24 to 48 hours should be performed. However, if related lesions are detected, as they were in our case, the

procedure should be halted immediately with no advancement to the distal part (5).

In our patient, the medical intervention was administration of intravenous fluid, initiation of total parenteral nutrition, H₂ - blocker, and an intravenous antibiotic therapy for almost seven days. Findings in the gastroscopy which was conducted on the second admission day, were concordant with grade 2A and B of caustic esophageal injury (8). As the larynx and pharynx diameters in neonates are lower compared to those of the children and their mucosa is more permeable, higher mortalities are reported in newborns (13).

In addition to health consequences, ingestion of caustic substances imposes an economic burden for diagnosis, management, and follow up care. Stricture of the esophageal is considered as a short-term complication, and long-term effects of caustic ingestion include esophagus perforation, obstruction, and malignancy (1). Although the caustic agents' ingestion can be prevented, it is still one of the major public health issues in the developing countries (3).

Based on the literature, most caustic injuries accidentally occur in neonates due to erroneous practice of parents or child care givers. Male sex, attention deficit hyperactivity disorder, uneducated parents, young maternal age, deficient parental supervision and rural residence are the main risk factors for childhood caustic ingestion (10). Besides the mentioned risk factors, whether caustic substance ingestion especially in neonatal period can be considered as a result of neglectful behavior of parents or not, is controversial.

The most commonly reported type of child abuse is child neglect which is characterized by a failure in providing a child's basic needs. These needs include proper healthcare, supervision, nutrition, clothing, housing and provision of physical, social,

emotional, safety, and educational needs (18).

Based on this definition, and considering the fact that giving caustic agents to neonates by their parents or other caregivers even accidentally might lead to life-threatening complications, it can be concluded that caustic ingestion can be considered as an instance of child neglect.

The most common presentation of child maltreatment is child neglect, constituting 79.5% of the affected children that leads to 80% of U.S. child welfare deaths. These children face different social, emotional, and language development defects. The high rates and negative consequences necessitate prompt implementation and monitoring interventions (19).

According to a review by Dogan et al. in Turkey, corrosive agents were accidentally administered by mothers, in 43 out of 473 patients with caustic ingestion (2), highlighting the fact that neglectful behavior of parents might be a cause and would lead to devastating outcomes. Storing poisonous substances in cold drink containers is frequently reported as the cause of childhood caustic ingestion, considering that these solutions are usually odorless and colorless; and resemble water.

4- CONCLUSION

Programs raising Public Health awareness can significantly decrease the incidence of caustic-related damages that are more common in developing countries (10). Parental education using multimedia has been shown effective in awareness raising and self-efficacy in child care (1). Recently, Mahmoudvand Z. et al. have developed a minimum data set for corrosive substance ingestion in Iran which can facilitate epidemiological studies and assist health policymakers in better establishment of preventive strategies in this regard (20).

However, neglectful behavior of parents should always be kept in mind while facing a case of caustic ingestion in the pediatric age group which might necessitate further family support and specific educational programs.

5- ETHICAL CONSIDERATION

This manuscript was prepared with the approval of the local ethics committee and in compliance with the declaration of Helsinki. Informed consent of the parents was also obtained prior to submission.

6- CONFLICT OF INTEREST

None.

7- ACKNOWLEDGMENT

The authors of this article would like to offer special thanks to the staff of the NICU of Children's Medical Center as well as Dr. Shahrokh Mehrpisheh and Dr. Azadeh Memarian for their kind help. We also thank Dr. Shiva Mohamadi, pediatric gastro tourism, for reviewing the manuscript and her comments, and Dr. Mohammad Taghi Majnoon, pediatric cardiologist, for his evaluation of the patient and his comments on cardiac issues. Moreover, we are grateful to thank the family of this newborn for their cooperation.

8- REFERENCES

1. Rafeey M, Ghojazadeh M, Sheikhi S, Vahedi L. Caustic ingestion in children: a systematic review and meta-analysis. *Journal of caring sciences*. 2016; 5(3):251.
2. Doğan Y, Erkan T, Çokuğraş FÇ, Kutlu T. Caustic gastroesophageal lesions in childhood: an analysis of 473 cases. *Clinical pediatrics*. 2006; 45(5):435-8.
3. Ekpe E, Ette V. Morbidity and mortality of caustic ingestion in rural children: experience in a new cardiothoracic surgery unit in Nigeria. *International Scholarly Research Notices*. 2012; 2012.

4. Niedzielski A, Schwartz SG, Partycka-Pietrzyk K, Mielnik-Niedzielska G. Caustic agent's ingestion in children: a 51-year retrospective cohort study. *Ear, Nose & Throat Journal*. 2020; 99(1):52-7.
5. Civan HA, Gulcu D, Erkan T. Corrosive esophagitis with benzalkonium chloride in a two days old neonate. *Pediatric Gastroenterology, Hepatology & Nutrition*. 2016; 19(3):207-9.
6. Sánchez-Ramírez CA, Larrosa-Haro A, Vásquez-Garibay EM, Macías-Rosales R. Socio-demographic factors associated with caustic substance ingestion in children and adolescents. *International journal of pediatric otorhinolaryngology*. 2012; 76(2):253-6.
7. Erdoğan E, Eroğlu E, Tekant G, Yeker Y, Emir H, Sarimurat N, Yeker D. Management of esophagogastric corrosive injuries in children. *European journal of pediatric surgery*. 2003; 13(05):289-93.
8. Kleinman RE GO, Mieli Vergani G, Sanderson IR, Sherman P. Walker's *Pediatric Gastrointestinal disease*. 6th ed 2018. p. 159.
9. Gagnier JJ, Kienle G, Altman DG, Moher D, Sox H, Riley D. The CARE Guidelines: Consensus-based Clinical Case Reporting Guideline Development. *Global advances in health and medicine*. 2013; 2(5):38-43.
10. Arnold M, Numanoglu A, editors. *Caustic ingestion in children—a review*. *Seminars in pediatric surgery*; 2017: Elsevier.
11. Abdulkadir I, Hassan L, Abdullahi F, Akeredolu F, Purdue S, Okpe M, Sobowale AM, Adewumi OA, Abdullahi U, Onadiran MA, Sholadoye TT, Baba S, Ogala WN. Accidental sulphuric acid poisoning in a newborn. *Nigerian Journal of Paediatrics*. 2015; 42(3):237-40.
12. Kushimo T, Ekanem M. Acid ingestion in a 2-day old baby. *West African journal of medicine*. 1997; 16(2):121-3.
13. Turan C, Özkan U, Özokutan BH, Özdemir M, Okur H, Küçükaydın M. Corrosive injuries of the esophagus in newborns. *Pediatric surgery international*. 2000; 16:483-4.
14. Hassan A, Munir A, Naumeri F, Qayyum B, Sharif M. Corrosive ingestion in a 4 days old newborn. *Journal of Pediatric and Adolescent Surgery*. 2021; 2(1):39-40.
15. Contini S, Swarray-Deen A, Scarpignato C. Oesophageal corrosive injuries in children: a forgotten social and health challenge in developing countries. *Bulletin of the World Health Organization*. 2009; 87:950-4.
16. Dehghani SM, Bahmanyar M, Javaherizadeh H. Caustic ingestion in children in south of Iran: a two-year single center study. *Middle East journal of digestive diseases*. 2018; 10(1):31.
17. De Jong A, Macdonald R, Ein S, Forte V, Turner A. Corrosive esophagitis in children: a 30-year review. *International journal of pediatric otorhinolaryngology*. 2001; 57(3):203-11.
18. Bovarnick S. *Child neglect (Child protection research briefing)*. London: National Society for the Prevention of Cruelty to Children. 2007.
19. Green AE, Trott E, Willging CE, Finn NK, Ehrhart MG, Aarons GA. The role of collaborations in sustaining an evidence-based intervention to reduce child neglect. *Child Abuse & Neglect*. 2016; 53:4-16.
20. Mahmoudvand Z, Shanbehzadeh M, Shafiee M, Kazemi-Arpanahi H. Developing the minimum data set of the corrosive ingestion registry system in Iran. *BMC health services research*. 2022; 22(1):1-13.