

## Dilemma of Retained Intraorbital Fragment of Pencil

Mohammad Yaser Kiarudi<sup>1</sup>, Aliakbar Sabermoghadam<sup>2</sup>, Mahsa Sardabi<sup>3</sup>, \* Seyyed Hossein Ghavami<sup>4</sup>

<sup>1</sup> Assistant professor of ophthalmology, Eye Research Center, Mashhad University of Medical Sciences, Mashhad, Iran

<sup>2</sup> Associate professor of Ophthalmology, Eye Research Center, Mashhad University of Medical Sciences, Mashhad, Iran.

<sup>3</sup> Resident of radiology, Mashhad University of Medical Sciences, Mashhad, Iran.

<sup>4</sup> Eye Research Center, Mashhad University of Medical Sciences, Mashhad, Iran.

### Abstract

Juvenile injuries by intraorbital foreign body in extremities are common and usually trivial (1) but they may lead to debilitating sequels in the head and neck. Because of their availability in comparison to other sources of trauma, accidental injuries may occur while children play with their friends. Injuries by pencils are special types of intraorbital foreign body, the final outcome of which is dependent to concurrent injuries of the ocular and also neurologic structure and comorbidity. Orbital injury requires comprehensive evaluation, especially in child victims when there is not sufficient information regarding trauma mechanism and the intraorbital foreign body should be ruled out before any closure of wounds, as shown in the sample case presented here. In school age children with a history of falling, intraorbital fragments of pencils should be kept in mind. Preoperative information about the true number and exact location of retained fragments is paramount for an appropriate management. When there is high suspicion for retained foreign body, further detailed studies with CT and if needed MR scans and in selected cases plain X-ray are very helpful.

**Key Words:** CT-Scan, Foreign Body, Graphite, Juvenile injuries, Orbit, Pencil, Trauma.

\* Please cite this article as: Kiarudi MY, Sabermoghadam A, Sardabi M, Ghavami SH. Dilemma of Retained Intraorbital Fragment of Pencil. Int J Pediatr 2022; 10(9):16758-16765. DOI: 10.22038/ijp.2022.63984.4860

---

### \*Corresponding Author:

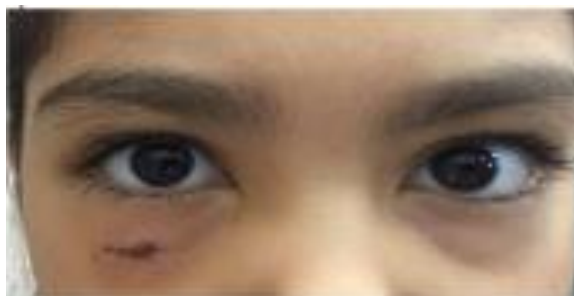Seyyed Hossein Ghavami, Eye Research Center, Mashhad University of Medical Sciences, Mashhad, Iran.  
Email: sh.ghavami@yahoo.com

Received date: Feb.23,2022; Accepted date:Aug.25,2022

*Dear Sir,*

Here, we describe the case of a child presented with lower lid laceration and a vague history of trauma at school. At presentation, the patient was conscious and

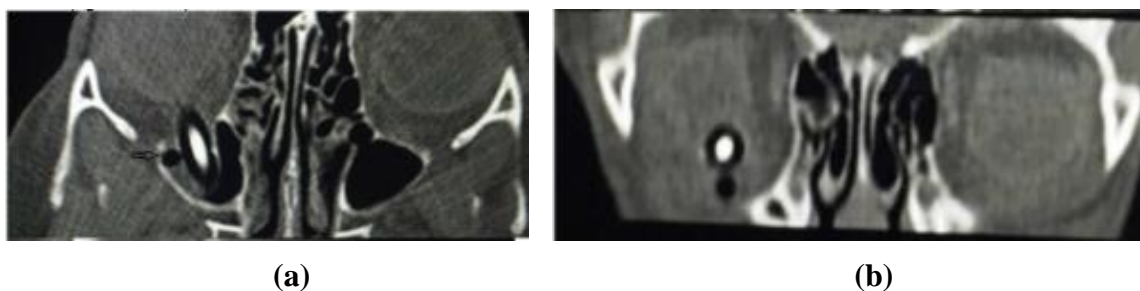
oriented, but frightened and not cooperative for history taking. In external eye exams, there was right lower lid laceration and hyper Globus of the right eye (**Fig. 1**).



**Fig. 1:** shows the lower lid laceration and hyperglobus of the right eye

The exact evaluation of extra-ocular movements was not possible but grossly, there was limitation of infraduction. Relative afferent pupillary defect was negative. In slit-lamp examination, a round laceration in the right lower lid was seen. The anterior segment and posterior pole of

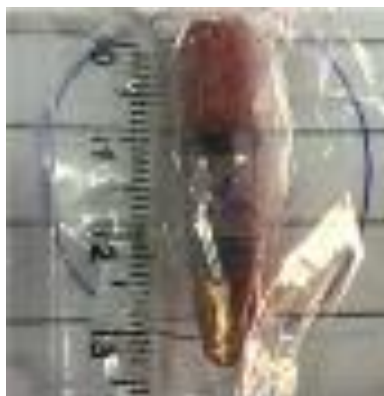fundus seemed intact. Computed Tomography (CT) was performed and revealed a linear intraorbital foreign body. It had a central hyperdense core with surrounding hypodense material (**Fig. 2a** and **2b**).



**Fig. 2:** axial and coronal CT images show a linear intraorbital foreign body, central hyperdensity surrounded by hypodensity extending to the posterior of the right orbit. The arrow shows an air bubble.

These features were compatible with graphite pencil with an approximate length of 3 cm. It was extended from inferior of the right orbit to the posterior and pierced the roof of the maxillary sinus. The patient was admitted and proper antibiotics were administered and planned for removal of the foreign body under general anesthesia.

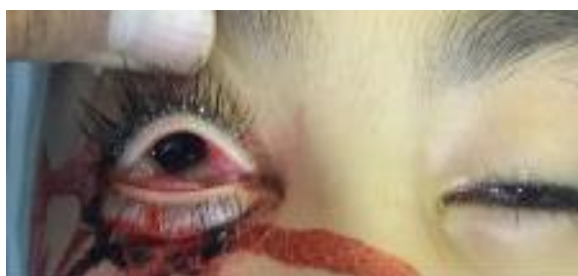The laceration in the lower eyelid was explored with minimally extending the entrance wound. The proximal end of the foreign body became visible. The pencil was then grasped forcefully and with fine twisting movements was brought out totally (**Fig 3**).



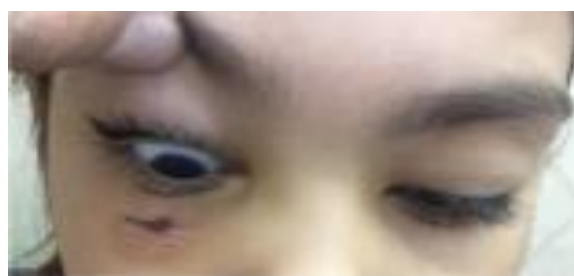**Fig. 3:** The extracted pencil measuring 3 cm

No orbital hemorrhage occurred after removal of the pencil. Indirect ophthalmoscopy was done and periphery of the retina was intact. Forced duction test was normal. The entrance wound was repaired in a routine manner. After surgery, systemic antibiotics were continued for two days and then the patient

discharged with topical and systemic antibiotics. At the patient's 2-week follow-up, she showed a distance visual acuity of 20/20 in both eyes with resolution of all eyelid edema and continued full extra ocular motility without any sequel from the orbital foreign body (**Fig. 4 and 5**).



**(a)**



**(b)**

**Fig. 5:** Two weeks post-operatively, the right eye looks normal in the primary position. Patient has recovered normal infraduction.

Two weeks after the operation, the right eye looked normal in the primary position. The patient had recovered normal infraduction.

In the literature, we found 13 relevant studies describing 42 individuals with intraorbital pencil (from 1990 up to date). We excluded papers with wooden stick materials which were not pencils in origin. **Table 1** shows age, sex, side of trauma, presenting signs and symptoms, radiologic appearance, comorbidities, presentation

time after injury and final outcome of patients.

Juvenile injuries by pencils in extremities are common and usually trivial (1) but they may lead to debilitating sequels in the head and neck. Because of their availability in comparison to other sources of trauma, accidental injuries may occur while children play with their friends. There may be a history of falling on the ground (9, 10). Review of **Table 1** shows that many victims are children even as young as 14 months (14).

**Table-1:** Clinical, imaging, comorbidity, radiologic and final outcome of patients with intraorbital pencil fragment from 1990 up to date

Author (year, no. of cases)	Sex/Age (years)	Symptoms/signs	Radiologic feature	Outcome	Comorbidity	Presentation time after injury	Side
Gates & Hardjasudarma (1993, 1) (2)	M/22	Puncture wound at the lateral can thus, Rapid decrease of VA to NLP, limitation of EOM movements. Sharp pain	CT: hypodense foreign body containing hyperdense center, with extension into the optic canal	partial third nerve palsy and NLP	complete third nerve palsy	N.A	R
Herman et al (1995, 2) (3)	M/11	eyelid erythema and conjunctival chemosis, primarily treated as conjunctivitis	well-defined lytic lesion of the superior orbit with a well-defined opacity at its center	Good recovery of the ptosis and proptosis	Proptosis and ptosis	6 years	R
	F/3	Periorbital edema, proptosis, upper eyelid ptosis, hypotropia	CT: Sclerotic, poorly defined lateral orbital rim and a mass in the region of the lacrimal gland and a well-defined opacity adjacent to The zytomatic bone.	Complete resolution of the proptosis, ptosis and hypotropia.	Palpable mass mimicking orbital tumor	One week after injury	L
Elgin et al (2007, 1) (4)	M/3	Upper lid laceration	N.A	Good recovery	none	N.A	R
Al-Mujaini et al (2008, 1) (5)	M/9	Reduced VA to LP, lid edema (lower lid more than upper), No entrance wound	hyperdense foreign body(pencil tip) embedded in the lateral 1/3 of the preseptal compartment of the lower lid	Secondary hypotony with a vision of NLP	endophthalmitis	Four days	R
Ozer et al (2010, 1) (6)	M/4	Apparent piece of pencil with infraorbital swelling and ecchymosis	Hypodense object with a high- intensity core to penetrating through the anterior maxillary sinus wall, medial orbital wall, reaching the gyrus rectus. Vital structures were normal	Good recovery without ocular & neurologic deficit	gyrus rectus injury, bony defect at the cribrifom plate	N.A	R
Shelsta et al (2010, 9) (7)	N.A	N.A	CT: radiodense core containing graphite and pigment, surrounded by radiolucent wood and a thin rim of paint	N.A	N.A	N.A	N.A
Fisher et al (2011, 9) (8)	N.A	N.A	N.A	Expiration of one patient from brain injury	N.A	N.A	N.A
Al-Otaibi & Baeesa (2012, 1) (9)	F/4	Orbital cellulitis following a fall on face at school	Hypodense object with a high- intensity core traversing the medial roof of the right orbit into the inferior frontal lobe with fluid collection	No neurologic deficit, mild ptosis without EOM movement limitation	subfrontl abscess, subdural empyema	Three days after injury	R

Ahmad et al (2012, 1) (10)	F/5	Sudden onset of upper eyelid swelling, chemosis and	long, linear orbital foreign body extending	N.A	firm, palpable mass	Within a few hours	L
	-	congestion, small eyelid laceration, after falling, limited EOM motility	from the left orbit through the medial part of the temporal lobe up to the brain stem	-	-	-	-
Choudhri et al (2013, 1) (11)	13/M	Eyelid ecchymosis and edema, pain on leftward gaze, no entry wound, hemorrhagic conjunctival chemosis	MRI: A susceptibility halo around the foreign body in the orbit (pencil tip) CT: a cylindrical- to-conical shaped high density foreign body, X-ray: no evidence of metallic particle	VA 20/40 with complete resolution of all eyelid edema And EOM motility	N.A	N.A	R
Tas & Top (2014, 10) (12)	N.A	VA :20/20 to 20/40	N.A	N.A	N.A	N.A	N.A
Torabi&Tabatabai (2016, 1) (13)	F/3	Apparent piece of pencil perforating medial can thus, ocular motility limitation, history of falling	Hypodense object with a high-intensity core extending to the orbital cone and superior orbital fissure	Good recovery	none	immediately	L
Cho et al (2017, 4) (14)	M/34	a pencil lodged in the right medial orbit. NLP	CT: linear foreign body	VA: NLP, optic disc pallor, resolution of the ophthalmoplegia and ptosis	Subdural hemorrhage in temporal lobe.	6 hours	R
	M/2	Redness and swelling of the upper eyelid fever and vomiting proptosis	superomedial orbital collection density containing a round-shaped foreign body	full postoperative recovery	brain abscess, seizures	3 weeks	R
	M/14 months	moderate edema erythema and a 1.5 mm red spot in the medial sub-brow area	small radiopaque fragment in the superomedial orbital roof	complete recovery	none	2 days	R
	M/2	persistent erythema and swelling, induration around a healing wound	hyper-dense object in the left superomedial orbit	Full recovery.	none	6 weeks	L
Sabermoghadam et al (2018, 1)	F/7	Lower lid laceration, hyperglobus, limited downgaze	CT: linear Hypodense object with a high-intensity core	Good recovery	none	immediately	R

N.A: not available, EOM: extraocular muscle, NLP: no light perception

A pencil has a central core of lead and surrounding woody cylinder. The modern lead pencil, as the name brings in mind, does not contain metallic lead in it. Rather the lead pencil consists of a mixture of clay particles in conducting graphite matrix (15). For its composition, the central core has high-density signals in CT scan that may mimic metal particle. Choudhri et al. reported a retained foreign body where the graphite core of a pencil resulted in metal-like diamagnetic susceptibility artifact in MRI 10. However, there was no evidence of metallic foreign body in the plain X-ray. Magnetic susceptibility artifact is one of MRI artifacts caused by focal distortion in the main magnetic field resulting from the presence of ferromagnetic objects such as surgical clips and wires; and also metallic foreign bodies (16). In 2 reports in which only pencil tips were embedded in the orbit, high signal particles were observed in CT scan (5, 11). Although it is stated that plain x-ray has no role in the management of intraorbital wooden foreign bodies (7), in this situation, plain X-ray may confirm the non-metallic nature of the foreign body. In our review, we found two special radiologic appearances in long-standing and neglected cases that were reactive osteitis adjacent to a dense fragment and soft tissue mass surrounding the dense graphite core (3).

An intraorbital wooden foreign body is often a challenging radiological issue because its density in CT images varies greatly from hypointensity to hyperintensity (17). There are several factors determining the intensity of wooden materials on CT images such as water content of wood fragments, type, hydration and their size (7). Per analysis, by Javadrashid et al. (17), on dry wood in comparison to green wood exhibited low density in CT images so that it would wrongly be diagnosed as air. In all previous reports of pencil fragment, the

surrounding wood of pencil (dry wood) had shown low density in CT scans (**Table 1**). Cone-Beam Computed Tomography (CBCT) is a fairly new imaging modality that has been very applications in all fields of dental practices. It differs from the CT in a number of fundamental ways (18). The costs of a CBCT scanner and also X-ray exposure to the patient are significantly less than that of a CT scanner. Although at present, CT is the imaging technique of choice for detection of IOFB, for these advantages of CBCT in comparison to spiral CT, and also its superiority to showing hard tissue damages in the vicinity of metal particles, CBCT has been introduced as the method of choice for evaluating patients with ocular trauma and suspected IOFBs (17).

Timely diagnosis of IOFB is of paramount importance and cannot be overemphasized. Although the majority of the subjects refer within a day from the trauma (19), there are patients with delayed diagnosis. The diagnosis is not straightforward in all patients. In our series, even there was not wound entrance in two patients. We found patients with clinical features of conjunctivitis and endophthalmitis. Neglected cases may present after long periods of time because of sustained inflammation of these organic porous particles. We found two cases with primary clinical suspicious of orbital tumors (proptosis) such as rhabdomyosarcoma; and after thorough history taking, the parents remembered ocular trauma 6 years before (3).

The final outcome in this special type of intraorbital foreign body, is dependent to concurrent injuries of the ocular and also neurologic structure and comorbidities. One catastrophic injury resulted in death due to brain damage (8). Other significant neurologic comorbidities we observed in this review were as follows: seizure, hemiparesis, subfrontal abscess, subdural empyema, gyrus rectus injury, the bony

defect at the cribriform plate and third nerve palsy. Regarding devastating ocular outcomes, one case of phthisis bulbi secondary to endophthalmitis and complete visual loss (no light perception) were found.

One of the important issues in orbital organic foreign bodies is protection against infection. The commonly isolated organisms are Staphylococcus and Streptococcus, followed by Diplococcus pneumoniae. With less prevalence are gram negative and anaerobic organisms (9). Fungal organisms are very rare (12). When concomitant cranial penetration is suspected, the recommended empiric antibiotic therapy is a third-generation cephalosporin and vancomycin in high doses (7, 12). Proper antibiotic coverage is recommended to prevent potentially orbital and sometimes intracranial complications. Orbital injury requires comprehensive evaluation, especially in child victims when there is not sufficient information regarding trauma mechanism and an intraorbital foreign body should be ruled out before any closure of wounds. In school age children with a history of falling, intraorbital fragments of pencils should be kept in mind. Preoperative information about the true number and exact location of retained fragments is paramount for an appropriate management. When there is high suspicion for retained foreign body, further detailed studies with CT and if needed MR scans and in selected cases plain X- ray are very helpful.

## REFERENCES

1. Kim YJ, Ahn JY, Kim BJ, Kim MN, Song KY. A Case of Graphite Foreign Body Misdiagnosed as Blue Nevus. *Annals of Dermatology* 2007; 19: 166.
2. Gates TR, Hardjasudarma M. Computed tomography findings of an intraorbital pencil. *The American journal of emergency medicine* 1993; 11: 433-434.
3. Herman T, Shackelford G, Tychsen L. Unrecognized retention of intraorbital graphite pencil fragments: the role of computerized tomography. *Pediatric radiology* 1995; 25: 535-537.
4. Elgin U, Berker N, Nalcacioglu P, Ucan N. Nonsurgical management of an intraorbital pencil without cranial or globe penetration. *Journal of pediatric ophthalmology and strabismus* 2007; 44: 307-308.
5. Al-Mujaini A, Al-Senawi R, Ganesh A, Al-Zuhaibi S, Al-Dhuhli H. Intraorbital foreign body: clinical presentation, radiological appearance and management. *Sultan Qaboos Univ Med J* 2008; 8: 69-74.
6. Ozer S, Onal B, Akbay A, Onerci M. Craniocerebral injury resulting from pencil penetration. *European archives of otorhino-laryngology* 2010; 267: 155-157.
7. Shelsta HN, Bilyk JR, Rubin PA, Penne RB, Carrasco JR. Wooden intraorbital foreign body injuries: clinical characteristics and outcomes of 23 patients. *Ophthalmic Plastic & Reconstructive Surgery* 2010; 26: 238-244.
8. Fisher SB, Clifton MS, Bhatia AM. Pencils and pens: an under-recognized source of penetrating injuries in children. *The American Surgeon* 2011; 77: 1076-1080.
9. Al-Otaibi F, Baesa S. Occult orbitocranial penetrating pencil injury in a child. *Case reports in surgery* 2012; 2012.
10. Ahmad SS, FAEH F, Ghani SA, Peng KS, Sellamuthu P. 5-year-old girl with left upper eyelid swelling. *Digital journal of ophthalmology: DJO/sponsored by Massachusetts Eye and Ear Infirmary* 2012; 18: 15.
11. Choudhri AF, Patel BJ, Phillips ME, Mills KA, Whitehead MT, Fleming JC. Diamagnetic susceptibility artifact associated with graphite foreign body of the orbit. *Ophthalmic Plastic &*

Reconstructive Surgery 2013; 29: e105-e107.

12. aş S, Top H. Intraorbital wooden foreign body: clinical analysis of 32 cases, a 10-year experience. *Ulus Travma Acil Cerrahi Derg* 2014; 20: 51-55.

13. Torabi HR, Tabatabai S-A. Intraorbital Penetrating Pencil Injury in a Child. *Trauma Monthly* 2016.

14. Cho W-K, Ko AC, Eatamadi H, Al-Ali A, Abboud J-P, Kikkawa DO, Korn BS. Orbital and orbitocranial trauma from pencil fragments: role of timely diagnosis and management. *American journal of ophthalmology* 2017; 180: 46-54.

15. Bhowmik R. Ferromagnetism in lead graphite-pencils and magnetic composite with CoFe<sub>2</sub>O<sub>4</sub> particles. *Composites Part B: Engineering* 2012; 43: 503-509.

16. Willam E. Brant CAH. *Fundamentals of diagnostic radiology*. Philadelphia, Lippincott Williams & Wilkins, Wolters Kluwer, 2012.

17. Javadrashid R, Golamian M, Shahrzad M, Hajalioghli P, Shahmorady Z, Fouladi DF, Sadrarhami S, Akhoundzadeh L. Visibility of Different Intraorbital Foreign Bodies Using Plain Radiography, Computed Tomography, Magnetic Resonance Imaging, and Cone-Beam Computed Tomography: An In Vitro Study. *Canadian Association of Radiologists Journal* 2016.

18. Kiarudi AH, Eghbal MJ, Safi Y, Aghdasi MM, Fazlyab M. The applications of cone-beam computed tomography in endodontics: a review of literature. *Iranian endodontic journal* 2014; 10: 16-25.

19. Di Gaeta A, Giurazza F, Capobianco E, Diano A, Muto M. Intraorbital wooden foreign body detected by computed tomography and magnetic resonance imaging. *The neuroradiology journal* 2017; 30: 88-91.