

## Rhabdomyosarcoma Arising within Congenital Cystic Adenomatoid Malformation; a Case Report

\* Farinaz Amirikar<sup>1</sup>, Nemat Bilan<sup>2</sup>, Azim Rezamand<sup>3</sup>, Masoud Jamshidi<sup>4</sup>, Zahra Golchinfar<sup>5</sup>

<sup>1</sup> Assistant professor, Pediatric Health Research Center, Tabriz University of Medical Sciences, Tabriz, Iran.

<sup>2</sup> Professor, Pediatric Health Research Center, Tabriz University of Medical Sciences, Tabriz, Iran.

<sup>3</sup> Associated professor, Pediatric Health Research Center, Tabriz University of Medical Sciences, Tabriz, Iran.

<sup>4</sup> Assistant professor, Pediatric Health Research Center, Tabriz University of Medical Sciences, Tabriz, Iran.

<sup>5</sup> Msc, Clinical Research Development Unit of Children Educational and Treatment Center, Tabriz University of Medical Sciences, Tabriz, Iran.

### Abstract

This case report describes a 30-month-old child with primary pulmonary rhabdomyosarcoma with a congenital cystic adenomatoid malformation (CCAM). In the current literature, primary pulmonary neoplasms have been reported for similar cases. The tumor was located in the anterior-basal segment of the left lower lobe with a thin-walled cystic appearance and lobulated margins. A histology examination showed rhabdomyosarcoma origin with an embryonal subtype. Postoperative systemic chemotherapy was carried out. After a 6-month follow-up, the patient had no residual or recurrent disease.

**Key Words:** Children, Congenital cystic adenomatoid malformation, Primary pulmonary rhabdomyosarcoma.

\* Please cite this article as: Amirikar F, Bilan N, Rezamand A, Jamshidi M, Golchinfar Z. Rhabdomyosarcoma Arising within Congenital Cystic Adenomatoid Malformation; a Case Report. Int J Pediatr 2022; 10 (6):16233-16237. DOI: **10.22038/ijp. 2022.64392.4889**

---

### \*Corresponding Author:

Farinaz Amirikar, Assistant professor, Pediatric Health Research Center, Tabriz University of Medical Sciences, Tabriz, Iran. Email: Amirikarfarinaz@gmail.com

Received date: Mar.14,2022; Accepted date:May.22,2022

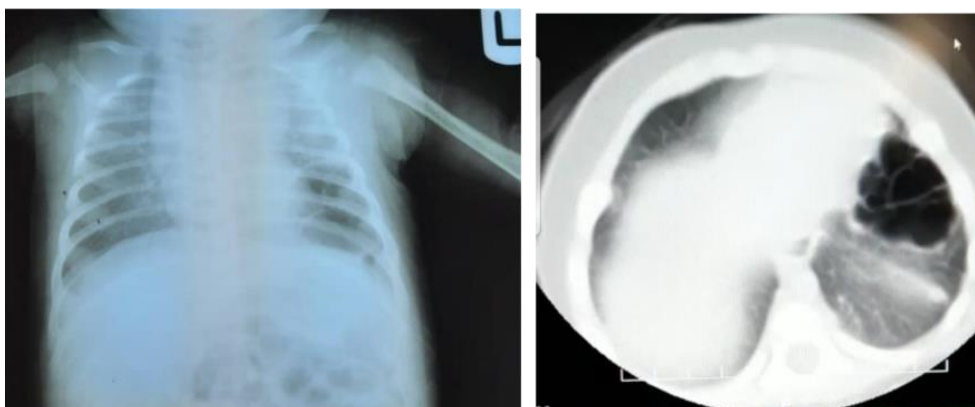
## 1- INTRODUCTION

Primary pulmonary rhabdomyosarcoma (RMS) is a rare neoplasm among primary pulmonary neoplasms, accounting for only 4.4% of childhood pulmonary neoplasms with a prevalence of 0.5% in the world (1). This is a very rare condition and is usually reported as isolated case reports. RMS is the most common soft tissue sarcoma in childhood that its location in the lung is very unusual (2). This tumor is of obscure etiology but has been correlated with congenital pulmonary malformations (3). We report a case of rhabdomyosarcoma arising within congenital cystic adenomatoid malformation in a 2-year-old child.

## 2- CASE PRESENTATION

This case is a 30-month-old child resulting from a twin and term pregnancy. In the perinatal ultrasound evaluation, the probability of a diaphragmatic hernia had been reported for this fetus. The infant was discharged with normal Apgar after birth, and the other twin had a normal clinical examination.

In a 6-month follow-up, lung X-ray and CT scan showed that CPAM was diagnosed for the child according to the cystic appearance (**Fig. 1**). According to the diagnosis, the surgery plan was intended for the patient. Yet, the parent's refusal for surgical operation led to self-satisfy discharge of the patient.



**Fig. 1:** Chest x-ray and CT scan of the patient in the 6-month follow-up after birth

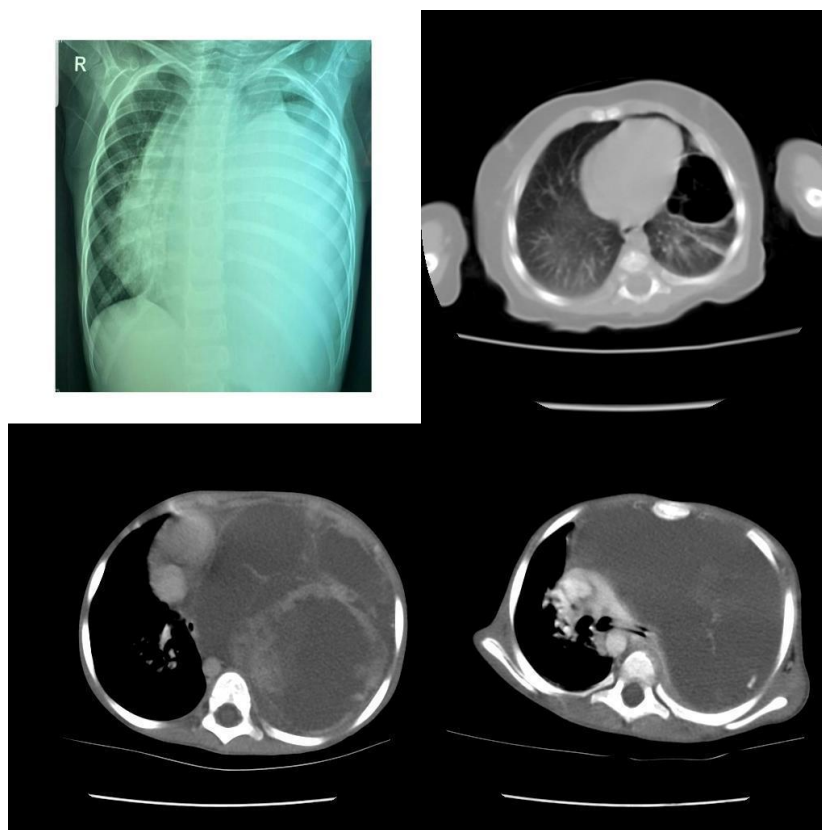
Then, the patient was admitted to our center with symptoms of fever and cough. The lung's chest X-ray and CT scan showed a possible pleural effusion pattern (**Fig. 2**). In CT Scan images, there was a thin-walled cystic lesion with lobulated margins in the anterior-basal segment of the left lower lobe, based on which CPAM type IV or could be diagnosed. Also, large multicystic mass with enhancing septae and some enhanced solid nodules was seen, occupying the left hemithorax, partially sparing the lung apex that causes contra-lateral midline shifting with no bony destruction.

So, for further evaluation and treatment, the child was hospitalized. The patient had no clinical symptoms until one week before admission and had no history of hospitalization.

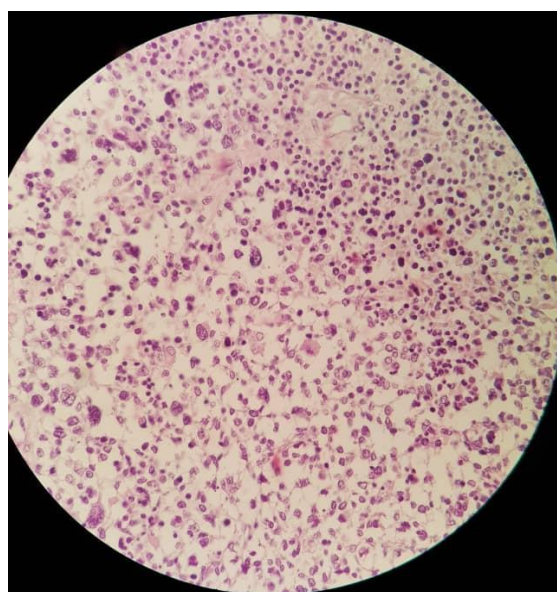
Because of the aggravation of respiratory distress, the patient was admitted to the PICU. The mass was excised because of the relationship between CCAM and Blastoma Pleuropulmonary, especially type IV of CCAM. But, because of the solid component of the tissue, the response rate to treatment was significantly lower. Also, in a pathology study conducted on

tissue excised (**Fig. 3**), rhabdomyosarcoma was diagnosed, which is one of the rare cases within CPAM. In immunohistochemistry evaluations, we observed positive markers of Vimentin, Desmin and MYOD that were in favor of

rhabdomyosarcoma diagnosis. Postoperative systemic chemotherapy was carried out. After a 6-month follow-up, the patient had not any residual or recurrent disease.



**Fig. 2:** Chest x-ray and CT scan of the patient in our center



**Fig. 3:** Pathology evaluation of the mass considering rhabdomyosarcoma

### 3- DISCUSSION

Rhabdomyosarcoma in childhood is the most common soft tissue sarcoma and commonly occurs in the head, neck, head, and urogenital organs. Nevertheless, primary pulmonary neoplasms are unusual in the pediatric age groups; so, RMS of lung tissue is one of the rarest ones. As mentioned, it accounts for only 0.5% of childhood RMS (3). Moreover, this tumor is a primitive mesenchymal tumor with skeletal differentiation and poor prognosis in children (4). As we know from recent evidence, RMS is strongly associated with CCAM, but some authors reported that it might also occur in healthy children. By the way, the etiology of primary pulmonary RMS is still unknown.

We have two main hypotheses for its origin: First, considering the common association of RMS with pulmonary malformations such as cystic adenomatosis reported in previous studies, it might have been originated from heterotopic islets of striated muscle, and second, in the absence of congenital abnormalities, it might have been developed from metaplastic changes in uncommitted mesenchymal cells (5).

Lung neoplasms can usually present as a cough, respiratory distress, hemoptysis, chest pain, and/or recurrent pneumonitis; and we can expect the same symptoms for RMS (1). Our patient also had fever and cough symptoms. Spontaneous pneumothorax has been reported in RMS cases that can grow in the presence of CCAM (6).

The main differential diagnoses in patients with this condition are lymphoma, pleuropulmonary blastoma, malignant peripheral nerve sheath tumors (MPNST), primitive neuroectodermal tumors (PNET)/EWING, and neuroblastoma. In RMS, we cannot see blastema, anaplastic and epithelial components in pleuropulmonary blastoma. In immunohistochemistry evaluations, among

other differential diagnoses, the nuclear positivity for MyoD1 and myogenin is specific for RMS that was positive in our patient.

Hafiz et al. (2021) studied a primary pulmonary alveolar RMS and in their review of literature identified 32 cases reported from 1970 to 2021 with a primary pulmonary RMS in the pediatric age group (7). The first pediatric case of primary RMS was reported by Fallon et al. in a six-year-old girl in 1970 (6). Our patient is 30 months old, while most of the other reported cases were in an age range of 5 months to 16 years old. However, our case symptoms represent the 33 cases with RMS arising within CCAM from 1970 until now. Among the similar cases, nine of them developed in a background of CCAM, while the others set in a normal lung (7).

### 4- CONCLUSION

RMS with the primary pulmonary feature is rare in childhood and exhibits aggressive behaviors. Therefore, RMS should be included in any lung mass differential diagnosis with small round blue cell morphology. Moreover, it is necessary to exclude metastatic RMS from other sites with clinical and radiological assessment. In addition to RMS, other differential diagnoses that should be considered for lung mass are lymphoma, pleuropulmonary blastoma, PNET/EWING, neuroblastoma, and MPNST.

### 5- REFERENCES

1. Hancock BJ, Di Lorenzo M, Youssef S, Yazbeck S, Marcotte J-E, Collin P-P. Childhood primary pulmonary neoplasms. *Journal of pediatric surgery*. 1993; 28(9):1133-6.
2. Doladzas T, Arvelakis A, Karavokiros IG, Gougou Die, Pikoulis E, Patsouris E, et al. Primary rhabdomyosarcoma of the lung arising over cystic pulmonary

adenomatoid malformation. *Pediatric hematology and oncology*. 2005; 22(6):525-9.

3. Murphy JJ, Blair GK, Fraser GC, Ashmore PG, LeBlanc JG, Sett SS, et al. Rhabdomyosarcoma arising within congenital pulmonary cysts: report of three cases. *Journal of pediatric surgery*. 1992; 27(10):1364-7.

4. Choi JH, Ro JY. The 2020 WHO classification of tumors of soft tissue: selected changes and new entities. *Advances in Anatomic Pathology*. 2021; 28(1):44-58.

5. Chi JG, Song YK. Diffuse striated muscle heteroplasia of the lung. An autopsy case. *Archives of Pathology & Laboratory Medicine*. 1982; 106(12):641-4.

6. Fallon G, Schiller M, Kilman JW. Primary rhabdomyosarcoma of the bronchus. *The Annals of Thoracic Surgery*. 1971; 12(6):650-4.

7. Hafiz B, Bamefleh H. Primary Pulmonary Alveolar Rhabdomyosarcoma in a Pediatric Patient: A Case Report with Literature Review. *Cureus*. 2022; 14(1).