

Natural Disease History and Characterization of SUMF1 Molecular Defects in Multiple Sulfatase Deficiency: a Case Report

Shokoufeh Khanzadeh¹, Meisam Babaei², Parvin Imanpour³, *Shahram Sadeghvand⁴

¹ Medical student, Student Research Committee, Tabriz University of Medical Sciences, Tabriz, Iran.

² Assistant Professor of Pediatric Neurology, Department of pediatrics, North Khorasan University of Medical Sciences, Bojnurd, Iran.

³ Pediatrician, Clinical Research Development Unit of Children Hospital Tabriz University of Medical Sciences, Tabriz, Iran.

⁴ Assistant Professor of Pediatric Neurology, Clinical Research Development Unit of Children Hospital Tabriz University of Medical Sciences, Tabriz, Iran.

Abstract

Multiple sulfatase deficiency (MSD) is a very rare Lysosomal Storage Disease (LSD) caused by mutations in the SUMF1 gene. So far, about 143 patients with MSD have been reported in previous studies, although this figure is likely an underestimation due to under-reporting and under-recognition. The present report shows the genetic and clinical aspects of a patient with MSD in comparison to the previously reported patients.

Key Words: Lysosomal storage disease, Multiple sulfatase deficiency, SUMF1 gene.

* Please cite this article as: Khanzadeh S, Babaei M, Imanpour P, Sadeghvand S. Natural Disease History and Characterization of SUMF1 Molecular Defects in Multiple Sulfatase Deficiency: a Case Report. Int J Pediatr 2021; 9 (12):15047-15053. DOI: **10.22038/IJP.2021.57775.4532**

* Corresponding Author:

Shahram Sadeghvand, Assistant Professor of Pediatric Neurology, Clinical Research Development Unit of Children Hospital Tabriz University of Medical Sciences, Tabriz, Iran. Email: Shahram.sadegh_vand@yahoo.com

Received date: May.15,2021; Accepted date:Oct.5,2021

1- INTRODUCTION

Considering the number of cases reported with Multiple Sulfatase Deficiency (MSD), caused by mutations in the SUMF1 gene (1-3), it is a very rare Lysosomal Storage Disease (LSD). Previous studies have reported about 143 patients with MSD, which seems to be an underestimation due to under-reporting and under-recognition. This report attempts to clarify the genetic and clinical aspects of a patient with MSD, as compared to the previously reported ones. Prior to the study, an informed consent was obtained from his parents.

2- CASE REPORT

The boy was born in a healthy and Iranian family with first-cousin parents after an uneventful pregnancy at 37 weeks of gestation by cesarean delivery with a seemingly normal Apgar score. He was immediately hospitalized in the neonatal intensive care unit (NICU) and was there for 11 days. Due to apnea coupled with hypotonia and cyanosis, treatment with phenobarbital was administered for him. However, his birth parameters were normal (HC, 33 cm; BL, 49.5 cm; BW, 2450 kg). When he was eight months old, his head suddenly became larger; the diagnosis of communicating hydrocephalus was made for him, and he underwent medication therapy. As a 20-month-old boy, he represented psychomotor delay and developed a tonic seizure. Shortly afterward, he underwent a rapidly progressive loss of muscle tone and psychomotor skills. Social contact eventually deteriorated (no visual contact, no speech, and no parent identification). In the following months, he was admitted repeatedly to our hospital due to recurrent pneumonia, gastroenteritis, and clonic-type seizures. Taking a family history, we found no neurologic problem in the family.

At the last clinical examination, he was 3.5 years old when he presented to our

children's hospital emergency department with a clonic seizure coupled with apnea. He was bedridden and suffered from global developmental delay (GDD), meaning that he was not able to speak, make eye contact, identify his parents, and sit or walk independently. He weighed 8.5 kg (<1st percentile), his height was 85cm (<1st percentile), and had a head circumflex of 52cm (>97th percentile). The clinical examination revealed hypotonia of the lower and upper limbs, abnormal palmar crease, macrocephalus (head circumflex: 52, >95th percentile), hypertrichosis, absent deep tendon reflex, and hepatomegaly (projection of the liver edge 5cm below the costal margin). Also, skeletal deformities (pectus carinatum, kyphosis, and scoliosis) were noted. Morphologically, he presented with hirsutism, broad thumbs, severe muscular atrophy, and delayed growth. His facial features had become slightly coarse and dysmorphic (thick and high arched eyebrows, orbital hypertelorism, long eyelashes, prominent and smooth philtrum, anteverted nostrils, depressed nasal bridge, and posteriorly rotated ears). Furthermore, his neck was considerably short (**Fig. 1A, B, C, D**). Diffuse ichthyosis of the lower limbs extensor surface and the dorsum of foot was noted. Also, he showed dry, rough, and scaly skin resulting from cradle cap (seborrheic dermatitis). In addition, there was brachydactyly (**Fig. 2A, B**). The dermatologist confirmed common (vulgar) ichthyosis. The anterior and posterior fontanelles were still open (3cm×2cm and 0.5cm ×0.5cm, respectively). The boy had a left undescended testicle and a normal left testicle. The ophthalmologic investigation was normal. **Fig. 3** shows brain magnetic resonance imaging (MRI) of our patient. Visual examination was normal. The EMG-NCV reported sensory-motor demyelinating polyneuropathy of both upper and lower limbs and EEG left diffuse slowing pattern (encephalopathic pattern) (**Fig. 4**).

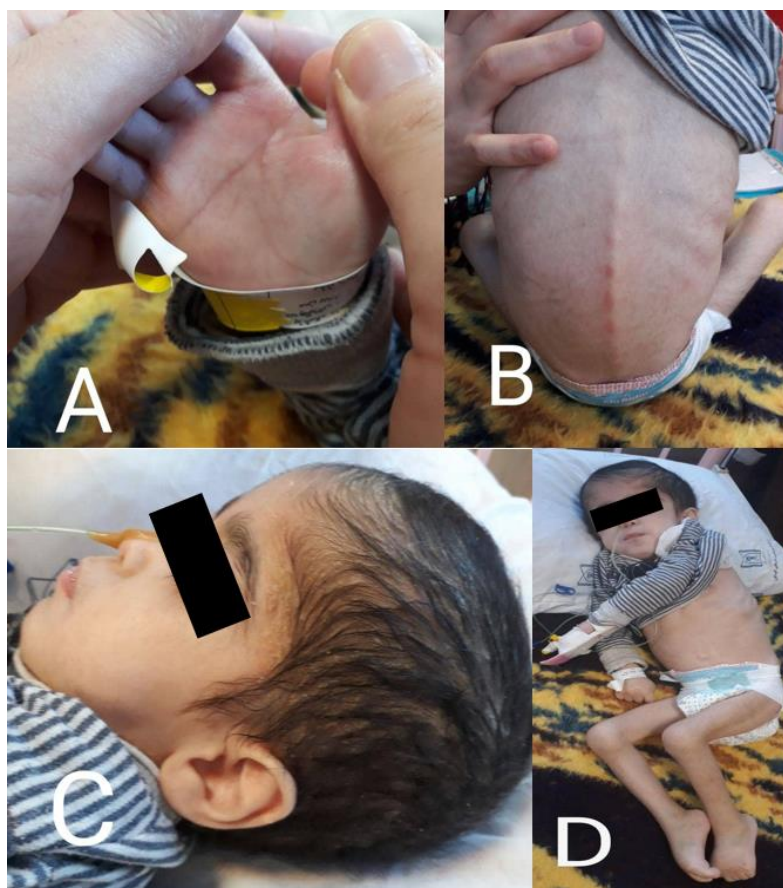


Fig. 1: Phenotype: **A.** abnormal palmar crease. **B.** kyphosis and scoliosis. **C.** long eyelashes, prominent and smooth philtrum, anteverted nostrils, depressed nasal bridge and posteriorly rotated ears, hirsutism, cradle cap (seborrheic dermatitis), and short neck. **D.** coarse face, orbital hypertelorism, severe muscular atrophy and delayed growth, thick and high arched eyebrows

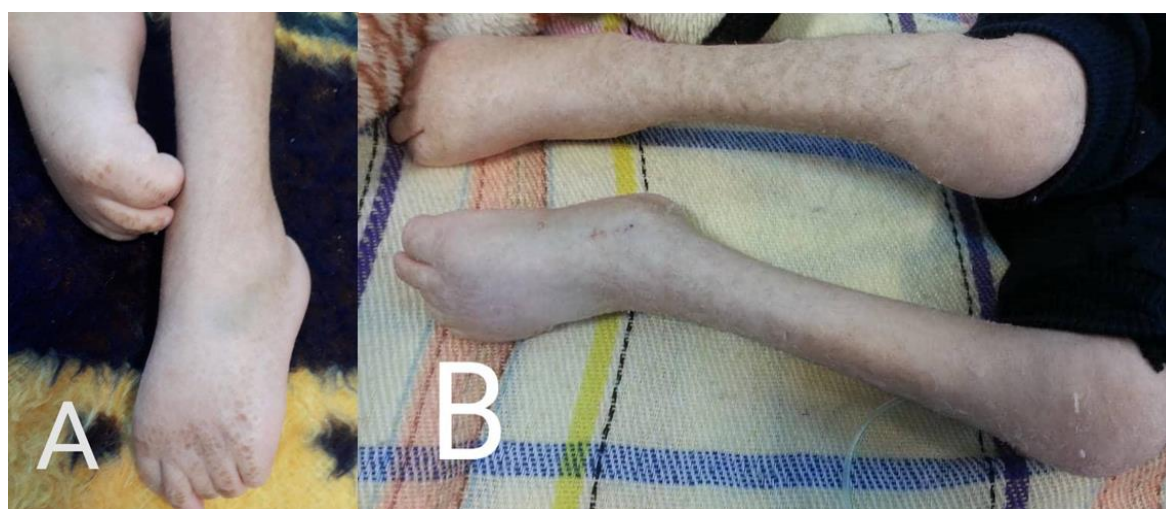


Fig. 2: Dermatologic problems: **A.** ichthyosis of the lower limbs extensor surface and the dorsum of foot, brachydactyly. Note the broad thumb. **B.** dry, rough, and scaly skin, hirsutism.

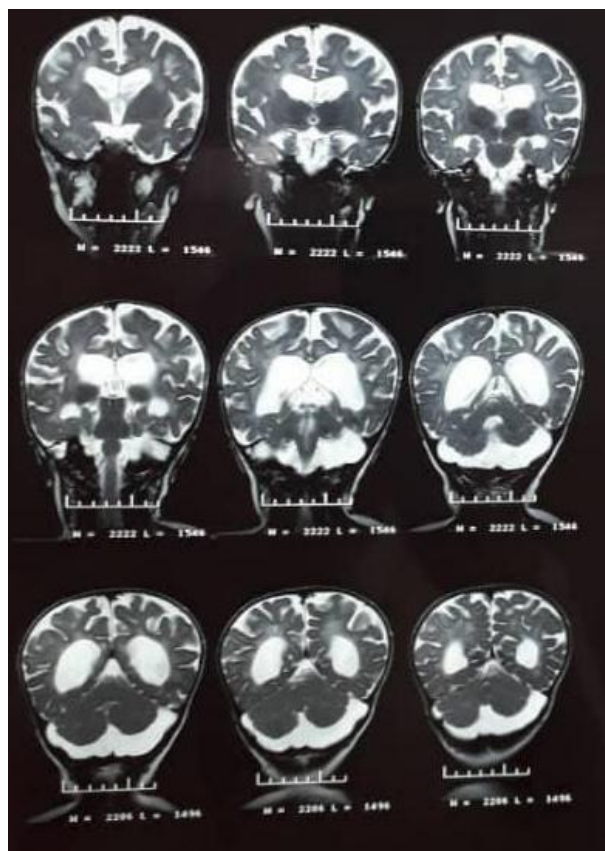


Fig. 3: MRI: Abnormal signal intensity and generalized loss of the white matter, thin corpus callosum and diffuse cerebellar atrophy. These findings were compatible with leukodystrophy

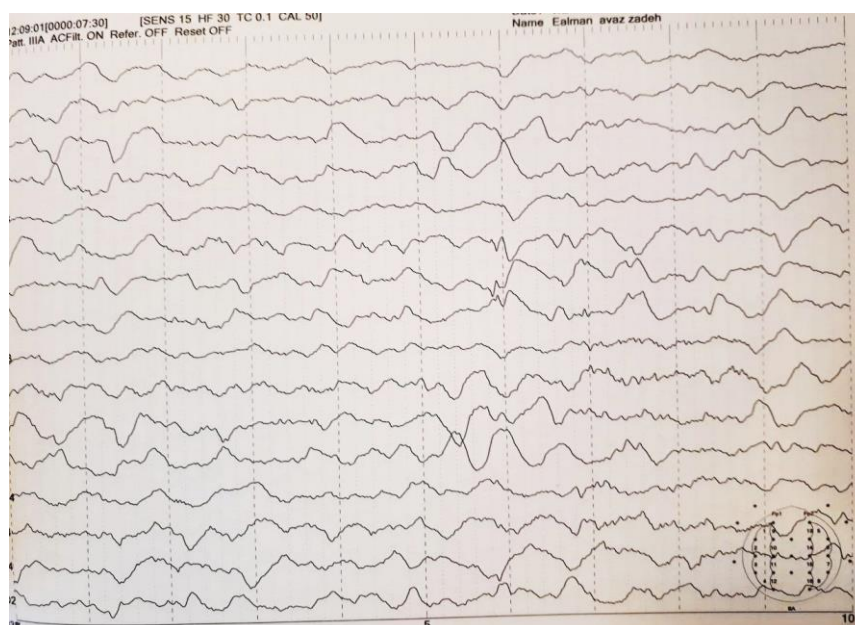


Fig. 4: EEG: Diffuse slowing pattern (encephalopathic pattern)

The patient underwent an auditory brainstem response (ABR) test and showed severe hearing loss in both ears. CSF was not sampled. An echocardiogram revealed normal results. Abdominal ultrasound revealed hepatomegaly. X-rays of the thoracolumbar spine, wrist, pelvis and lower extremities were obtained and shown in **Fig. 5A, B, C, and D**.

Taken together, all of these signs were compatible with disabling and progressive

neurological disorder that was ultimately diagnosed as MSD by a genetic test. Instead of enzyme activity testing, the individual's DNA was extracted from a blood sample for whole Exome sequencing (WES). Ultimately, the gene SUMF1 showed a homozygote mutation: c.739G>C, p. G247R in exon 6. The karyotype was normal, 46, XX. The genetic test and clinical findings were compatible with MSD.

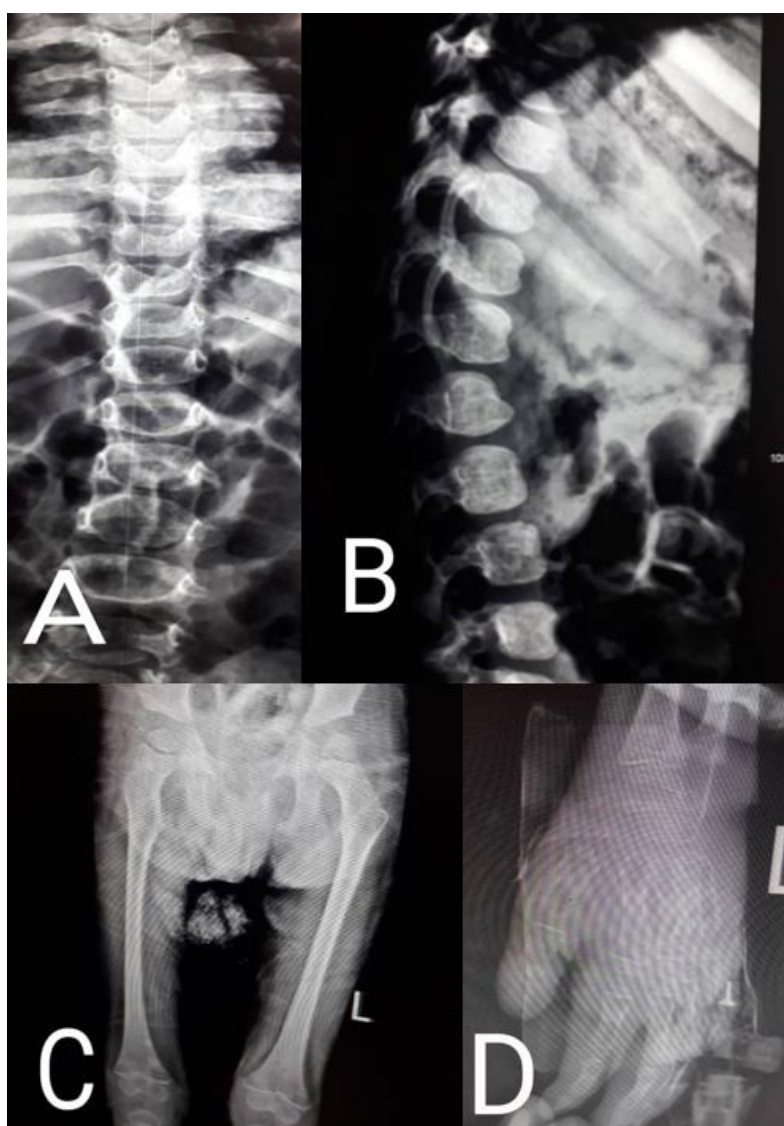


Fig. 5: X-Rays: **A.** oar-shaped / paddle ribs. **B.** anterior breaking of thoracolumbar spine and hypoplastic vertebral body result in kyphosis. **C.** bilateral hypoplasia of pubic bones and irregular and flat acetabula. **D.** hypoplastic and broad first metacarpals, pointing of the third and second metacarpals, proximal bulging of metacarpal bone and angulation of the distal ulnar and radial metaphysis.

3- DISCUSSION

MSD is an ultra-rare autosomal recessive inborn impairment of metabolism, influencing post-translational activation of human sulfatases by FGE. Due to missense and nonsense mutations in the SUMF1 gene, the catalytic activity of FGE deteriorates, leading to reduced human sulfatase activities (4). Approximately 50 SUMF1 mutations are discovered. The majority of them are missense types that influence residual molecular activity and stability of mutant FGE, that both relate to MSD severity (5, 6). The estimated disorder prevalence is about 1 in 500,000 (7). A genetic test of our patient revealed a mutation in the allele of c.739G > C, p. G247R. This is the most prevalent mutation in MSD and is considered a severe missense variant with severe reduction of stability and activity of human sulfatases (6). The diagnosis is not easy due to the ultra-rarity of the disorder. In our patient, the signs that led the team to suspect the MSD were the coarse face, the cutaneous features, and particularly the radiological findings consistent with dysostosis multiplex. In previous studies, the most frequently reported sign/symptoms were ichthyosis (71%), organomegaly (57%), dysostosis multiplex (56%), and dysmorphic features (53%), respectively (6). Our patient had typical manifestations of neonatal MSD, including all these signs. Indeed, the development of these signs is a very helpful indicator in identifying the disorder. Although skeletal (17%) and nutritional and gastrointestinal (14%) problems were the most common signs at birth, (6) in our case, apnea, hypotonia, and cyanosis were detected at birth. It was similar to the case previously described (8). Another Iranian neonate with MSD was also, previously, reported who presented the typical clinical symptoms of the disorder (9).

4- CONCLUSION

MSD is still an incurable disorder. So, genetic counseling and potential treatment strategies entirely depend on complete functional and molecular analysis of SUMF1 mutations on the biochemical and clinical phenotype.

5- CONFLICT OF INTEREST: None.

6- REFERENCE

1. Cosma MP, Pepe S, Annunziata I, Newbold RF, Grompe M, Parenti G, et al. The multiple sulfatase deficiency gene encodes an essential and limiting factor for the activity of sulfatases. *Cell*. 2003; 113(4):445-56.
2. Dierks T, Schmidt B, Borissenko LV, Peng J, Preusser A, Mariappan M, et al. Multiple sulfatase deficiency is caused by mutations in the gene encoding the human α -formylglycine generating enzyme. *Cell*. 2003; 113(4):435-44.
3. Dierks T, Dickmanns A, Preusser-Kunze A, Schmidt B, Mariappan M, von Figura K, et al. Molecular basis for multiple sulfatase deficiency and mechanism for formylglycine generation of the human formylglycine-generating enzyme. *Cell*. 2005; 121(4):541-52.
4. Schlotawa L, Radhakrishnan K, Baumgartner M, Schmid R, Schmidt B, Dierks T, et al. Rapid degradation of an active formylglycine generating enzyme variant leads to a late infantile severe form of multiple sulfatase deficiency. *European Journal of Human Genetics*. 2013; 21(9):1020-3.
5. Schlotawa L, Steinfeld R, Figura Kv, Dierks T, Gärtner J. Molecular analysis of SUMF1 mutations: stability and residual activity of mutant formylglycine-generating enzyme determine disease severity in multiple sulfatase deficiency. *Human mutation*. 2008; 29(1):205-.

6. Schlotawa L, Preiskorn J, Ahrens-Nicklas R, Schiller S, Adang LA, Gärtner J, et al. A systematic review and meta-analysis of published cases reveals the natural disease history in multiple sulfatase deficiency. *Journal of Inherited Metabolic Disease*. 2020; 43(6):1288-97.
7. Cappuccio G, Alagia M, Brunetti-Pierri N. A systematic cross-sectional survey of multiple sulfatase deficiency. *Molecular genetics and metabolism*. 2020; 130(4):283-8.
8. Garavelli L, Santoro L, Iori A, Gargano G, Braibanti S, Pedori S, et al. Multiple sulfatase deficiency with neonatal manifestation. *Italian journal of pediatrics*. 2014; 40(1):1-4.
9. Mancini GM, Van Diggelen O, Huijmans J, Stroink H, de Coo R. Pitfalls in the diagnosis of multiple sulfatase deficiency. *Neuropediatrics*. 2001; 32(01):38-40.