

## Early Ductus Arteriosus Constriction: A Rare Case Presentation at 18 Weeks of Gestation

Reza Gerami<sup>1</sup>, Komeil Farajnejad Ghadi<sup>2</sup>, \*Soudeh Roudbari<sup>3</sup>

<sup>1</sup>MD, Assistant professor of Radiology, Radiation Sciences Research center (RSRC), AJA University of Medical Sciences, Tehran, Iran.

<sup>2</sup>MD, Department of Radiology, Iran University of Medical Sciences, Tehran, Iran.

<sup>3</sup>MD, Rajaie Cardiovascular Medical and Research Center, Iran University of Medical Sciences, Tehran, Iran.

### Abstract

The ductus arteriosus (DA) is a vital structure in fetal circulation, carrying about two thirds of the right ventricular (RV) output to the aorta. During fetal life, ductal patency is actively preserved by several different factors, and pathologic ductal constriction causes right-sided pressure overload of the heart, leading to RV failure. There have been many reports of ductal constriction so far, most of which are linked to maternal use of non-steroidal anti-inflammatory drugs, but they are mainly reported in the third trimester. In the present study, we report the case of a 25-year-old gravid 2 woman with premature constriction of the DA following maternal treatment with dexamethasone and ibuprofen at the very early age of 18 weeks of gestation. She was referred to the radiology department for fetal echocardiography after a recent ingestion of ibuprofen for back pain. She was found to have had a constricted ductus arteriosus 3 days after being medicated at the gestational age of 18 weeks.

**Key Words:** Constriction, Ductus Arteriosus, Fetal echocardiography.

\*Please, cite this article as Gerami R, Farajnejad Ghadi K, Roudbari S. Early Ductus Arteriosus Constriction: A Rare Case Presentation at 18 Weeks of Gestation. *Int J Pediatr* 2020; 8(8): 11861-866. DOI: **10.22038/ijp.2020.50615.4023**

---

### \*Corresponding Author:

Soudeh Roudbari, MD, Rajaie Cardiovascular Medical and Research Center, Iran University of Medical Sciences, Tehran, Iran.

Email: [Soudeh.r@gmail.com](mailto:Soudeh.r@gmail.com)

Received date: Jun.24, 2020; Accepted date: Jul.12, 2020

## 1- INTRODUCTION

The ductus arteriosus (DA) is a vital structure in fetal circulation, carrying about two thirds of the right ventricular (RV) output to the aorta. During fetal life, ductal patency is actively preserved by several different factors, and pathologic ductal constriction causes pressure overload to the right side of the heart, leading to RV failure (1-2). There have been many reports of ductal constriction so far, most of which are linked to maternal use of non-steroidal anti-inflammatory drugs (NSAIDs) (3-6). NSAIDs are widely used for the treatment of mild pain, but are also administered in particular pregnancy-related conditions. Nevertheless, using NSAIDs in pregnancy may result in adverse fetal effects due to the inhibition of prostaglandin synthesis, leading to constriction or closure of the DA (7). The present study reports a case of premature constriction of the DA following maternal treatment with dexamethasone and ibuprofen at the very early age of 18 weeks of gestation.

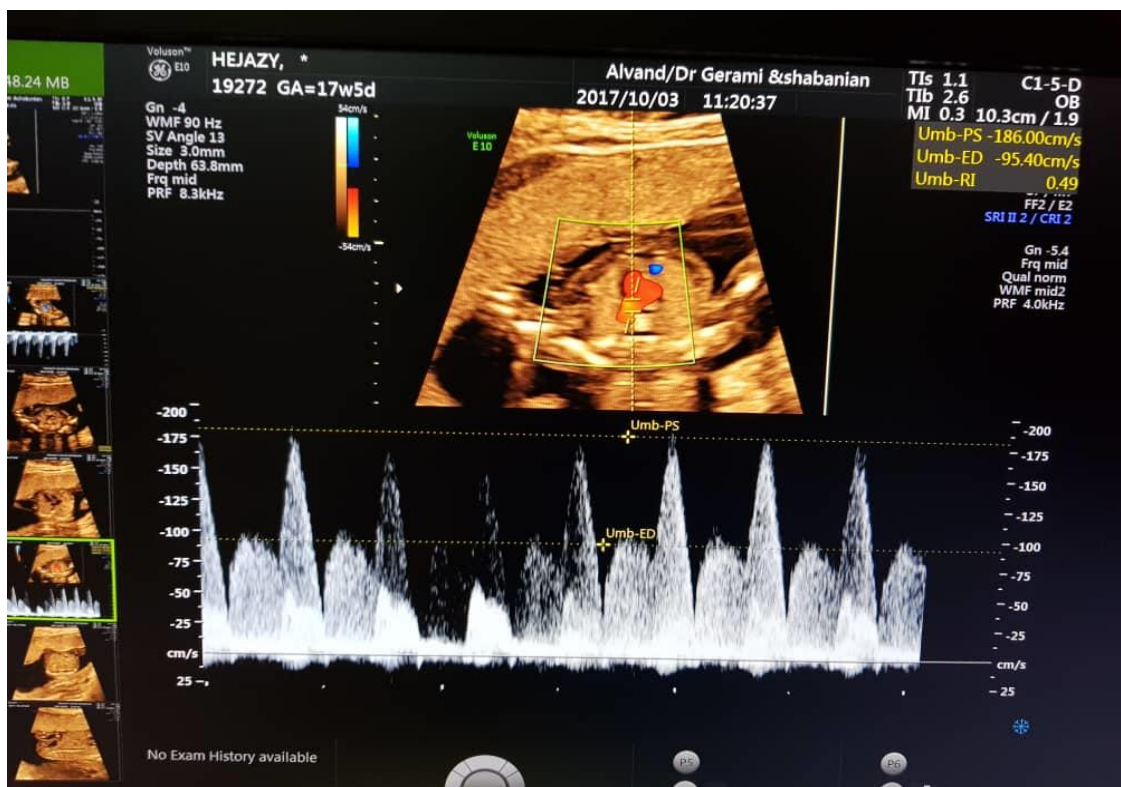
## 2- CASE REPORTS

A 25 year old, gravid 2, 18 weeks pregnant woman was referred to the Alvand Radiology and Ultrasound Center, in Tehran, Iran, on October 3, 2017, for fetal echocardiography due to recent ingestion of ibuprofen. She had no notable medical history of congenital heart disease, did not complain of any apparent distressing signs or symptoms, and denied

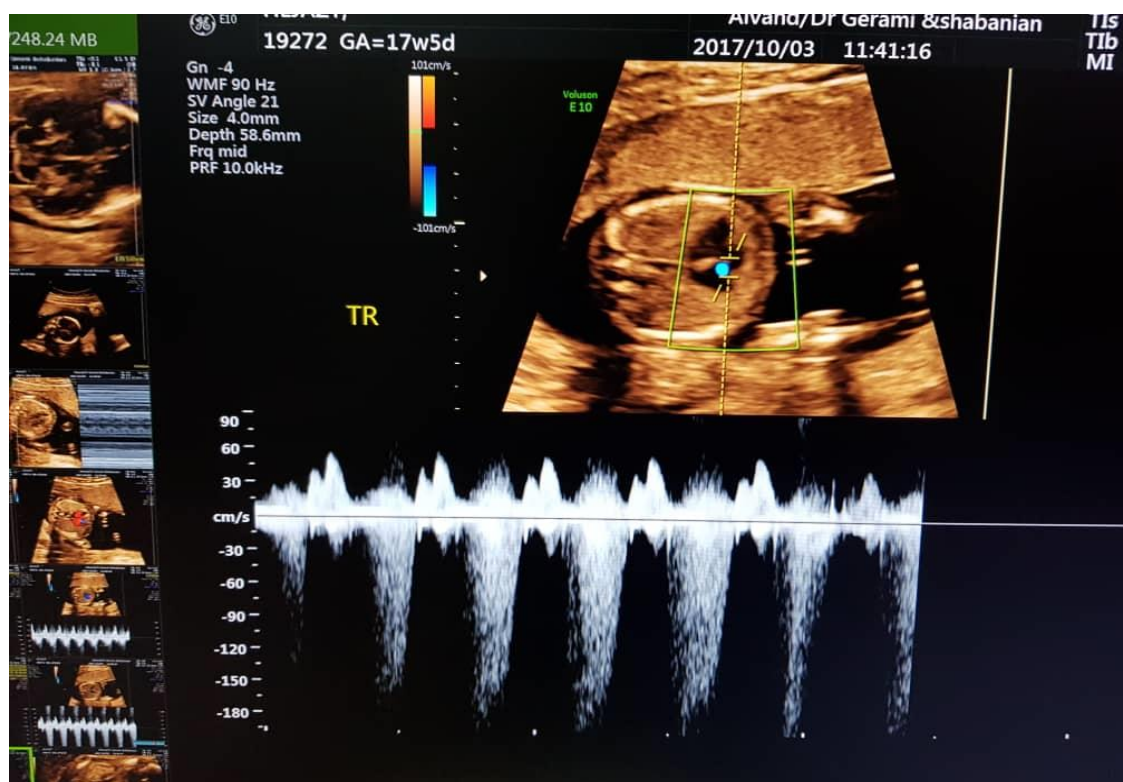
any use of medications except one intramuscular dose of dexamethasone and ibuprofen 400mg/BD in the last 3 days to control her back pain. Her first trimester ultrasound was normal. Fetal echocardiography report revealed a normal four chamber view, where the atria and ventricles had normal size and thickness. Both atrioventricular valves moved normally. The two great arteries ascended normally from the appropriate ventricles. The pulmonary and aortic valves appeared normal and the size of both the main pulmonary artery and the root of aorta were within normal limits. The aortic arch had a normal location and the main pulmonary artery bifurcated into two pulmonary branch arteries, but was not continuous with the DA. A significantly increased systolic (186cm/s) and diastolic (95cm/s) velocity was seen in the DA in favor of DA constriction. Also, the DA arterial resistance was fairly reduced and had low pulsatility and resistive indices (PI=0.9 and RI=0.49) (**Figure. 1**). Furthermore, significant tricuspid regurgitation (TR) was seen at the level of the tricuspid valve (**Figure. 2**).

### 2-1. Consent

The patient and her family were fully informed that the data collected would be submitted for publication solely for educational purposes and a written consent was obtained.



**Fig.1:** Doppler waveforms of the DA showing typical high velocities in systole (186 cm/s) and a second peak in diastole (95 cm/s) with a high pulsatility index (0.9).



**Fig.2:** Significant regurgitation can be seen at the level of the tricuspid valve.

### 3- DISCUSSION

The ductus arteriosus (DA) is a normal and vital structure in fetal circulation, and acts as a shunt to bypass the pulmonary vascular system resistance by diverting oxygen-rich blood returning from the caval system back into the systemic circulation. It anatomically connects the proximal descending aorta to the main pulmonary artery near the origin of the left branch of the pulmonary artery. The DA remains patent throughout fetal life by an active balance between prostaglandins, such as prostaglandin E<sub>2</sub> from the placenta and nitric oxide synthase from the endothelium, and the relatively low fetal oxygen tension in the intrauterine environment. This balance is altered after delivery as the duct closes spontaneously 24 hours after birth. However, the complete anatomical occlusion of the lumen may take several days or even weeks (1-3).

Certain circumstances can cause premature ductal constriction, leading to dilation of the right atrium and ventricle, tricuspid valve regurgitation, right-sided hypertrophy, cardiac failure, fetal hydrops, and ultimately, intrauterine death. The variability of symptoms related to DA constriction is probably related to its severity, but additional factors could also have a role. Some of these factors include the gestational age at time of constriction, the time during which the constriction has developed, the presence or absence of TR, and the amount of flow through the RV (4-6). There have been many reports of ductal constriction, most of which are related to maternal use of non-steroidal anti-inflammatory drugs (NSAIDs). NSAIDs are mostly used as analgesics for mild pain relief by the general population, and many of them are available over the counter. These drugs are a group of medications that reduce the production of the vasodilator prostaglandin through direct inhibition of the enzyme cyclooxygenase,

inducing systemic and pulmonary vasoconstriction. NSAIDs have also been widely used in pregnancy-related disorders, including polyhydramnios, and to prevent preterm labor because of their tocolytic activity, while also having other indications for chronic uses, such as in inflammatory bowel disorder or chronic rheumatic diseases. However, as previously mentioned, administration of NSAIDs in pregnancy may result in adverse effects on the fetus, as these medications can cross the placenta and lead to various levels of embryo-fetal and neonatal problems depending on the type of the agent, the dose and duration of therapy, the period of gestation, and the time elapsed between maternal NSAID administration and delivery (7).

The most common NSAID responsible for constriction of the DA is indomethacin after the 27th week of gestation, which can produce a reversible dose-independent constriction. Some cases of ductal constriction have been associated with other medications such as paracetamol, naphazoline, fluoxetine, isoxsuprine, caffeine, aspirin, methimazole, and pesticides, with some cases having no clear cause and thereby considered as idiopathic (2, 3, 8). Ductal constriction in fetal echocardiography is defined as a peak systolic velocity of greater than 1.4 m/s in conjunction with a persistent diastolic peak flow velocity of greater than 0.35 m/s.

Nevertheless, velocities through the DA have been shown to increase gradually with advancing gestational age (9-10). The case presented in this paper had used ibuprofen and dexamethasone simultaneously, which had led to an early constriction of DA at the gestational age of 18 weeks. Similar cases have been reported after the use of diclofenac at higher gestational ages of 23 to 37 and sometimes even right after birth (11-15). In a recent study in 2018 (16), in 68 randomized clinical trials of 4802 infants,

14 different variations of indomethacin, ibuprofen, or acetaminophen were used as treatment modalities. The results showed that high doses of oral ibuprofen were associated with a higher likelihood of hemodynamically significant DA closure compared to standard doses of intravenous ibuprofen or intravenous indomethacin. In another study in 2019 (17), the effectiveness of multiple drugs used to constrict patent DA in newborns aged less than 28 weeks were evaluated. The study showed that indomethacin produced the most constriction, followed by ibuprofen and acetaminophen. Another recent research (18) presented 3 cases of prenatal premature constriction of the DA by over-the-counter NSAIDs such as benzydamine, and it was shown to have an equally deleterious effect on the DA as other NSAIDs in the third trimester of pregnancy.

#### 4- CONCLUSION

In conclusion, TSC and SMA are two inherited diseases with relatively low incidences. Although they are genetically distinct, and completely independent disorders, they may rarely occur together in an individual, simultaneously. Further studies are needed to obtain the patterns of genetic inheritance of these diseases in the reported patient.

**5- CONFLICT OF INTEREST:** None.

#### 6- REFERENCES

- Schneider DJ, Moore JW. Patent ductus arteriosus. *Circulation*. 2006; 114:1873–1882.
- Choi EY, Li M, Choi CW, Park KH, Choi JY. A case of progressive ductal constriction in a fetus. *Korean Circ J*. 2013; 43(11):774- 81.
- Lopes LM, Carrilho MC, Francisco RP, Lopes MA, Krebs VL, Zugaib M. Fetal ductus arteriosus constriction and closure: analysis of the causes and perinatal outcome related to 45 consecutive cases. *J Matern Fetal Neonatal Med*. 2016; 29(4):638- 45.
- Allegaert K, Mian P, Lapillonne A, van den Anker JN. Maternal paracetamol intake and fetal ductus arteriosus constriction or closure: a case series analysis. *Br J Clin Pharmacol*. 2019;85(1): 245- 51.
- Shima Y, Ishikawa H, Matsumura Y, Yashiro K, Nakajima M, Migita M. Idiopathic severe constriction of the fetal ductus arteriosus: a possible underestimated pathophysiology. *Eur J Pediatr*. 2011; 170(2):237- 40.
- Enzensberger, C., Wienhard, J., Weichert, J., Kawecki, A., Degenhardt, J., Vogel, M. and Axt-Flidner, R. Idiopathic Constriction of the Fetal Ductus Arteriosus. *Journal of Ultrasound in Medicine*. 2012; 31: 1285-91.
- Antonucci R, Zaffanello M, Puxeddu E, et al. Use of non-steroidal anti-inflammatory drugs in pregnancy: impact on the fetus and newborn. *Curr Drug Metab*. 2012;13(4):474- 90.
- Schiessl B, Schneider KT, Zimmermann A, Kainer F, Friese K, Oberhoffer R. Prenatal constriction of the fetal ductus arteriosus--related to maternal pain medication?. *Z Geburtshilfe Neonatol*. 2005;209(2):65- 8.
- Huhta JC, Moise KJ, Fisher DJ, Sharif DS, Wasserstrum N, Martin C. Detection and quantitation of constriction of the fetal ductus arteriosus by Doppler echocardiography. *Circulation* 1987; 75: 406–12.
- Trevett, T.N., Jr and Cotton, J. Idiopathic constriction of the fetal ductus arteriosus. *Ultrasound Obstet Gynecol*. 2004; 23: 517-19.
- Choi EY, Li M, Choi CW, Park KH, Choi JY. A case of progressive ductal constriction in a fetus. *Korean Circ J*. 2013;43(11):774- 81.
- Aker K, Brantberg A, Nyenes SA. Prenatal constriction of the ductus arteriosus following maternal diclofenac medication in the third trimester. *BMJ Case Rep*. 2015; 2015:bcr2015210473.

13. Rein AJ, Nadjari M, Elchalal U, Nir A. Contraction of the fetal ductus arteriosus induced by diclofenac. Case report. *Fetal Diagn Ther.* 1999; 14(1):24- 5.
14. Siu KL, Lee WH. Maternal diclofenac sodium ingestion and severe neonatal pulmonary hypertension. *J Paediatr Child Health.* 2004; 40(3):152- 53.
15. Auer M, Brezinka C, Eller P, Luze K, Schweigmann U, Schwärzler P. Prenatal diagnosis of intrauterine premature closure of the ductus arteriosus following maternal diclofenac application. *Ultrasound Obstet Gynecol.*2004; 23: 513-16.
16. Mitra S, Florez ID, Tamayo ME, et al. Association of Placebo, Indomethacin, Ibuprofen, and Acetaminophen With Closure of Hemodynamically Significant Patent Ductus Arteriosus in Preterm Infants: A Systematic Review and Meta-analysis. *JAMA.*2018;319(12):1221-38.
17. Liebowitz M, Kaempf J, Erdeve O, et al. Comparative effectiveness of drugs used to constrict the patent ductus arteriosus: a secondary analysis of the PDA-TOLERATE trial (NCT01958320). *J Perinatol.* 2019; 39(5):599-607.
18. Krzeszowski W, Wilczyński J, Grzesiak M, Nowakowska D. Prenatal sonographic diagnosis of premature constriction of the fetal ductus arteriosus after maternal self-medication with benzydamine hydrochloride: report of 3 cases and review of the literature. *J Ultrasound Med.* 2015; 34(3):531-35.