

Are Children Less Susceptible To COVID-19? A Case Series

Saeedeh Derhami¹, *Shaghayegh Rahmani², Nasrin Jalalimanesh³

¹Emergency Medicine Resident, Emergency Department, Faculty of Medicine, Mashhad University of Medical Sciences, Mashhad, Iran.

²Assistant Professor of Emergency Medicine, Innovated Medical Research Center, Mashhad Branch, Islamic Azad University, Mashhad, Iran.

³Pediatric Specialist, Faculty of Medicine, North Khorasan University of Medical Sciences, Bojnourd, Iran.

Abstract

Background

The novel coronavirus (SARS-CoV-2 [2019-nCoV]) is the origin of several cases of pneumonia in Wuhan, Hubei province, China. According to the reported data, children are less common to be infected by COVID-19. Besides, their mortality rate is almost zero.

Case Presentation

In this article, we investigated six children who were infected by COVID-19 and discuss the various symptoms of disease in children.

Conclusion

In this article, we investigated six children with various clinical manifestations, and based on our patients' presentations, death undoubtedly occurs among children infected by COVID-19. The majority of our sample population includes boys, therefore we suggest this theory that this virus is more probable to be severe among the male gender.

Key Words: Children, COVID-19, Mortality.

*Please cite this article as: Derhami S, Rahmani Sh, Jalalimanesh N. Are Children Less Susceptible To COVID-19? A Case Series. Int J Pediatr 2020; 8(7): 11603-608. DOI: **10.22038/ijp.2020.48891.3924**

*Corresponding Author:

Shaghayegh Rahmani, MD, Assistant professor of Emergency Medicine, Innovated Medical Research Center & Department of Immunology, Mashhad Branch, Islamic Azad University, Mashhad, Iran.

Email: sh79316@yahoo.com

Received date: Mar.25, 2020; Accepted date: Jun.22, 2020

1- INTRODUCTION

The novel coronavirus (SARS-CoV-2 [2019-nCoV]) is the origin of several cases of pneumonia in Wuhan, Hubei province, China (1). This viral infection rapidly spread worldwide. This novel coronavirus is named *2019-nCoV* by the World Health Organization (WHO). COVID-19 became a global concern in early 2020 and is labeled as a pandemic. COVID-19 transmits human-to-human through respiratory droplets and close contact, the possibility of the fecal-oral route also has been proposed, recently (2-4). According to the reported data, children are less common to be infected by COVID-19. Besides, their mortality rate is almost zero (5). On the other hand, clinical characteristics of COVID-19 in pediatrics are non-specific, which explain the fewer number of COVID-19 among children. However, the recent improvement in screening methods makes these findings ambiguous in children. It is not clear why children are less susceptible to be infected by COVID-19. In this article, we report six children infected by COVID-19 and discuss the various symptoms of the virus among children. These children referred to several hospitals in North Khorasan

between April and May 2020. Throat swabs were obtained from all children and it was positive for 2019-nCoV on real-time reverse-transcription-polymerase-chain-reaction (RT-PCR) assays.

2- CASE REPORT

Case.1

A six-year-old boy was referred to our hospital with seizure and loss of consciousness. His vital sign was as below: heart rate (HR): 110/minute, blood pressure (BP): 60/ MmHg, body temperature (BT): 37°C and O₂ saturation (SPO₂): 74%. He had apneustic respiration. Medical examination showed fixed and dilated pupils. Fine crackles were heard. The limbs were cold and cyanotic. Portable Chest X-ray (CXR) showed bilateral infiltration and a mass-like lesion in the right lung (**Figure.1**). Laboratory tests included positive C-Reactive Protein (CRP), and anemia, while other indicators were in normal ranges. His parents mentioned that he had flu like symptoms for the last four days. Despite the immediate resuscitation, intubation, aggressive fluid, and antibiotic therapy, the child was expired 4 hours after admission.

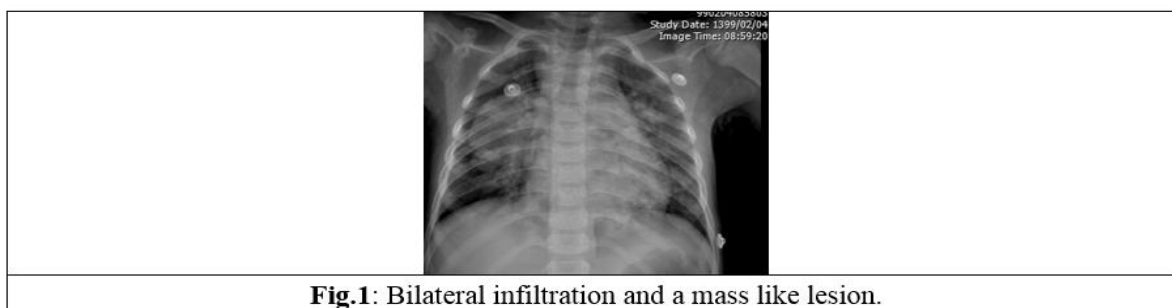

Fig.1: Bilateral infiltration and a mass like lesion.

Case.2

A one-year-old baby boy has referred to our academic hospital with fever and cough form 2 days ago. Examination showed tachycardia, tachypnea, and BT of 40° C. Fine bilateral crackles were auscultated. According to CXR and High-Resolution Computerized Scan (HRCT),

he had bilateral infiltration (**Figure.2**). The CRP and leukocytosis were positive according to the results of laboratory tests. He was admitted to the Intensive Care Unit (ICU), and broad-spectrum antibiotics were administered for him. He was discharged with partial recovery after eight days.

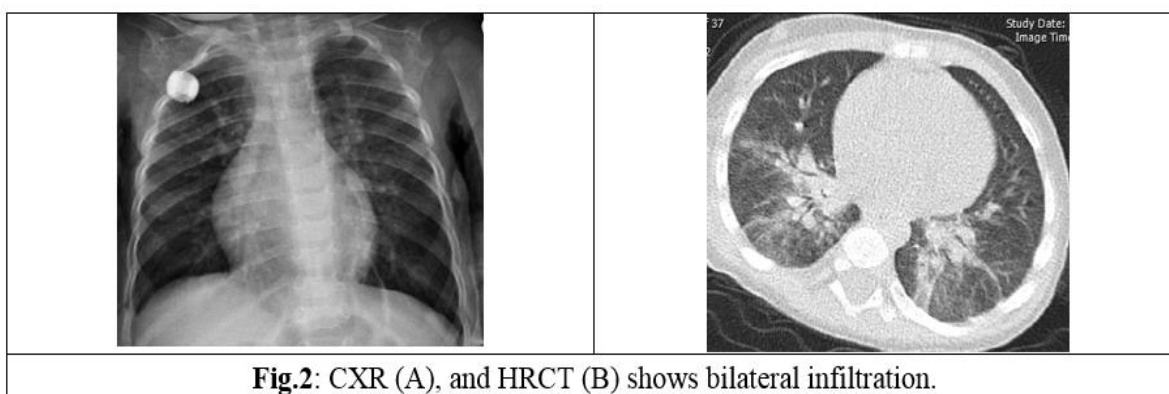


Fig.2: CXR (A), and HRCT (B) shows bilateral infiltration.

Case.3

A two- year- old boy was referred with fever and cough and a previous history of close contact with a suspicious patient for COVID-19. The child was returned to the hospital the examination by two medicians and receiving the oral antibiotics. Moreover, he had a fever, tachypnea, and

tachycardia at the admission moment. He had the ill appearance and bilateral crackle heard in the pulmonary examination. Bilateral infiltration was seen in CXR, and HRCT (**Figure.3**). He was admitted to the ICU ward and took broad-spectrum antibiotics. Moreover, he was recovered partially after 12 days and finally discharged.

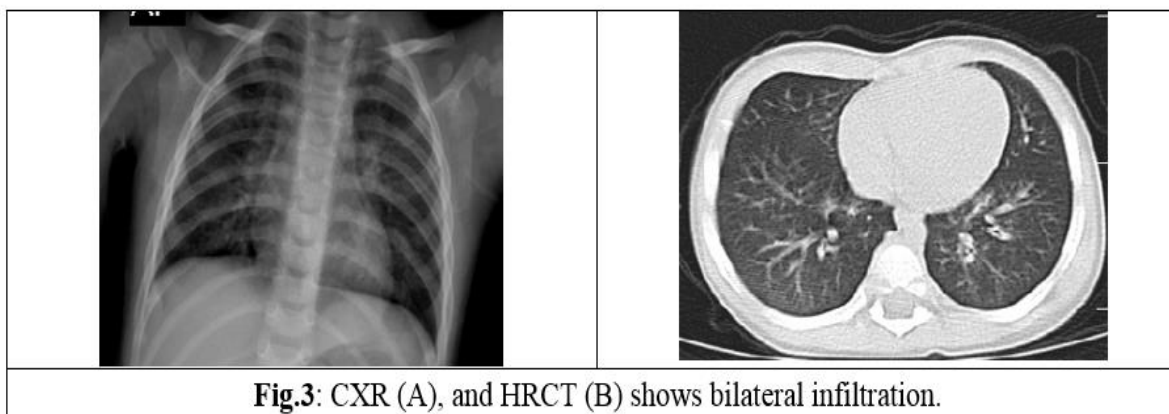


Fig.3: CXR (A), and HRCT (B) shows bilateral infiltration.

Case.4

Eight-year-old boy with a history of congenital heart disease (atrial septal defect [ASD]) was referred to our clinic with a fever form two days ago as the chief complaint. He had an ill appearance with a dry cough. Laboratory tests showed

lymphopenia, neutropenia, thrombocytopenia, and two plus positive CRP. He had no abnormal respiratory sound in auscultation. **Figure. 4** shows his CXR and HRCT. He was admitted to ICU admission and broad-spectrum antibiotics were administered for him. He was discharged after two weeks with recovery.

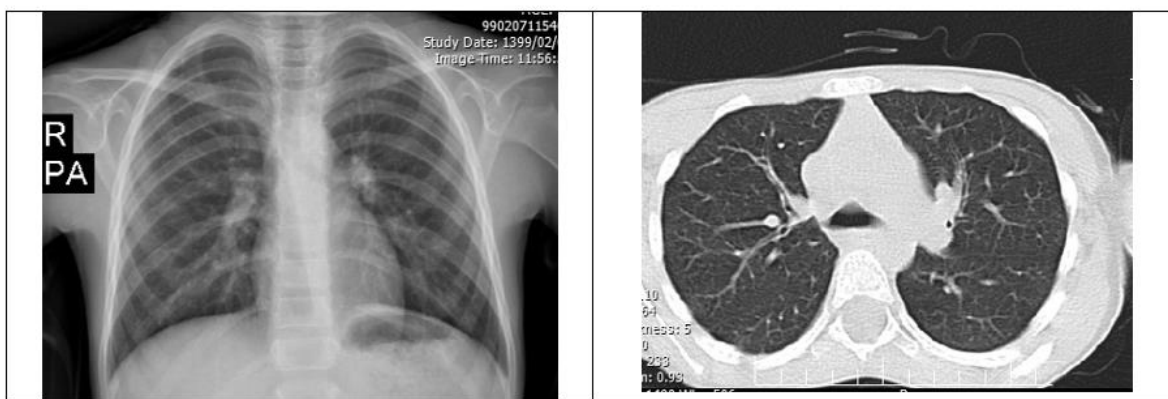


Fig.4: CXR (A), and HRCT (B) shows bilateral infiltration.

Case.5

A two-year-old previously addicted girl was referred to our emergency department with the suspicion of overdose. She has received 0.2 mg of naloxone during transfer to the hospital. On admission, she had BT of 40°C, tachycardia, and tachypnea. Her parents did not mention respiratory compliments. She was confused and had no neck stiffness in the examination. She became agitated in the

emergency department and had 20 seconds of Generalized Tonic-Clonic (GTC) seizure. Laboratory tests showed leukocytosis and positive CRP. **Figure. 5** shows her CXR and HRCT with bilateral infiltration. After a detailed evaluation by a child neurologist, encephalitis was proposed and supportive therapy was considered for her. She was hospitalized for 10 days and her consciousness level was normal after 2 days of admission.

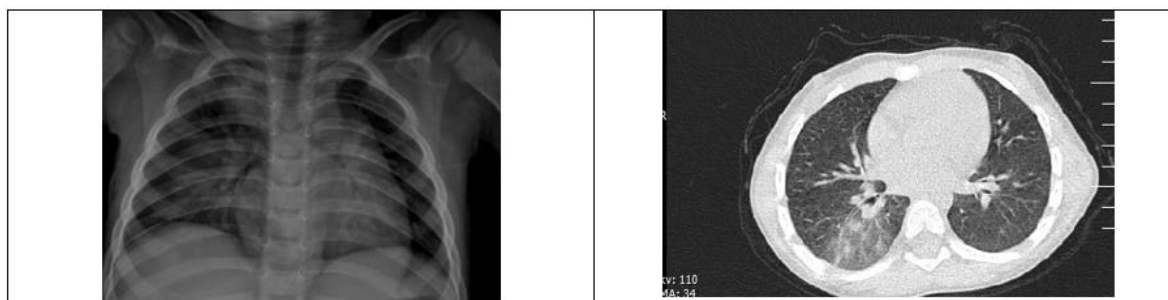
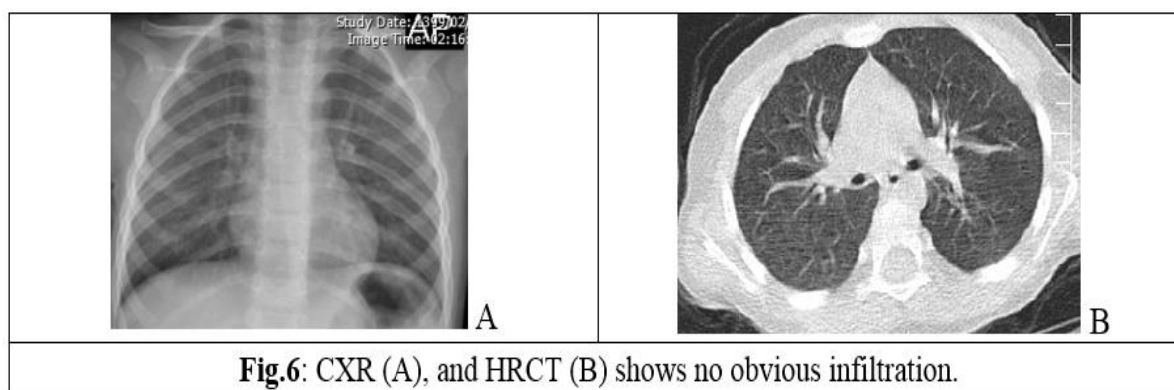


Fig.5: CXR (A), and HRCT (B) shows bilateral infiltration.

Case.6

A two-year-old healthy boy was referred to our emergency department with fever and abdominal pain. He had diarrhea, dry cough, and fever. He had no abdominal tenderness in medical examination. **Figure.6** shows his CXR and HRCT. Laboratory tests showed lymphopenia and

positive CRP. The results of other tests were in the normal range included liver function tests, amylase, urine analysis, stool exam, etc. abdominal ultrasound was also normal. He was admitted to the pediatric ward for close observation and supportive therapy. He was discharged after four days with full recovery.



3- DISCUSSION

Clinical characteristics of COVID-19 are non-specific among children. Moreover, it is not clear whether the pediatric population is at risk for COVID-19 or not. In this article, we report six children infected by COVID-19 with various presentations. Most of our cases were boys and we concluded that this virus is more probable to be severe among the male gender. The Severe Acute Respiratory Syndrome Coronavirus-2 (SARS-CoV-2) was started at the end of 2019, now labeled a global pandemic as COVID-19. This virus infected millions of people in different countries, in which there are some children among this population (3); with the virus have severe respiratory manifestations in adults, some cases experience rapid deterioration and need for intubation and mechanical ventilation. First published papers showed that children are less likely to be infected by COVID-19, and the chance of infection and mortality rate in children younger than 10 years is very low (6, 7). It was considered that children were asymptomatic or had mild manifestations. The reasons for children's resistance to some infectious diseases such as COVID-19 remain unclear. But wider screenings confirmed that children are easily infected and became symptomatic. Viral receptors distribution and maturation might be a possible cause of manifestations age-related differences. For instance, it was showed that ACE2 expression dramatically

decreases in rat lung with age (8). Fever, dry cough, rhinorrhea, sore throat, and fatigue are the most common symptoms in children. Gastrointestinal complaints such as diarrhea or vomiting are presented in nearly 10 % of children (9). All our reported cases had a fever, which did not respond to pyretic drugs. Abdominal pain was described in children with COVID-19 but it was not common. One of our children had unspecified abdominal pain, which was not accompanied by respiratory disease. We proposed that children with gastrointestinal infection might experience less severe disease. In the early phase of COVID-19 infection, CXR might be normal. Moreover, CT scans without contrast might help more than plain radiographies (10).

Only one of our reported cases had nearly normal CXR and HRCT. We suggest a CT-scan only in children with respiratory disorders. Neurologic complaints observed in adults with COVID-19 such as headache, loss of smell, and taste. But evaluating these symptoms in children is not easy. There is evidence that obesity is an independent risk factor associated with the severity of the disease. Male gender and hypertension are other probable risk factors. Two of the examined cases had neurologic manifestations and one died before further evaluation. As has been mentioned before encephalitis with negative CSF results is a clinical manifestation of COVID-19 (11).

4- CONCLUSION

Human coronaviruses cause mild upper respiratory tract infectious diseases. However, in the past two decades, two outbreaks of coronaviruses have been reported which lead to severe pneumonia with a high mortality rate. In the first reports, the chance of coronavirus infection in children was estimated very low. Based on the family cluster pattern of COVID-19 it occurs in pediatrics at a high rate. In this article, we introduced six children with various clinical manifestations, and based on our patients, death undoubtedly occurs in children infected by COVID-19.

5- ACKNOWLEDGMENT

We would like to express our particular thanks to our patients and their families.

6- CONFLICT OF INTEREST: None.

7- REFERENCES

- Jin Y, Yang H, Ji W, Wu W, Chen S, Zhang W, Duan G. Virology, Epidemiology, Pathogenesis, and Control of COVID-19. *Viruses*. 2020; 12(4). pii: E372. doi: 10.3390/v12040372.
- Goldman RD. Coronavirus disease 2019 in children: Surprising findings in the midst of a global pandemic. *Can FAM Physician*. 2020; 66(5):332-334.
- Ozma MA, Maroufi P, Khodadadi E, Köse Ş, Esposito I, Ganbarov K, et al. Clinical manifestation, diagnosis, prevention and control of SARS-CoV-2 (COVID-19) during the outbreak period. *Infez Med*. 2020 Ahead of print Jun 1; 28(2):153-165.
- Zimmermann P, Curtis N. Coronavirus Infections in Children Including COVID-19: An Overview of the Epidemiology, Clinical Features, Diagnosis, Treatment and Prevention Options in Children. *Pediatr Infect Dis J*. 2020; 39(5):355-368.
- Seyedi S J, Shojaeian R, Hiradfar M, Mohammadipour A, Alamdaran SA. Coronavirus Disease 2019 (COVID-19) Outbreak in Pediatrics and the Role of Pediatricians: A Systematic Review, *Iran J Pediatr*. Online ahead of Print; 30(2):e102784. doi: 10.5812/ijp.102784.
- Lee PI, Hu YL, Chen PY, Huang YC, Hsueh PR. Are children less susceptible to COVID-19? *J Microbiol Immunol Infect*. 2020. doi: 10.1016/j.jmii.2020.02.011.
- Lu Q, Shi Y. Coronavirus disease (COVID-19) and neonate: What neonatologist need to know. *J Med Virol*. 2020. doi: 10.1002/jmv.25740.
- Lu R, Zhao X, Li J, Niu P, Yang B, Wu H, et al. Genomic characterisation and epidemiology of 2019 novel coronavirus: implications for virus origins and receptor binding. *Lancet*. 2020 22-28 February; 395(10224): 565–74.
- Qiu H, Wu J, Hong L, Luo Y, Song Q, Chen D. Clinical and epidemiological features of 36 children with coronavirus disease 2019 (COVID-19) in Zhejiang, China: an observational cohort study. *Lancet Infect Dis*. 2020. Mar 25. doi: [https://doi.org/10.1016/S1473-3099\(20\)30198-5](https://doi.org/10.1016/S1473-3099(20)30198-5)
- Xia W, Shao J, Guo Y, Peng X, Li Z, Hu D. Clinical and CT features in pediatric patients with COVID-19 infection: Different points from adults. *Pediatr Pulmonol*. 2020. doi: 10.1002/ppul.24718.
- Ye M, Ren Y, Lv T. Encephalitis as a clinical manifestation of COVID-19 [published online ahead of print, 2020 Apr 10]. *Brain Behav Immun*. 2020; S0889-1591(20)30465-7.