

A Case of Sigmoid Volvulus in Pregnancy: A Rare Emergency in Pregnancy

Sara Ghahremani¹, Parisa Razmjouei², Parvaneh Layegh³, Ayoub Tavakolian⁴, Masumeh Ghazanfarpour⁵, Fatemeh Shoaee⁶, *Somayeh Moeindarbary⁷

¹Department of Pediatrics, Mashhad University of Medical Sciences, Mashhad, Iran. ²Shahid Faghihi Hospital, Department of Gynecology and Obstetrics, Shiraz University of Medical Sciences, Shiraz, Iran. ³Assistant Professor, Department of Radiology, School of Medicine, Mashhad University of Medical Sciences, Mashhad, Iran. ⁴Emergency Medicine Department, Faculty of Medicine, Sabzevar University of Medical Sciences, Sabzevar, Iran. ⁵Students Research Committee, Razi School of Nursing and Midwifery, Kerman University of Medical Sciences, Kerman, Iran. ⁶Kowsar Hospital, Department of Gynecology and Obstetrics, Shiraz University of Medical Sciences, Shiraz, Iran. ⁷Assistant Professor, Department of Obstetrics and Gynecology, Neonatal and Maternal Research Center, Mashhad University of Medical Sciences, Mashhad, Iran.

Abstract

Background

Sigmoid volvulus (SV) in pregnancy is a very rare entity, which can be associated with extremely high rates of mortality and morbidity for both mother and fetus.

Care Report

A 22-year-old female patient with a first pregnancy with a gestational age of 27 weeks was referred to the Omolbanin hospital, Mashhad, Iran, and presented with generalized pain, abdominal swelling, and abnormal bowel movements from a week ago. Intestinal loops with thick wall and fluid content decreased with decrease in peristalsis was seen in abdominal and pelvic ultrasound. In addition, abdominal and pelvic X-ray examination showed enlarged bowel with bent inner tube view. Due to severe abdominal pain and available evidence, she underwent laparotomy for suspected intestinal obstruction. A dilated sigmoid colon rotated about two times around its mesentery was seen adjacent to the pregnant uterus. The sigmoid was detorted and was fixed to the pelvic floor through its mesentery. The patient was discharged 4 days after surgery in good general condition, and her baby was born at 38 weeks of gestation by natural vaginal delivery.

Conclusion

Sigmoid volvulus during pregnancy is a rare complication. Its timely diagnosis will prevent intestinal gangrene and reduce maternal and fetal damage.

Key Words: Pregnancy, Surgical emergency, Sigmoid volvulus.

*Please cite this article as: Ghahremani S, Razmjouei P, Layegh P, Tavakolian A, Ghazanfarpour M, Shoaee F, et al. A Case of Sigmoid Volvulus in Pregnancy: A Rare Emergency in Pregnancy. Int J Pediatr 2020; 8(1): 10743-747. DOI: [10.22038/ijp.2020.45675.3734](https://doi.org/10.22038/ijp.2020.45675.3734)

*Corresponding Author:

Somayeh Moeindarbary (M.D), Department of Obstetrics and Gynecology, Neonatal and Maternal Research Center, Mashhad University of Medical Sciences, Mashhad, Iran.

Email: Moeins@mums.ac.ir

Received date: Nov.15, 2019; Accepted date: Dec.22, 2019

1- INTRODUCTION

Volvulus means rotation in the part of the intestine that leads to intestinal obstruction. The most common site for volvulus is the cecum and sigmoid colon. It can also occur in the stomach, gallbladder, colon and transverse colon. Sigmoid volvulus is a very rare complication during pregnancy. Only 104 cases have been reported since 1885 (1). The incidence of volvulus in pregnancy varies from 1: 1500 to 1:66,431. This complication is most commonly reported in people over the age of 70 years and with a history of chronic nerve disease or constipation (2). The incidence of volvulus in pregnancy does not increase, but it is more difficult to detect in pregnancy. During pregnancy, bowel obstruction occurs in more than half of the cases of adhesions due to previous surgeries, including cesarean section, and in less than a quarter of cases, due to bowel obstruction (3). Most cases of volvulus occur during the third trimester of pregnancy because at this time the large uterus causes the sigmoid to move out of the pelvis (4).

The clinical and radiographic signs of this complication during pregnancy are similar to those of non-pregnant women. The most common symptoms in pregnant women are persistent or intermittent abdominal pain, nausea and vomiting and abdominal tenderness. Abdominal pain is usually persistent, progressive, and severe. Vomiting develops a few days after symptoms. On examination, the abdomen is swollen and painful to the touch. Blood and electrolytes tests are usually normal in sigmoid volvulus in the absence of gangrene and peritonitis (5, 6). Volvulus management in pregnancy is a multifaceted approach with the collaboration of a gynecologist, neonatal specialist and general surgeon. Ultrasound and MRI are selective diagnostic methods, especially at the beginning of pregnancy.

During pregnancy, simple radiography is also helpful for diagnosis. Diagnostic findings in abdominal radiographs include observation of inverted-U dilated sigmoid colon or Coffee-bean sign. During pregnancy, the mortality rate due to obstruction is greatly increased due to the difficulty of diagnosis and delay (6, 7). In the absence of peritonitis or rupture of the bowel, bowel discharge is performed by an endoscope. It should be noted that in the third trimester of pregnancy, the large uterus limits its use and reduces the likelihood of its success (8). In addition, most surgeons recommend surgery to open the torsion to prevent recurrence. In the case of bowel gangrene, the standard surgical procedure is sigmoid removal and primary anastomosis (6). Here, we report a rare case of intestinal obstruction due to sigmoid volvulus in a young woman of 27 weeks gestation who avoided early bowel gangrene due to timely diagnosis and immediate surgery and was able to maintain the bowel.

2- CASE REPORT

The patient was a 22-year-old woman whose first pregnancy was gestational age 27 weeks based on ultrasound at 12 weeks, who was referred to the Omolbanin hospital, Mashhad, Iran. She complained of generalized abdominal pain and constipation from a week before the onset that progressively worsened. She had vomited several times since morning. On clinical examination pulse rate: 100, blood pressure: 110/60, T: 38°C oral was detected. On abdominal examination, there was severe abdominal distention with generalized tenderness without rebound tenderness. In lab tests, her hemoglobin was 11.3 g/dl (12-16g/dl), white blood cell was 17100 (4000-11000/cmm), and polymorphonuclear leukocytes (PMNs) was 87%. Liver enzymes and electrolytes were normal. On sonography, the liver, gall bladder and kidneys were normal, and on the left, intestinal loops with thick wall

and fluid content were observed with decreased peristalsis. Abdominal and

pelvic X-ray showed a dilated bowel with a bent inner tube view (**Figure.1**).

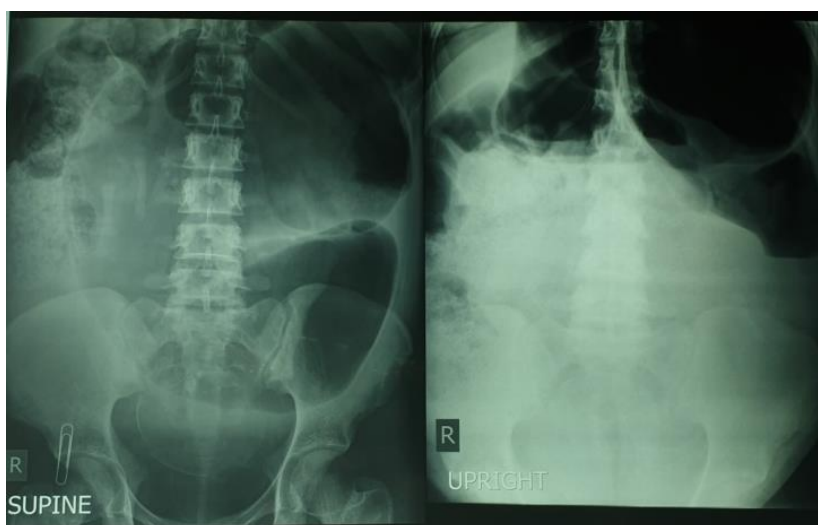

Fig.1: Abdominal X-ray image (lying / standing) showing fluid-air surface of dilated colon with inverted -U view.

Due to the patient's severe pain and X-ray findings that suspected intestinal obstruction, a laparotomy was performed with a median incision and a highly dilated sigmoid colon rotated about two times

around its mesentery near the pregnant uterus was seen; then torsion was opened and there was no evidence of sigmoid gangrene (**Figure.2**).

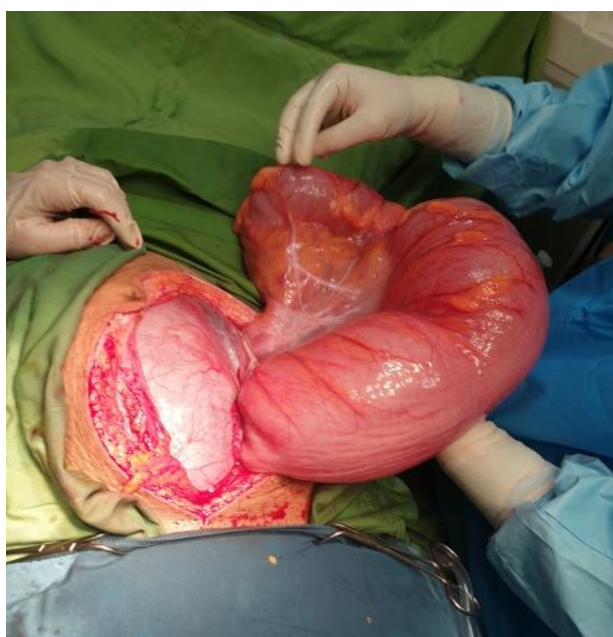


Fig.2: Picture taken during explorative laparotomy, showing dilated sigmoid volvulus on the right side and pregnant uterus on the left side.

The contents of the blocked part were drained through rectal tube insertion. Due to the lack of intestinal gangrene, sigmoid removal and primary anastomosis were not performed and after detorsion to prevent recurrence, sigmoid fixation to the pelvic wall was performed. Betamethasone was prescribed for fetal lung maturation after surgery due to diffuse uterine contractions and the risk of preterm labor. With prescription pain relief, uterine contractions were resolved 24 hours after surgery and ultrasound performed to assess fetal health was normal. The patient was discharged 4 days after surgery in good general condition and her baby was born at 38 weeks of gestational age by natural vaginal delivery; baby weighted 3,000 g with Apgar score 9 at 1 min and 10 at 5 min.

3- DISCUSSION

The incidence of sigmoid volvulus varies by geographic region and in western countries the annual incidence of this complication is 1.7-5.7:100,000 in adults and in Asia is 24-60:100,000 cases in adults. Median age at onset is 70 years (8, 9). Approximately 25 to 44% of all cases of intestinal obstruction in pregnancy are reported in the third trimester and are less likely to occur in the first trimester and puerperium (4, 10, 11). Our reported patient was a 22-year-old woman with a 27-weeks gestational age. Risk factors of intestinal obstruction include high-fiber diets, prolonged hospitalization, and chronic constipation, underlying diseases such as neurodegenerative diseases, Chagas disease and diabetes (2). However, our patient did not report a history of chronic constipation, prolonged activity decline, or any of the listed risk factors. Complications of sigmoid volvulus in pregnancy are highly influenced by gestational age, duration of symptoms, and number of pregnancies. Clinically the most common symptoms are sudden onset of abdominal pain, abdominal distention,

constipation and leukocytosis. Some studies have reported recurrent lower abdominal pain with nausea and vomiting and oral intolerance (4, 10, 12, 13). In our presented patient, abdominal pain, distension and constipation had been established a week prior to referral. Nausea and vomiting were also added to the patient's symptoms in the morning. During pregnancy due to the difficulty of diagnosis and delay in surgery, the rate of mortality due to obstruction is greatly increased. The best options for diagnosing volvulus are ultrasound and MRI. Using abdominal and pelvic X-ray will also be very helpful (11, 12).

In our patient, abdominal and pelvic X-ray showed dilated sigmoid as an inverted-U, characteristic of sigmoid volvulus, which prompted timely diagnosis and immediate laparotomy and prevented intestinal gangrene. A team of neonatologist, gynecologist and general surgeons performed the surgical procedure for treatment of the sigmoid volvulus. Although in early pregnancy, endoscopy is the preferred method to relieve bowel dilatation, in third trimester pregnancies, due to the large size of the uterus, there is a high risk of failure of this method and laparotomy is usually used. In the case of gangrene, the dead part of the intestine is removed and primary colostomy or anastomosis is used. In the absence of gangrene, rotation is opened without removing part of the intestine (13-15).

In our patient, due to timely diagnosis and immediate laparotomy, sigmoid was completely healthy and after opening the rotation to prevent recurrence, it was fixed via mesentery to the pelvic wall. The prognosis of sigmoid volvulus is very poor with a 6-12% of maternal mortality and a 20-26% of fetal mortality (15). However, our patient was discharged 4 days after surgery in good general condition and her baby was born at 38 weeks gestation by natural vaginal delivery.

4- CONCLUSION

Sigmoid volvulus during pregnancy is a rare complication. It is generally seen in multiparous women and in the third trimester. Timely diagnosis will prevent intestinal gangrene and reduce maternal and fetal mortality.

5- CONFLICT OF INTEREST: None.

6- REFERENCES

1. Atamanalp SS , Kisaoglu A, Disci E, Kantarci M, Ozogul B, et al. sigmoid Volvulus Complicating Pregnancy: A Case Report .Eurasian J Med.2015;47:75-6.
2. Raveenthiran V, Madiba TE, Atamanalp SS, De U.Volvulus of the sigmoid colon sigmoid.Colorectal Dis .2010; 12: e1-e17.
3. Orish V, Coomson E, Fanyi E, Onyeabor O, Sanyaolu A, et al. Gangrenous Gut in apregnant woman:A Case Report. AJMAH .2017; 5:1-5.
4. Chuanqing Wu, Xiaojie Zhu, Weizhen Liu, Tuo Ruan, Kaixiong Tao. Sigmoid volvulus during late pregnancy: a case report and literature review. Int J Clin Exp Med 2017; 10(12):16733-738.
5. Ramalingam R, Pradiba S, Michael A. A rare case of sigmoid volvulus complicating pregnancy in a Tertiary care centre: a case report. IJRCOG. 2016; 13(1):100-2.
6. Aftab Z, Toro A, Abdelaal A, Dasovsky M, Gehani S, Abdel Mola A, et al. Endoscopic reduction of a volvulus of the sigmoid colon in pregnancy: case report and a comprehensive review of the literature.World J Emerg Surg. 2014; 9: 41.
7. Al-Rshoud F, ALdeen E, Kilani R. Sigmoid colon volvulus immediately after ultrasound-guided simple ovarian cyst aspiration: a case report. Middle East Fertility Society Journal. 2017; 22(1):84-8.
8. Halabi WJ, Jafari MD, Kang CY, Nguyen VQ, Carmichael JC, et al. Colonic volvulus in the United States: trends, outcomes, and predictors of mortality. Ann Surg. 2014; 259(2):293-301.
9. Bharti Saxena, Sanjay Kharoliwal, Neeraj K. Dewanda, Rajendra Kumar Tanwar. "Sigmoid Volvulus with Pregnancy: A Case Report". Journal of Evolution of Medical and Dental Sciences 2015; 4 (Issue 24): 4225-28.
10. Serafeimidis C, Waqainabete I, Creaton A, Vakamacawai E, Kumar R. Sigmoid volvulus in pregnancy: case report and review of literature. Clin Case Rep. 2016;4(8):759.
11. Al Maksoud AM, Barsoum AK, Moneer MM. Sigmoid volvulus during pregnancy: A rare non-obstetric complication. Report of a case and review of the literature. Int J Surg Case Rep. 2015; 17: 61–4.
12. Palmucci S ,Lanza ML ,Gulino F , Scilletta B ,Ettorre GC. Diagnosis of a sigmoid volvulus in pregnancy: ultrasonography and magnetic resonance imaging findings. J Radiol Case Rep. 2014; 8(2):54-62.
13. Khan MR ,Ur Rehman S. Sigmoid volvulus in pregnancy and puerperium: a surgical and obstetric catastrophe. Report of a case and review of the world literature. World J Emerg Surg. 2012; 7(1):10.
14. Ward KE ,Blake E ,Gonzalez E , Pieracci F ,Alston M. Sigmoid Volvulus Complicating Postpartum Period. Case Rep Obstet Gynecol. 2017; 2017: 9034925.
15. Iida T, Nakagaki S, Satoh S, Shimizu H , Kaneto H. Clinical outcomes of sigmoid colon volvulus: identification of the factors associated with successful endoscopic detorsion. Intest Res. 2017; 15(2): 215-220.