

## Isolated Chronic Osteomyelitis of Fibula in a Child: A Case Report

Amir Ahmadzadeh Amiri<sup>1</sup>, Payman Sadeghi<sup>1</sup>, Mohsen Jafari<sup>2</sup>, \*Mahdieh Mousavi Torshizi<sup>1</sup>

<sup>1</sup>Department of Pediatric Rheumatology, Bahrami Children's Hospital, Tehran University of Medical Sciences, Tehran, Iran.

<sup>2</sup>Department of Pediatric Infectious Diseases, Bahrami Children' Hospital, Tehran University of Medical Sciences, Tehran, Iran.

### Abstract

#### Background

The most common sites affected in pediatric osteomyelitis are long bones of lower extremities such as femur and tibia but isolated fibular osteomyelitis has rarely been reported in children. Here, we present a case of isolated chronic osteomyelitis of fibula in a 2.5-year-old girl. To our knowledge, this is the youngest patient reported with isolated chronic fibular osteomyelitis in literature.

#### Case Presentation

A 2.5-years-old Iraqi girl was referred to our center with pain and swelling of the right lower leg. Her vital signs were stable and she had partial weight bearing on her right foot. She had been partially treated for acute osteomyelitis 4 months before. She was diagnosed with isolated chronic osteomyelitis of the right fibula and undergone surgical debridement. There was no bacterial growth on blood and bone tissue cultures and the patient was empirically treated with IV cloxacillin and ceftriaxone, followed by oral clindamycin for at least 3 months. At a 6-month follow-up, she was symptom-free and showed complete recovery.

#### Conclusion

We present a rare case of isolated chronic fibular osteomyelitis in a child, emphasizing the importance of appropriate empiric antibiotic therapy compatible with the patient's age and suspected organism in case of negative cultures.

**Key Words:** Fibula, Pediatric; Osteomyelitis.

\*Please, cite this article as Ahmadzadeh Amiri A, Sadeghi P, Jafari M, Mousavi Torshizi M. Isolated Chronic Osteomyelitis of Fibula in a Child: A Case Report. Int J Pediatr 2020; 8(6): 11403-407. DOI: [10.22038/ijp.2020.45408.3726](https://doi.org/10.22038/ijp.2020.45408.3726)

---

#### \*Corresponding Author:

Mahdieh Mousavi Torshizi, Postal address: Bahrami Children Hospital, Shahid Kiai St., Damavand Ave., Tehran, Iran. Fax number: + 9821775688

Email: [mousavi1387@yahoo.com](mailto:mousavi1387@yahoo.com)

Received date: Dec.27, 2019; Accepted date: Feb.12, 2020

## 1- INTRODUCTION

Osteomyelitis, defined as an inflammation of bone or bone marrow primarily caused by pyogenic bacterial organisms, is a serious infection in children that requires prompt diagnosis and management (1). Most cases of pediatric osteomyelitis are of hematogenous origin; however, the organisms might also reach the bone via direct inoculation or contiguous spread from adjacent tissues (2). Chronologically, osteomyelitis can be classified as acute (duration of shorter than 2 weeks), subacute (duration of 2 weeks to 3 months), and chronic (duration of longer than 3 months) (3). The most common sites affected in pediatric osteomyelitis are long bones of lower extremities, including femur and tibia (2, 3) but isolated fibular osteomyelitis is much less commonly encountered in clinical practice and has rarely been reported in children (4, 5). In this paper, we present a case of isolated chronic osteomyelitis of fibula in a 2.5-year-old girl. To the best of our knowledge, this is the youngest patient reported with isolated chronic fibular osteomyelitis in literature.

## 2- CASE REPORTS

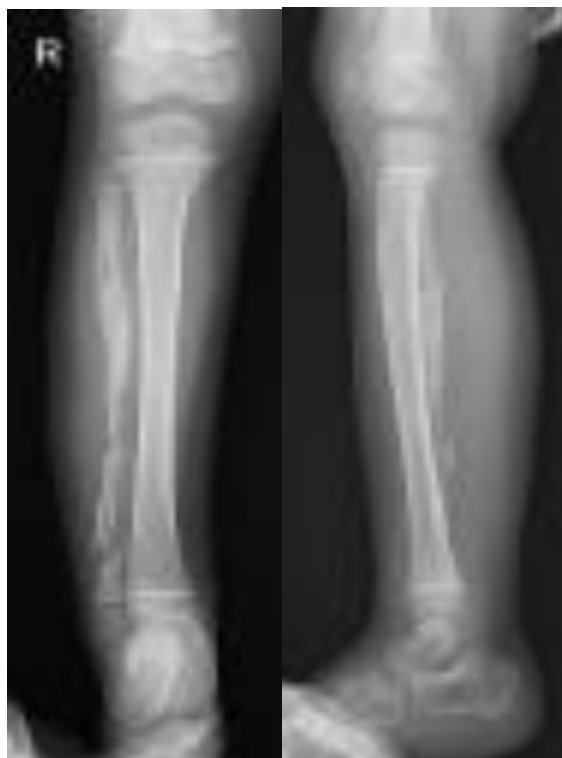A 2.5-year-old Iraqi girl presented to our outpatient clinic in the pediatric Rheumatology clinic in Bahrami Children's Hospital (Tehran) with the chief complaint of limping and pain and swelling of the right ankle and right lower leg. Her symptoms began about 4 months ago acutely with pain and tenderness in the right ankle and right lower leg alongside with fever with no history of trauma. She had been partially treated with intramuscular (IM) ceftriaxone and amikacin and had been undergone surgical abscess drainage with a possible diagnosis of osteomyelitis in Basra, Iraq. After 3 months, during which the patient experienced intermittent low-grade fever

and general malaise, the symptoms relapsed and she developed worsening pain and swelling of the right leg. She was then referred to Bahrami Pediatric Hospital, Tehran, Iran, and was admitted for further workup. On physical examination, the patient was afebrile and her vital signs were stable. She had partial weight bearing on her right foot. The lower third of the right leg and her ankle were swollen and erythematous and there was tenderness on palpation of the affected area. The active and passive ranges of motion and deep tendon reflexes of the ankle and knee joints were normal. There was no drainage sinus or pus discharge. Laboratory investigations showed a total leukocyte count (TLC) of  $10600/\text{mm}^3$  with 32% neutrophil and 58% lymphocyte, erythrocyte sedimentation rate (ESR) of 39 mm/hr, and negative C-reactive protein (CRP) titer. Blood culture was negative.

A plain radiograph of the involved limb showed excessive osteolysis of the fibular bone of right leg with marked periosteal reaction surrounding upper third of the bone and normal tibial texture and no signs of fracture (**Figure. 1**). Magnetic resonance imaging (MRI) showed cortical irregularity of entire fibula with irregular periosteal reaction and adjacent soft tissue swelling along with signs of involucrum in the upper third of right fibula, which are suggestive of chronic osteomyelitis of fibula. The tibial bone marrow signal was normal. Based on the patient's history of inadequately treated acute osteomyelitis and the results of the imagings mentioned above, the patient was diagnosed with chronic osteomyelitis of fibula; then, treatment with IV cloxacillin was initiated. After consulting the attending pediatric orthopedic surgeon and obtaining consent from her parents, the patient was scheduled for surgical debridement on two days after. On the second day of admission, the patient became febrile, and infectious diseases consultation was

requested. Intravenous (IV) ceftriaxone was added to the antibiotic regimen and Tuberculin Skin Test (TST) was performed as requested by the attending infectious diseases specialist, which

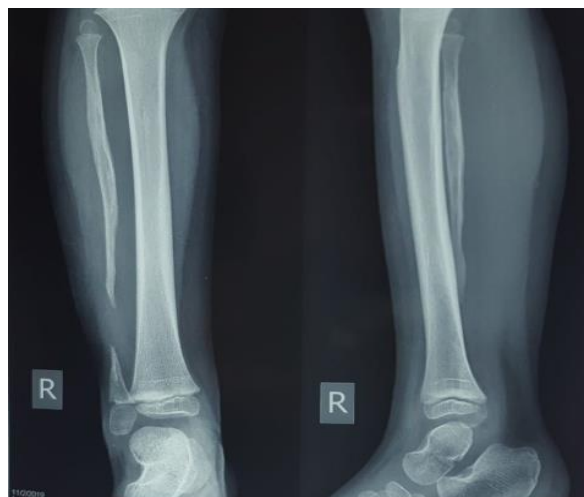
revealed negative results. During the next 24 h, the fever dropped and her signs and symptoms of inflammation decreased. However, the ESR level remained high (37 mm/hr).



**Fig.1.** X-ray of the right leg before medical treatment.

On day 3 of admission, the patient underwent surgical debridement and partial excision of the fibula. Bone tissue biopsy sent for histopathological examination showed chronic osteomyelitis with no evidence of malignancy and no bacterial growth after 48 h. Postoperatively, treatment with IV cloxacillin and ceftriaxone continued for two weeks until discharge. At the time of discharge, the patient was in good condition and was advised to continue antibiotic therapy with oral clindamycin for at least 3 months and to return for follow-up visits and laboratory investigations. The

patient returned for two follow-up visits at 3-month intervals. Three months after discharge, she was clinically asymptomatic and laboratory tests showed negative CRP titer, decreased ESR (15 mm/hr), and decreased total leukocyte count (TLC) (6000 with 61.9% Lymphocytes). At the 6-month follow-up visit, she showed complete recovery. The last X-ray showed segmental bony loss of lower fibula with thinning and spindling of the fibula, due to previous surgery with normal tibial texture and no signs of fracture (**Figure. 2**).



**Fig.3.** X-ray of the right leg six months after treatment.

### 3- DISCUSSION

Hematogenous osteomyelitis is seen more commonly in children than in adults, especially in those younger than 5 years of age (6). The incidence of acute osteomyelitis varies from 8-10 in 100,000 per year in developed countries but it is reported to be much higher in developing countries (3). In children, hematogenous osteomyelitis primarily affects the most vascularized regions of the growing skeleton; i.e., metaphyses of the long bones, but the metaphyseal equivalents of flat bones are also prone to osteomyelitis (7). Lower extremities are involved in 75% of pediatric cases, of which the most common sites are femur, tibia, pelvis, and feet (3). Chronic osteomyelitis can occur either primarily or following inadequate or partial treatment of acute osteomyelitis. This health problem is characterized by necrosis of the affected bone, which leads to the formation of sequestrae (avascular bony fragments) and involucrae (sequestrae and the surrounding periosteal reaction) (8). In this case, the patient developed chronic osteomyelitis following a partial treatment of the acute condition. Historically, the most common causative organism of pediatric hematogenous osteomyelitis is *Staphylococcus aureus*, followed by *Streptococcus pyogenes*,

*Streptococcus pneumoniae*, and *Haemophilus influenzae* (3, 9). During the past two decades, *Kingella kingae* has been commonly reported as the most common causative pathogen in young children, especially those between 6 months and 4 years of age (7). In the present case, blood culture was negative and the results of bone tissue culture revealed no growth after 48 h, which might be due to prior antibiotic therapy. Before admission to our center, our patient had treated for acute osteomyelitis with ceftriaxone and amikacin; none being diagnosed with *Staphylococcus aureus* infections. Mahmoudi et al. found no causative pathogens in 40% of cases of pediatric osteomyelitis. They emphasized the importance of empiric antimicrobial therapy as they used cloxacillin with a cephalosporin for culture-negative patients (10). Similarly, our patient received IV cloxacillin and ceftriaxone, which are respectively considered as the first-line treatment for *Staphylococcus aureus* and *Kingella kingae*. We observed a very desirable response to this antibiotic regimen. Although there is not a single definite suggested duration of antibiotic therapy for subacute osteomyelitis, the recommended duration of antibiotic therapy in review articles and notable

pediatric textbooks include an average of 2 weeks (range of 1-4 weeks) parenteral antibiotics followed by oral antibiotics. Oral administration of antibiotics and outpatient follow-ups can be initiated after having found normal CRP titers, and the oral antibiotic therapy can be continued for a full period of 3 to 6 weeks in total until the ESR level normalizes (11,12). The ESR and/or CRP level normalization period may be prolonged in patients with the need for surgical drainage or procedures (13). In the case of our patient, the ESR levels reached a normal level after about 6 months post-surgery.

#### 4- CONCLUSION

In conclusion, we present a case of isolated chronic fibular osteomyelitis in a 2.5- year- old child. Moreover, we highlight the importance of appropriate empiric antibiotic therapy compatible with the patient's age and suspected organism involved, as a necessity in the initiation of treatment before finding the responsible organism using the culture studies. In fact, in some cases, we might be able to continue the therapy after obtaining negative results in culture studies. We also emphasized the need for surgical drainage or debridement in cases of chronic osteomyelitis.

**5- CONFLICT OF INTEREST:** None.

#### 6- REFERENCES

1. Riise OR, Kirkhus E, Handeland KS, Handeland KS, Flatø B, Reiser T, et al. Childhood osteomyelitis-incidence and differentiation from other acute onset musculoskeletal features in a population-based study. *BMC Pediatr.* 2008;8:45.
2. Castellazzi L, Mantero M, Esposito S. Update on the management of pediatric acute osteomyelitis and septic arthritis. *Int J Mol Sci.* 2016;17(6):855.
3. Castellazzi L, Mantero M, Esposito S. Update on the management of pediatric acute osteomyelitis and septic arthritis. *Int J Mol Sci.* 2016;17(6):855.
4. Peltola H, Pääkkönen M. Acute Osteomyelitis in Children. *N Engl J Med.* 2014; 370: 352-60.
5. Singh J, Kalia A, Virk J. Isolated chronic osteomyelitis of fibula in a child: A case report and review of literature. *Int J Orthop Sci.* 2017;3(4):923-26.
6. Varun V, Naveen S, Anuj R, Gaurav K, Shilpi S, Vikas V. Osteomyelitis of Fibula in a Child: A Rare Case Report with a Huge Sequestrum. *Sch. Acad. J. Biosci.* 2015; 3(6): 563-66.
7. Frank G, Mahoney HM, Eppes SC. Musculoskeletal infections in children. *Pediatr Clin North Am* 2005; 52(4):1083–1106, ix. doi: 10.1016/j.pcl.2005.04.003.
8. Jaramillo D, Dormans JP, Delgado J, Laor T, St. Geme III JW. Hematogenous osteomyelitis in infants and Children: Imaging of a Changing Disease. *Radiology* 2017; 283(3):629-643.
9. Auh JS, Binns HJ, Katz BZ. Retrospective Assessment of Subacute or Chronic Osteomyelitis in Children and Young Adults. *Clin Pediatr.* 2004;43(6):549-555.
10. Street M, Puna R, Huang M, Crawford H. Acute hematogenous osteomyelitis in children. *J Pediatr Orthop.* 2015; 35(6):634-9.
11. Mahmoudi S, Pourakbari B, Borhani K, Khodabandeh M, Keshavarz Valian S, Aziz Ahari A, et al. Acute osteomyelitis and septic arthritis in children: A referral hospital-based study in Iran. *Wien Med Wochenschr.* 2017; 167(11-12):259-263.
12. Harik NS, Smeltzer MS. Management of acute osteomyelitis in children. *Expert Rev Anti-Infect Ther.* 2010; 8(2):175–181.
13. Agarwal A, Agarwal AN. Bone and Joint Infections in Children: Acute Hematogenous Osteomyelitis. *Indian J Pediatr.* 2016; 83(8):817-24.
14. Khachatourians AG, Patzakis MJ, Roidis N, Holtom PD. Laboratory monitoring in pediatric acute osteomyelitis and septic arthritis. *Clin Orthop.* 2003;409:186-94.