

Foreign Body Ingestion and Aspiration in Iranian Children: Experience of 369 Cases in a Pediatric Unit

Roya Oboodi¹, Mozghan Moghtaderi¹, Leila Salarian², Mahsa Agahi¹

¹Neonatal Research Center, Shiraz University of Medical Sciences, Shiraz, Iran.

²Pediatric Department, Shiraz University of Medical Sciences, Shiraz, Iran.

Abstract

Background

The spectrum of foreign bodies is various based on specific environment and eating habits in each area. This study was designed to identify the type of foreign bodies, associated symptoms and management of children with ingestion or aspiration of objects.

Materials and Methods

This descriptive retrospective study reviewed the medical charts of all children under 18 years of age with suspected foreign body aspiration or ingestion who were admitted to Namazee Hospital affiliated to Shiraz University of Medical Sciences over a 5-year period from 2013 to 2018. The data recorded in the checklists were analyzed using SPSS software version 22.0.

Results

Over the five-year study period, 369 children in the age range of 28 days to 18 years with FB ingestion or aspiration were included in this study. Of 264 patients (43.9% girls, 56.1% boys) with a mean age of 3.73 ± 3.30 years who had referred with foreign body ingestion, an identifiable object was recognized in 245 (92.8%) patients. The most common ingested object was coin (40.9%) followed by disc batteries (15.9%). Foreign bodies had been aspirated in 105 patients (32% girls, 68% boys) with a mean age of 3.1 ± 2.8 years. The majority of the aspirated objects were seeds (28.6%).

Conclusion

This study showed the most common ingested FBs were coin and is more commonly located in the esophagus; however, the common aspirated FBs were seeds and lodged preferentially in the right bronchial tree.

Key Words: Aspiration, Bronchoscopy, Children, Endoscopy, Foreign body, Ingestion.

*Please cite this article as: Oboodi R, Moghtaderi M, Salarian L, Agahi M. Foreign Body Ingestion and Aspiration in Iranian Children: Experience of 369 Cases in a Pediatric Unit. *Int J Pediatr* 2019; 7(6): 9567-76. DOI: [10.22038/ijp.2019.39254.3343](https://doi.org/10.22038/ijp.2019.39254.3343)

*Corresponding Author:

Mozghan Moghtaderi, Neonatal Research Center, Shiraz University of Medical Sciences, Zand St., 71348-45794, Shiraz, Iran. Tel/Fax: +98 71 36122218

Email: Moghtadery@sums.ac.ir

Received date: Feb.03, 2019; Accepted date: Mar 22, 2019

1- INTRODUCTION

Aspiration and ingestion of foreign body (FB) are a life-threatening emergency which predominantly occurs in children aged 6 months to 3 years. In this age, children habitually tend to place small objects in their mouth and nose to explore the surrounding environment; they lack teeth for grinding up food into small pieces for swallowing, tend to perform playing whilst eating, and do not have the cognitive capacity to distinguish between eatable and non-eatable objects (1-4). Most swallowed FBs have been coins in the USA; however, the ingestion of button batteries has long been recognized as a potential threat to children's health (5, 6). The Susy Safe project found food objects including the bones, nuts and seeds represented 26% of the cases and non-food objects including pearls, balls, marbles, coin and toys were the remaining 74% (7).

The aspirated objects are often small, round objects such as nuts, candy, popcorn and beans as well as small parts of toys (8). Ingestion of FB may be totally asymptomatic or accompanied by choking, dysphagia, emesis, and melena (9). Initial events after aspiration of solid or semisolid object into the airway are violent paroxysm of coughing, choking and gagging; moreover, large size FB can lead to complete obstruction of the airway, asphyxia and rapid death (10-12). History is the most important factor in determining FB ingestion; all children with a history of FB ingestion should be evaluated with radiographs of the neck, chest, and abdomen. Radiolucent objects require direct visualization or contrast radiographs (9, 13). Diagnosis of FB aspiration needs detailed history and examination of the breathing sounds. In a patient with high suspicion to aspiration, bronchoscopy is carried out promptly if imaging studies are negative (14). Airway FB will be removed by bronchoscopy on the same day of diagnosis and ingested FB by non-urgent

or emergency endoscopy. There are geographical differences in the spectrum of objects and diets commonly found in different regions; this variation can affect the type and frequency of the ingested or aspirated objects. Despite the clinical significance of FBs, there are no published reports on ingested and aspirated FBs in children in our region. This study was designed to identify the spectrum of FBs, associated symptoms and management of children with ingestion or aspiration of objects in Shiraz city, Southwestern Iran.

2- MATERIALS AND METHODS

2-1. Method

This descriptive retrospective study over a period of 5 years (2013–2018) included medical charts of all children under 18 years of age with suspected FB aspiration or ingestion who were admitted in Nemazee Hospital. Nemazee Hospital affiliated to Shiraz University of Medical Sciences is the first and largest teaching hospital in Southwestern Iran, and it serves as the only subspecialty center for bronchoscopy and endoscopy of young children in the region. Required data of 377 files of children with suspected FB problem was reviewed by referring to the hospital archive and studying medical records. Individuals older than 18 years of age and cases with incomplete records were excluded. The total data of 369 patients was included in the study and they were categorized into two groups according to the ingested or aspirated FBs. Baseline characteristics including gender, age, presenting complaint, physical examination, type and location of the FB, radiological findings, duration of hospitalization from admission to discharge, and complications were obtained by reviewing the medical records. Information about bronchoscopy findings and endoscopy results in the course of treatment was collected by medical files according to the designed checklist.

2-2. Ethics

The study protocol was approved by the Ethics Committee of the university (IR.SUMS.MED.REC.1394.s05). Also, data was reported in general without mentioning the name.

2-3. Statistical analysis

Data analyses were performed using SPSS version 22.0 (SPSS Inc., Chicago, IL, USA), and $p \leq 0.05$ was considered statistically significant. The clinical and laboratory characteristics were analyzed by descriptive statistics; results were reported as mean \pm standard deviation (SD) for the quantitative variables. Chi-squared test

was used to determine whether there is a statistically significant correlation between the type of FBs and occurrence of complication of the medical procedure.

3- RESULTS

Over the five-year study period, 369 children (boys 215, girls 154) in the age range of 28 days to 18 years (mean age of 3.61 ± 3.21 years) with FB ingestion or aspiration were included in this study. Among them, 264 (71.5%) showed FB ingestion and 105 (28.5%) FB aspiration. The age distribution and gender of patients with FB problem who had referred to the hospital is summarized in **Figure.1**.

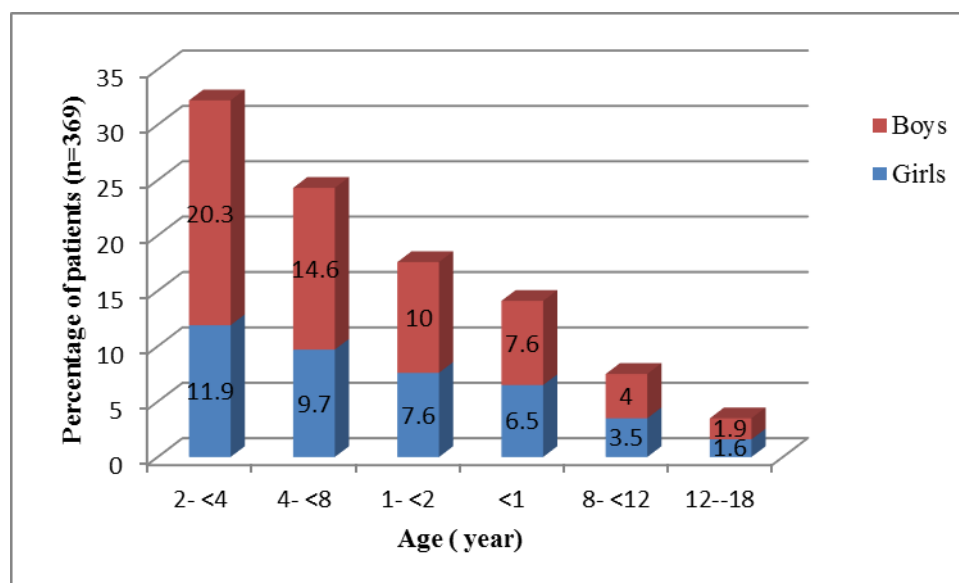


Fig.1: Comparison of the percentage of children with foreign body ingestion or aspiration in different ages according to gender.

3-1. Patients with FB ingestion

Of 264/369 patients who referred with FB ingestion, an identifiable object was recognized in 245 (92.8%) patients. Among them, 116 were girls (43.9%). The mean age of the children suffering from ingestion was 3.73 ± 3.30 years, ranging from 36 days to 17 years. One hundred and fifty (56.8%) out of 264 children were ≤ 2 years old. The presenting complaints of 264 patients who ingested FB have been shown in **Figure 2**. Physical examination

of these patients showed no abnormality in 242(91.6%), the other findings were drooling in 12 (4.6%), abdominal tenderness in 9 (3.4 %), and harsh breathing sound in 1(0.4%). There were data on radiological investigation in 111 (42%) patients with ingested FB. Location of FB presented on the upper gastrointestinal tract in 88 out of 111 (79.3%) patients: two in the pharynx, 60 in the upper one-third of the esophagus, one in the mid-part of the esophagus, 12 in the lower esophagus, and 13 in the stomach. In

14 (12.6%) children, the FB was in the intestine, 7 in the colon, and 7 in the small intestine. Nine (8.1%) children had no identifiable FB on radiologic investigations. The most common ingested FB was coin (40.9%) followed by disc batteries (15.9%). The mean age of the children with ingested coin or disc battery was 4 ± 1.1 years and 2.4 ± 0.9 years, respectively. The frequency and type of the ingested FBs are shown among Iranian patients in **Table.1**. The elapsed time

between the ingested FB and hospital referral was from one hour to 720 days with a mean of 5 ± 0.7 days. Endoscopic examination using general anesthesia was performed in 231 studied children with ingested FB and colonoscopy was not required. The most common site for FB was the esophagus (113 patients) followed by the stomach (35 patients). About 21% of the ingested FB passed spontaneously through the bowels.

Table-1: Frequency and type of ingested foreign bodies in the studied patients (245/264)

Type of foreign body	Number of patients	Percentage
Coin	108	40.9
Battery	42	15.9
Pin	13	4.9
Spike	11	4.2
Piece of toy	8	3
Chicken bone	7	2.7
Tresses	7	2.7
Piece of metal	7	2.7
Pin/ clip	6	2.3
Food particles	5	1.9
Button	5	1.9
Earrings	4	1.5
Stem of thyme	3	1.1
Needle	3	1.1
Pistachio	2	0.8
Glass	2	0.8
Peanut	2	0.8
Stone	2	0.8
Piece of fruit	2	0.8
Raisin	2	0.8
Seeds	2	0.8
Head of pen	1	0.4
Flash memory	1	0.4
Total	245	92.8

Table.2 shows the location of the ingested FB by endoscopy. The anatomical location of the FB revealed different frequencies based on radiological findings and endoscopy results; movement of the FB through the gastrointestinal system and missing cases should be considered. The mean duration of hospitalization in

patients with FB ingestion was 2.1 ± 1.1 days (ranged from 1 to 16 days). Twenty-seven (10.2%) children developed complication after ingesting FB, statistical analysis showed no relationship between the type of ingested FB and their complications (**Table.3**).

Table-2: Anatomic region of the ingested foreign body by endoscopy (231/264)

Location of foreign body with endoscopy	Number of patients	Percentage
Oropharynx	16	6.9
Esophagus	113	48.8
Duodenum	18	7.7
Stomach	35	15.5
No identifiable object	49	21.1
Total	231	100

Table-3: The complications in 264 children with FBs ingestion and correlation with type of FBs

Complication after ingestion of FBs	Number	Percentage	P- value*
Esophageal necrosis and fibrosis	14	5.3	1
Erosion and hemorrhage of the stomach	5	1.9	1
Required laparotomy (due to significant injury)	8	3	0.7

P value* between complication and type of ingested FBs. FB: foreign body.

3-2. Patients with FB aspiration

One hundred and five patients with FB aspiration with an age range of 28 days to 15 years (mean age 3.1 ± 2.8 years) were studied. These comprised 71(68%) boys with a boy-to-girl ratio of 2:1. Approximately 70% of the FB aspirations occurred within the first three years of life. FB was removed successfully in 82 (78.1%) of these patients, but the remaining patients (22; 20.9%) had no identifiable FB and one patient (1%) referred with respiratory arrest. Patients referred with a combination of symptoms.

Presenting clinical features of the patients with FB aspiration were cough and stridor in 84 (80%), choking in 51 (48.5%), cyanosis in 24 (22.9%), dyspnea in 14 (13.3%), nausea in 10 (9.5%), fever in 4 (3.8%), tachypnea in 3 (2.9%), repeated respiratory infection in 3 (2.9%), and irritability in 2 (1.9%). Drooling, abdominal pain and respiratory arrest were each present in one patient. Wheezing was found in one-third of these patients; the other signs of physical examination are represented in **Table.4**.

Table-4: Frequency and type of clinical signs in 103 patients with foreign body aspiration

Clinical signs	Number	Percentage
No abnormal findings	25	28.8
Wheezing	35	33.3
Decreased breathing sound	16	15.2
Respiratory distress	9	8.6
Abdominal tenderness	3	1.1
Harsh breathing sounds	9	8.6
Fever	2	1.9

There was incomplete registry information of X-ray results in the medical files. Radiological findings of the chest were only recorded in 10 patients with FB aspiration, 5 (4.8%) of whom had normal chest X-ray, 2 (1.9%) with right lung collapse, 2 (1.9%) with lung hyperinflation, and 1(1%) with lobar consolidation. The most common aspirated FBs were seen in 30 (28.6%) patients, peanut in 14 (13.3%), and food particles in 9 (8.6%). Almond in 6 (4.8%), rice in 4 (3.8%), fish bone in 4 (3.8%), piece of toy in 2 (1.9%) were the other aspirated FBs. There was one case for each FB: pistachio, coin, pin, spike, blade, tooth, blood sucker, and hair, piece of metal, needle, pill, pen cap, and raisin. In the case of foreign body aspiration, one case passed away due to pill. The elapsed time between the

accidental ingestion of FB and hospital referral ranged from one hour to 360 days with median of 2 days. Bronchoscopy was performed in 102 patients suspected with FB aspiration, one child passed away with respiratory arrest before bronchoscopy and two children coughed out the FB in the emergency room before bronchoscopy. The location of FBs following bronchoscopy is shown in **Figure.3**. The mean duration of hospitalization in patients with FB aspiration ranged from < 1 day to 14 days (mean 2 ± 1.6 days). Complications related to FB aspiration were detected in 30 (30.6%) of the patients, statistical analysis showed no relationship between the type of aspirated FB and their mentioned complications (**Table.5**).

Table-5: The complications in 103 children with FBs ingestion and correlation with types of FBs

Complication after aspiration of FBs	Number	Percentage	P- value*
Inflammation and granulation of the respiratory tract	25	24.2	0.09
Stenosis of the airways	3	2.9	1
Respiratory infections	2	1.9	0.8

P value* between complication and types of ingested FBs. FB: foreign body.

4- DISCUSSION

Ingestion and aspiration of FBs are common clinical problems for children presenting to emergency room (15). From our review, the peak incidence of FB ingestion and aspiration in 369 children was between 2 years to younger than 4 years. The mean age of children with FB ingestion was 3.7 ± 3.3 years in this study, similar to other reports in the literature; however, it was 5.7 years in 64 Turkish children who ingested FBs (15). In the present study, the incidence of FB ingestion was higher in boys than in girls; however, there was no statistically significant difference. Previous reports indicated that the first three years of life was mainly a risk for FB aspiration (17, 18); this study showed that the first three

years of life were the predominant age (70%) for FB aspiration. FB aspiration was more common in boys than girls (ratio of 2:1); this is similar to other studies on this problem by Saki et al. and Hadadi et al. (19, 20). This probably suggests that Iranian boys' personalities are more adventurous and playful compared to girls. The most prevalent clinical symptoms were drooling in 18.2%, nausea and vomiting in 16.6%, and dysphagia in 7.6% in our patients with FB ingestion. The frequency of these symptoms was different from that of a Turkish study showing drooling in 2.3%, vomiting in 3.5%, and dysphagia in 24.3% (16). The low rate of dysphagia in our study can be explained by younger age of patients who were not able to articulate their problem. Choking

attacks and coughing in a child while eating food or playing with toys are the most prevalent clinical symptoms in FB aspiration; this is similar to our study (21). In the present study, 91.6% of the patients with FB ingestion, and 25(28.8%) children with aspirated FB showed no abnormality in physical examination. The rate of no abnormal findings for FB ingestion was very high; it can be explained by lack of enough attention to filling the patients' medical chart by the physician. Drooling (4.6%) was a common finding for FB ingestion in our study; however, Dereci et al. found the rate of 2.3% for drooling of their patients (16). Wheezing and decreased breathing sound were two main findings on physical examination of patients with FB aspiration; this is consistent with the literature discussed in scientific texts (22, 23).

Ingested FBs were diagnosed in 102 (38.6%) by chest and abdominal radiography, while this rate was 245 (92.8%) by endoscopy; this difference depends on the type of FB which is non-opaque with no specific radiographic findings. Radiographic examination prior to bronchoscopy or endoscopy for FB localization in patients with a history of radiopaque FB can be helpful. It should be noted that most foreign bodies are radiolucent (24). Only 10 patients with FB aspiration had chest X-ray results, 5 of whom had no evidence of abnormal finding. The rate of normal chest X-ray was reported to be 19 to 25% in different studies in other areas (22, 25), and 32% among 1,114 Iranian patients with FB aspiration (26). The spectrum of the type of ingested or aspirated FB varies from region to region based on the diet and habits of people. In approximately fifty percent of children with FB ingestion, coins (40.9%), and electrical battery (15.9%) were removed. The rate of ingestion of coin in 1,256 children in China was 47% (27). In recent years,

ingestion of batteries by children has become more frequent due to more accessibility of electronic toys and devices in children (28). The esophagus was the most frequent location of these FBs, which is in agreement with the majority of the classical literature (28-30). Our study found the elapsed mean time between the accidental ingestion and aspiration of FB with hospital referral was 5 days and 2 days, respectively. The most common aspirated FBs were removed from the right main bronchus where FBs are found frequently to be seed and peanut. The classical literature shows that FB aspiration is predominant in the right bronchial tree (31, 32); however, a few studies show that aspirated FBs are more common in the left main bronchus (33). Seeds were the most common aspirated

FBs in our patients; this finding is consistent with Haddadi et al. and Farzizadeh et al.'s studies in this area (20, 23), breaking of seeds into smaller pieces and eating them is a social tradition, which is often seen in family gatherings. Twenty percent of the ingested FBs left the body spontaneously after passing the gastrointestinal tract. Endoscopy has assumed a significant role in the management of ingested FBs. Endoscopy showed FBs were most commonly located in the esophagus (48.8%) followed by the stomach (15.5 %). Dereci et al. (16) in 64 Turkish children who ingested FB found that the esophagus (53%), and stomach (15.6%) were the first two locations, which is similar to our study. Following diagnosis of FB aspiration, immediate bronchoscopy is necessary because it reduces the risk of complications. In our study, bronchoscopy was done in 102 cases of suspected FB aspiration without mortality and need of thoracotomy. No FB was in bronchoscopy of 21.6% patients in this study. Negative bronchoscopy in the study by Malek et al. was 14.2%; in Hadadi et al.'s research it was 28.2%, and

in Jose et al.'s study it was <10% (18, 20, 34). It is important if physicians doubt whether or not they should search for aspirated FB by doing bronchoscopy for certain diagnosis of lack or presence of FB in the tracheobronchial tract. Bleeding, edema and laryngospasm, bronchial spasms, and asphyxia are among the complications caused by bronchoscopy (35). We observed 30 patients with complications related to bronchoscopy following FB aspiration, including inflammation and granulation of respiratory tract, stenosis of airways as well as respiratory infections, respectively.

About ten percent of our children developed complication after ingesting FB, 5% esophageal necrosis and fibrosis, 2% erosion and hemorrhage of the stomach, and 3% required laparotomy due to significant injury. Iqbal et al. reported the complications of pediatric endoscopy in 9,308 procedures resulting esophageal bleeding in 2 (0.02%), esophageal mucosal tears in 2 (0.02%), as well as perforation in esophagus and duodenum in 2 (0.02%) (25). The risk of endoscopy complication is probably increased if the procedure is done for removing the sharp object and disk batteries; therefore, endoscopic removal of FBs was not a very safe method in our review experience. The hospitalization period of patients admitted for FB ingestion was the same as that of patients with FB aspiration (about 2 days).

4-1. Limitations of the study

This study was a retrospective study in which the only way for the authors to perform the study was to use the data from the medical health records. Therefore, incorrect or incomplete records could impact on proper data.

5- CONCLUSION

FB ingestion and aspiration should be suspected in children, predominantly in boys from 2 to 4 years of life. The most

common ingested and aspirated FBs were coin and seeds, respectively. The ingested FBs are more commonly located in the esophagus and the aspirated FBs lodged preferentially in the right bronchial tree. This study showed the risk of complication after accidental ingestion or aspiration of FBs was about 10% and 30% in children, respectively.

6- CONFLICT OF INTEREST: None.

7- ACKNOWLEDGEMENT

This work was performed in partial fulfillment of the requirements for the degree of Doctor of Medicine in Pediatric Department (Mahsa Agahi), and was supported by grants from Shiraz University of Medical Sciences (No: 9401-019162). The authors would like to thank Shiraz University of Medical Sciences, Shiraz, Iran and also Center for Development of Clinical Research of Nemazee Hospital and Dr. Nasrin Shokrpour for her editorial assistance.

8- REFERENCES

1. Green SS. Ingested and Aspirated Foreign Bodies. *Pediatr Rev.* 2015; 36(10):430-6.
2. Blanco-Rodríguez G, Teyssier-Morales G, Penchyna-Grub J, Madriñan-Rivas JE, Rivas-Rivera IA, Trujillo-Ponce de León A, et al. Characteristics and results of the ingestion of foreign bodies in children. *Arch Argent Pediatr.* 2018; 1; 116 (4): 256-61.
2. Jayachandra S, Eslick GD. A systematic review of paediatric foreign body ingestion: presentation, complications, and management. *Int J Pediatr Otorhinolaryngol.* 2013; 77(3):311-7.
3. Arana A, Hauser B, Hachimi-Idrissi S, Vandenplas Y. Management of ingested foreign bodies in childhood and review of the literature. *Eur J Pediatr.* 2001; 160(8):468-72.
4. Chen X, Milkovich S, Stool D, van As AB, Reilly J, Rider G. Pediatric coin ingestion

- and aspiration. *Int J Pediatr Otorhinolaryngol.* 2006; 70: 325–9.
5. Kodituwakku R, Palmer S, Paul SP. Management of foreign body ingestions in children: button batteries and magnets. *Br J Nurs.* 2017; 27; 26 (8):456-61.
 6. Gregori D. The Susy Safe Project. A web-based registry of foreign bodies injuries in children. *Int J Pediatr Otorhinolaryngol.* 2006; 70 (9):1663-64.
 7. Swanson KL, Edell ES. Tracheobronchial foreign bodies. *Chest Surg Clin N Am.* 2001; 11 (4):861-72.
 8. Jayachandra S, Eslick GD. A systematic review of paediatric foreign body ingestion: presentation, complications, and management. *Int J Pediatr Otorhinolaryngol.* 2013; 77(3):311-7.
 9. Foltran F, Ballali S, Rodriguez H, Sebastian van As AB, Passali D, Gulati A, et al. Inhaled foreign bodies in children: a global perspective on their epidemiological, clinical, and preventive aspects. *Pediatr. Pulmonol.* 2013; 48(4):344-51.
 10. Even L, Heno N, Talmon Y, Samet E, Zonis Z, Kugelman A.. Diagnostic evaluation of foreign body aspiration in children: a prospective study. *J. Pediatr. Surg.* 2005; 40(7):1122-27.
 11. Eren S, Balci AE, Dikici B, Doblan M, Eren MN. Foreign body aspiration in children: experience of 1160 cases. *Ann Trop Paediatr.* 2003; 23(1):31-7.
 12. Sink JR, Kitsko DJ, Mehta DK, Georg MW, Simons JP. Diagnosis of Pediatric Foreign Body Ingestion: Clinical Presentation, Physical Examination, and Radiologic Findings. *Ann Otol Rhinol Laryngol.* 2016; 125(4):342-50.
 13. Skoulakis CE, Doxas PG, Papadakis CE, Proimos E, Christodoulou P, Bizakis JG, et al. Bronchoscopy for foreign body removal in children. A review and analysis of 210 cases. *Int J Pediatr Otorhinolaryngol.* 2000 30; 53(2):143-8.
 15. Majola NF, Kong VY, Mangray H, Govindasamy V, Laing GL, Clarke DL. An audit of ingested and aspirated foreign bodies in children at a university hospital in South Africa: The Pietermaritzburg experience. *S Afr Med J.* 2018; 27; 108(3):205-9.
 16. Dereci S, Koca T, Serdaroğlu F, Akçam M. Foreign body ingestion in children. *Turk Pediatri Ars.* 2015; 50(4):234-40.
 17. Pugmire BS, Lim R, Avery LL. Review of Ingested and Aspirated Foreign Bodies in Children and Their Clinical Significance for Radiologists. *Radiographics.* 2015; 35(5):1528-38.
 18. Mallick MS, Khan AR, Al-Bassam A. Late Presentation of Tracheobronchial Foreign Body Aspiration in Children. *J Trop Pediatr* 2005; 51(3):145–8.
 19. Saki N, Nikakhlagh S, Rahim F, Abshirini H. Foreign body aspirations in infancy: a 20-year experience. *Int J Med Sci.* 2009 14; 6(6): 322-8.
 20. Haddadi S, Marzban S, Nemati S, Ranjbar Kiakelayeh S, Parvizi A, Heidarzadeh A. Tracheobronchial Foreign-Bodies in Children; A 7 Year Retrospective Study. *Iran J Otorhinolaryngol.* 2015; 27(82):377-85.
 21. Jose A, Cataneo M, Cataneo DC, Ruiz Jr RL. Management of tracheobronchial foreign body in children. *Pediatr Surg Int* 2008; 24(2):151-6.
 22. Sirmali M, Türüt H, Kısacık E, Fındık G, Kaya S, Tastepe I. The Relationship between Time of Admittance and Complications in Paediatric Tracheobronchial Foreign Body Aspiration. *Acta Chir Bel* 2005; 105(6): 631-4.
 23. Farzizadeh M, Hashemian H, AtrKarRoshan Z. Clinical and radiographic findings of foreign body aspiration in children hospitalized in 17 Shahriyar Hospital, Rasht, during 1996–2008. *Feiz Journal* 2013; 7(5): 495–500.
 24. Dikensoy O, Usalan C, Filiz A. Foreign body aspiration: clinical utility of flexible Bronchoscopy. *Postgrad Med J* 2002; 78(921): 399-403.
 25. Iqbal CW, Askegard-Giesmann JR, Pham TH, Ishitani MB, Moir CR. Pediatric endoscopic injuries: incidence, management, and outcomes. *J Pediatr Surg.* 2008; 43(5): 911-5.

26. Saki N, Nikakhlagh S, Heshmati SM. 25-Year Review of the Abundance and Diversity of Radiopaque Airway Foreign Bodies in Children. *Indian J Otolaryngol Head Neck Surg.* 2015; 67(3): 261-6.
27. Uçan ES, Tahaoglu K, Mogolkoc N, Dereli S, Basozdemir N, Basok O, et al.
29. Amanatidou V, Sofidiotou V, Fountas K, et al. Button battery ingestion: the Greek experience and review of the literature. *Pediatr Emerg Care.* 2011; 27(3):186-8.
30. Yardeni D, Yardeni H, Coran AG, Golladay ES. Severe esophageal damage due to button battery ingestion: can it be prevented? *Pediatr Surg Int.* 2004; 20(7):496-501.
31. Green SS. Ingested and Aspirated Foreign Bodies. *Pediatr Rev.* 2015; 36(10):430-6.
32. Naragund AI, Mudhol RS, Harugop AS, Patil PH, Hajare PS, Metgudmath VV. Tracheo-bronchial foreign body aspiration in children: a one year descriptive study. *Indian J Turban pin aspiration syndrome: a new form of foreign body aspiration. Respir Med* 1996; 90: 427-8.
28. Marom T, Goldfarb A, Russo E, Roth Y. Battery ingestion in children. *Int J Pediatr Otorhinolaryngol.* 2010; 74(8): 849-54.
- Otolaryngol Head Neck Surg. 2014; 66(Suppl 1):180-5.
33. Sahadan DZ, Zainudin NM, Kassim A, Zahari Z, Mahadzir M, Daud CZ, et al. Case series of foreign body aspiration in Paediatric Institute, Hospital Kuala Lumpur. *Med J Malaysia.* 2011; 66(5):484-6.
34. Jose A, Cataneo M, Cataneo DC, Ruiz Jr RL. Management of tracheobronchial foreign body in children. *Pediatr Surg Int* 2008; 24(2):151-6.
35. Hasdiraz L, Oguzkaya F, Bilgin M. Complications of bronchoscopy for foreign body removal: experience in 1035 cases. *Ann Saudi Med* 2006; 26(4):283-7.