

Diagnostic Accuracy of Acute Appendicitis by Ultrasound in Hospital Emergency

*Mohammad Ghasem Hanafi¹, Afshin Shiri²

¹Department of Radiology, Ahvaz Jundishapur University of Medical Sciences, Ahvaz, Iran.

²General Physician, School of Medicine, Student Research Committee, Ahvaz Jundishapur University of Medical Sciences, Ahvaz, Iran.

Abstract

Background

Acute appendicitis is the most common medical condition requiring immediate abdominal surgery. Medical ultrasound is a non-intrusive, non-expensive and available diagnostic method. In this study, the accuracy of ultrasound in diagnosis of acute appendicitis in hospital emergency was evaluated.

Materials and Methods

This retrospective cohort study was performed at Ahvaz Imam Khomeini hospital (Ahvaz city, Iran). The records of outpatient and inpatient of this hospital were studied to extract demographic information about the patients and radiological reports indicating the occurrence or exclusion of acute appendicitis and post-appendectomy report to allow for results comparison. Patient from 5-70 years included, with clinical suspicious to acute appendicitis, pathologic report also reviewed as gold standard of diagnosis.

Results

A total of 163 study subjects met the inclusion criteria, the age of the subjects ranged from 6 to 63 years. The accuracy, sensitivity and specificity were 98.1, 96 and 100%, respectively. The positive predictive value was 100%, while the negative predictive value was 82.35%. Diagnostic accuracy was 100% for the under-15 age group and 94.06% for the above 15 years age group.

Conclusion

The results showed that the medical ultrasound reports could be considered more credible in diagnosing acute appendicitis in under-15 male subjects which paves the way for more accurate planning of treatment and presenting patients with abdominal pains for surgery.

Key Words: Accuracy, Appendicitis, Diagnosis, Ultrasound.

*Please cite this article as: Mohammad Ghasem Hanafi, Afshin Shiri. Diagnostic Accuracy of Acute Appendicitis by Ultrasound in Hospital Emergency. Int J Pediatr 2019; 7(1): 1795-1802. DOI: [10.22038/ijp.2018.33708.2978](https://doi.org/10.22038/ijp.2018.33708.2978)

*Corresponding Author:

Mohammad ghasem Hanafi, Golestan Blvd., P.C. Box# 6135733119, Ahvaz, Iran. Fax: +98 6133743034.

Email: gaseghanafi@gmail.com

Received date: Jun.15, 2018; Accepted date: Aug. 12, 2018

1- INTRODUCTION

Acute appendicitis is the most common medical condition requiring immediate abdominal surgery (1). In most institutions, ultrasound has become the first-line imaging modality for the evaluation of appendix in the pediatric population (2). Although clinical symptoms of acute appendicitis are characterized by pains that begin in the region of the umbilicus and then "localizes" into the right lower quadrant known as McBurney's point; there is also elevation of neutrophilic white blood cells which are well-defined in more than 70% of the cases (3). The clinical symptoms of appendicitis may considerably overlap with other causes of abdominal pains (4). This necessitates the use of other diagnostic treatments, especially fast and available methods (5). Therefore, in 30% of the cases, it is impossible to have a definitive diagnosis before performing the surgery (6). Among the various imaging techniques, medical ultrasound as an available, noninvasive technique is the first-line diagnostic imaging examination for most patients suspected of developing appendicitis with ambiguous clinical evidence (7).

Almost 10% of the population develops acute appendicitis (8). Despite access to newer diagnostic methods, the number of misdiagnosed cases of appendicitis remained fixed between 1987 and 1997 (15.3%) (9, 10). The rate of negative appendectomy in females was higher than this and was 23.2% during their fertile years. The highest rate of negative appendectomy was recorded in females over 80 years (11). Computed Tomography (CT) with a sensitivity of 96% and specificity of 97% used to be the first-line method for the examination of acute abdominal pain (12, 13). However, considering the tendencies of patients to avoid exposure to x-ray and the increased risk of developing cancer as a result of

using this method (13), efforts have been made to reduce the exposure to x-ray while undergoing diagnostic tests, particularly in children. Acute appendicitis is an important disease requiring immediate abdominal surgery (14), its timely and correct diagnosis could considerably reduce its severe and unpleasant complications. Despite the existence of advanced diagnostic treatments, a significant number of patients initially diagnosed with acute appendicitis show negative laparotomy. Since medical ultrasound is a non-invasive, non-expensive and available diagnostic method, we attempted to study the accuracy of this method.

2- MATERIALS AND METHODS

2-1. Design and Setting

This retrospective cohort study was performed at Ahvaz Imam Khomeini hospital (Ahvaz city, Iran) with 2,160 emergency department visits per year.

2-2. Inclusion criteria of study

The study population included patients between 5 to 70 years of age who presented with symptoms indicative of acute appendicitis. Consecutive emergency department patients between May 10, 2014 and April 31, 2015 were registered.

2-3. Exclusion criteria of study

Patients were excluded if they left before being officially discharged or if they had a previous appendectomy or the ultrasound order was not placed by an emergency physician.

2-4. Methods and Measurements

Since this research was informed by the hospital and the clinical information, the records of the patients were collected from the archives of the hospital. The records of out-patient and in-patient of this hospital were studied to get the necessary information about the patients such as their

gender, age, the initial radiological reports indicating the occurrence or non-occurrence of acute appendicitis and post-appendectomy report to allow for the comparison of results.

2-5. Analysis

Chi-squared and T-tests were administered using SPSS software version 20 to examine, assess and measure the sensitivity, specificity, positive predicted value (PPV) and negative predicted value (NPV) of the collected data. The level of significance for the above-mentioned tests was set at $p < 0.05$.

3- RESULTS

A total of 163 study subjects met the inclusion criteria (**Figure.1**, STARD flow diagram); 61.34% ($n=100$) of the study subjects were female. The age of the subjects ranged from 6 to 63 years (**Table.1** Patient Characteristics). For better analyses of the study population, the subjects were categorized into two groups of under 15 years of age and over 15. A total of 93 participants were under 15 years i.e. 57.05% of the whole population while 70% of participants were over 15 years of age or 42.95% of the population. The accuracy, sensitivity and specificity were 98.1, 96 and 100%, respectively. The positive predictive value was 100%, and the negative predictive value was 82.35% (**Table.2**, Diagnostic accuracy). The following results were obtained for all the patients based on the initial medical Ultrasound and by comparing it with the post-surgery diagnoses of surgeons.

3-1. Results in the studied female subjects

Table-1: Baseline Characteristics of patients ($n = 163$)

Gender	Number (%)
Male	63 (38.66)
Female	100 (61.34)
15>years	93 (57.05)
15≤years	70 (42.94)
Age range (year)	6-63

Of the 100 assessed female individuals, 85 subjects had a positive medical ultrasound and consequently underwent surgery during which evidence of appendicitis was observed. In 15 cases where the evidence of appendicitis ultra-sonography evidence was not observed, we had 6 misdiagnoses (**Table.2** Diagnostic accuracy). These patients were relieved of their pains after administering medical abdominal treatments and released later while 4 cases were false negative.

3-2. Results in the studied male subjects

Of the 63 assessed male individuals, 44 (70%) individuals had a positive medical ultrasound which was compatible with in-surgery diagnoses. In the remaining 19 cases which were negative based on medical ultrasound examinations, there were two cases of incorrect medical ultrasound results (**Table.2**, Diagnostic accuracy).

3-3. Results in the studied under-15 years old subjects

This category covered 93 patients, the medical ultrasound results and post-surgery diagnoses which were compatible (**Table.2**, Diagnostic accuracy).

3-4. Results in the studied over-15 years old subjects

This category covered 70 patients with 50 cases of positive medical ultrasound results which were compatible with in-surgery diagnoses. The remaining 20 medical ultrasound results were negative for acute appendicitis, 6 of which were misdiagnoses (false negative) (**Table.2**, Diagnostic accuracy).

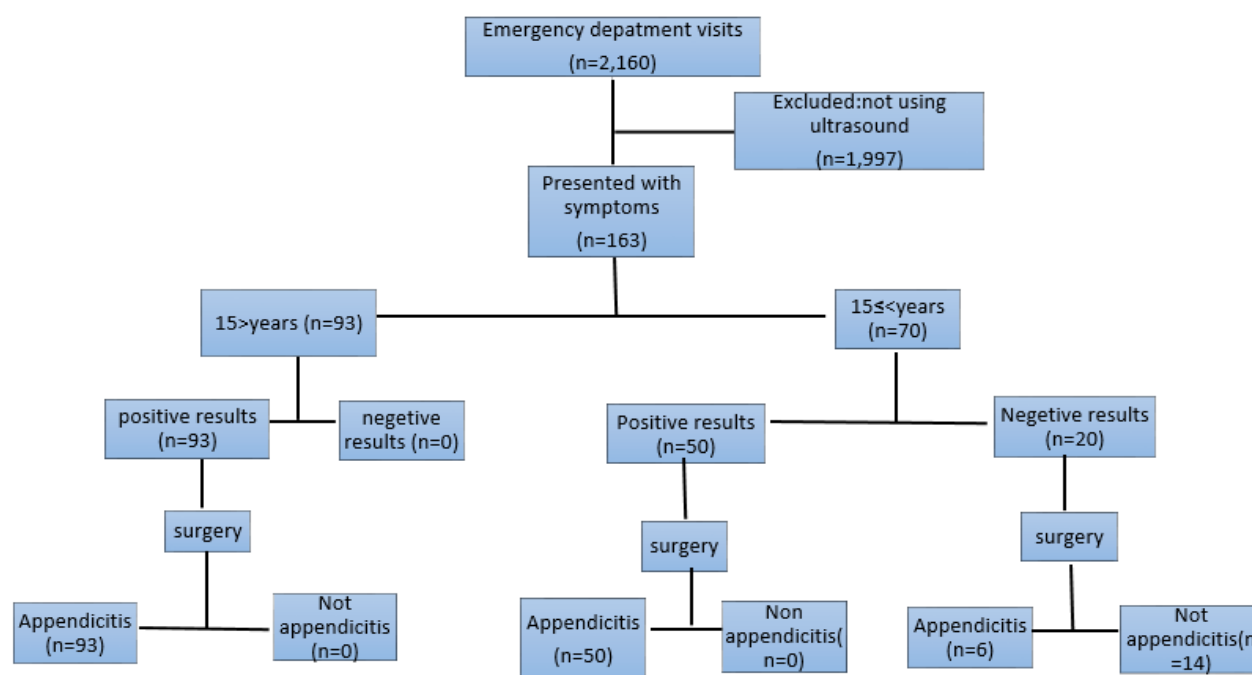


Fig.1: STARD flow diagram.

Table-2: Sensitivity and Specificity Values for Age and gender With the Use of Ultrasound for the Diagnosis of Acute Appendicitis

Patients	Number of patient	Sensitivity (%)	Specificity (%)	PPV (%)	NPV (%)	Diagnostic accuracy (%)
Female	100	89.4	100	100	73.33	94.7
Male	63	95.6	100	100	89.4	97.8
15 > years	93	100	100	100	100	100
15 ≤ years	70	89.2	100	100	70	94.06
Total	163	96	100	100	82.35	98.1

4- DISCUSSION

In this research, the accuracy of ultrasound in diagnosis of acute appendicitis in hospital emergency was evaluated. This study showed that the highest sensitivity was observed in under-15 male subjects considering the results obtained from different age groups, studying the genders and the applied study objectives which were in position of trust on the part of surgeons in medical ultrasound reports. Specificity and PPV were 100% for both age and gender groups. However, NPV and diagnostic accuracy were higher in under-15 male

subjects. A previous study reported that in children, ultrasound helps to reduce negative appendectomy and perforation rate (16). The results obtained from a study in 2014 showed that the sensitivity and specificity of ultrasound is 92.3%, and 94.7% (16), respectively. Another study showed that ultrasonography has high accuracy in diagnosing acute appendicitis and reduces negative appendectomies (17). But D'Souza et al. (2015) showed that ultrasonography commonly does not visualize the appendix, and has a low sensitivity for appendicitis (18). The diagnosis of a normal appendix on

ultrasound seems sufficiently accurate to deprive appendicitis with trust, while positive ultrasound should be expounded in continuity with the clinical aspect in impressing the decision to operate (19). Using ultrasound and CT-scan should normally be done to detect acute appendicitis. However, in terms of its benefits, ultrasound should be the first step (20) in the care of patients with lower abdominal pain after physical examination (21), and it plays an important role in assessing appendicitis in pregnant women, especially in the first trimester, and often contributes to a definite situation (22). Although the use of ultrasound as the first method of imaging for the diagnosis of appendicitis in children has increased over the past 5 years, more than 40% of children still undergo CT scan during their pre-operation assessment (23). Ultrasound may be a useful tool for examining children suspected of appendicitis, regardless of age and gender (24).

In children with suspected acute appendicitis, a radiation-free diagnostic imaging of ultrasonography selectively followed by MRI is feasible and comparable to CT-scan (25). Ultrasound sensitivity improves appendicitis with a longer duration of abdominal pain; while CT shows a high sensitivity regardless of the duration of pain (26). MRI can be compared with ultrasonography with the use of CT in detecting perforated appendicitis. However, both strategies incorrectly categorize up to half of the patients with perforated appendicitis as having simple appendicitis (27).

To minimize exposure to radiation in children, improvement should be made on the operation and acceptance of ultrasound as the main method of imaging abdominal pain in community hospitals (28). Point-of-care ultrasonography, when performed in emergency for the diagnosis of acute appendicitis, recorded high sensitivity of 92.3% and specificity of 95.8%, and had a

positive impact on the clinical decision making of emergency physicians (29). This study showed that ultrasound is an effective first-line diagnostic tool for acute appendicitis, and CT should be performed for patients with unresponsive ultrasound findings (30). In a systematic review and meta-analysis, the susceptibility of the United States to the diagnosis of acute appendicitis was 69% (95% confidence interval [CI]: 78-79%), and 81% (95%CI: 88-73%) (31); another meta-analysis showed that CT and MRI have a high risk of diagnosing clinical acute appendicitis in children which is generally significant (32). Comparing the diagnostic accuracy, the difference between clinical examinations and ultrasound was not significant. The difference between the diagnostic accuracy of clinical and laboratory findings and between ultrasonography and laboratory tests was statistically significant (33). Primary ultrasound can be as effective as CT in patients with acute appendicitis when the results are definite (34). Ultrasound is an accurate, safe and reliable method with a sensitivity of 92.7%, 94.5% of the feature, 93% accuracy, in detecting suspected cases of acute appendicitis that can help to minimize appendectomies and negative percutaneous rates (35).

5- CONCLUSION

The current study showed that the medical ultrasound reports could be considered more credible in diagnosing acute appendicitis in under-15 male subjects which paves the way for more accurate planning of treatment and presenting patients with abdominal pains for surgery. In addition, non-surgical procedures could be administered for both genders and age groups with stronger certainty and confidence in negative medical ultrasound reports.

6- CONFLICT OF INTEREST: None.

7- ACKNOWLEDGMENT

The present article was extracted from the thesis written by Afshin Shiri and was financially supported by Ahvaz Jundishapur University of Medical Sciences grants No. U-93008.

8- REFERENCES

1. Rothrock SG, Pagane J. Acute appendicitis in children: emergency department diagnosis and management. *Annals of emergency medicine* 2000, 36(1):39-51.
2. Doria AS, Moineddin R, Kellenberger CJ, Epelman M, Beyene J, Schuh S, et al. US or CT for Diagnosis of Appendicitis in Children and Adults? A Meta-Analysis. *Radiology* 2006, 241(1):83-94.
3. Grover CA, Sternbach G. Charles McBurney: McBurney's point. *The Journal of emergency medicine* 2012, 42(5):578-81.
4. Kwan KY, Nager AL. Diagnosing pediatric appendicitis: usefulness of laboratory markers. *The American journal of emergency medicine* 2010, 28(9):1009-1015.
5. Birnbaum BA, Wilson SR. Appendicitis at the millennium. *Radiology* 2000, 215(2):337-48.
6. Jones PF. Suspected acute appendicitis: trends in management over 30 years. *The British journal of surgery* 2001, 88(12):1570-77.
7. Chan I, Bicknell SG, Graham M. Utility and diagnostic accuracy of sonography in detecting appendicitis in a community hospital. *American Journal of Roentgenology* 2005, 184(6):1809-12.
8. Sutton D. Text book of radiology and imaging. 7th edition. London: Churchill livingstone; 2003.pp.683_684.
9. Mock K, Lu Y, Friedlander S, Kim DY, Lee SL. Misdiagnosing adult appendicitis: clinical, cost, and socioeconomic implications of negative appendectomy. *American journal of surgery* 2016, 212(6):1076-82.
10. Ahmed ST, Ranjan R, Saha SB, Singh B. Traumatic appendicitis misdiagnosed as a case of haemoperitoneum. *BMJ Case Rep.* 2014;2014.
11. Brunnicardi F, Andersen D, Billiar T, Dunn D, Hunter J, Matthews J, Pollock R. *Schwartz's Principles of Surgery*, 10e: McGraw-Hill; 2014.
12. Yacoe ME, Jeffrey Jr RB. Sonography of appendicitis and diverticulitis. *Radiologic Clinics of North America* 1994, 32(5):899-912.
13. Fujii Y, Hata J, Futagami K, Hamada T, Mitsuoka H, Teramen K, et al. Ultrasonography improves diagnostic accuracy of acute appendicitis and provides cost savings to hospitals in Japan. *Journal of ultrasound in medicine* 2000, 19(6):409-14.
14. Townsend CM, Beauchamp RD, Evers BM, Mattox KL. *Sabiston Textbook of Surgery E-Book: Elsevier Health Sciences*; 2016.
15. Pastore V, Cocomazzi R, Basile A, Pastore M, Bartoli F. Limits and advantages of abdominal ultrasonography in children with acute appendicitis syndrome. *African journal of paediatric surgery : AJPS* 2014, 11(4):293-96.
16. Saucier A, Huang EY, Emeremni CA, Pershad J. Prospective evaluation of a clinical pathway for suspected appendicitis. *Pediatrics* 2014, 133(1):e88-95.
17. Hussain S, Rahman A, Abbasi T, Aziz T. Diagnostic accuracy of ultrasonography in acute appendicitis. *Journal of Ayub Medical College, Abbottabad : JAMC* 2014, 26(1):12-17.
18. D'Souza N, D'Souza C, Grant D, Royston E, Farouk M. The value of ultrasonography in the diagnosis of appendicitis. *International journal of surgery (London, England)* 2015, 13:165-69.
19. Scrimgeour DSG, Driver CP, Stoner RS, King SK, Beasley SW. When does ultrasonography influence management in suspected appendicitis? *ANZ journal of surgery* 2014, 84(5):331-34.
20. Park JS, Jeong JH, Lee JI, Lee JH, Park JK, Moon HJ. Accuracies of diagnostic

methods for acute appendicitis. *The American surgeon* 2013, 79(1):101-6.

21. Sezer TO, Gulece B, Zalluhoglu N, Gorgun M, Dogan S. Diagnostic value of ultrasonography in appendicitis. *Advances in clinical and experimental medicine : official organ Wroclaw Medical University* 2012, 21(5):633-36.

22. Drake FT, Kotagal M, Simmons LE, Parr Z, Dighe MK, Flum DR. Single institution and statewide performance of ultrasound in diagnosing appendicitis in pregnancy. *The journal of maternal-fetal & neonatal medicine : the official journal of the European Association of Perinatal Medicine, the Federation of Asia and Oceania Perinatal Societies, the International Society of Perinatal Obstet* 2015, 28(6):727-33.

23. Kotagal M, Richards MK, Chapman T, Finch L, McCann B, Ormazabal A, et al. Improving ultrasound quality to reduce computed tomography use in pediatric appendicitis: the Safe and Sound campaign. *American journal of surgery* 2015, 209(5):896-900; discussion 900.

24. Lofvenberg F, Salo M. Ultrasound for Appendicitis: Performance and Integration with Clinical Parameters. *BioMed research international* 2016, 2016:5697692.

25. Aspelund G, Fingeret A, Gross E, Kessler D, Keung C, Thirumoorthi A, Oh PS, et al: Ultrasonography/MRI versus CT for diagnosing appendicitis. *Pediatrics* 2014, 133(4):586-93.

26. Bachur RG, Dayan PS, Bajaj L, Macias CG, Mittal MK, Stevenson MD, et al: The effect of abdominal pain duration on the accuracy of diagnostic imaging for pediatric appendicitis. *Annals of emergency medicine* 2012, 60(5):582-590 e583.

27. Leeuwenburgh MM, Wiezer MJ, Wiarda BM, Bouma WH, Phoa SS, Stockmann HB, et al: Accuracy of MRI compared with ultrasound imaging and selective use of CT to discriminate simple from perforated appendicitis. *The British journal of surgery* 2014, 101(1):e147-55.

28. Alter SM, Walsh B, Lenehan PJ, Shih RD. Ultrasound for Diagnosis of Appendicitis in a Community Hospital Emergency

Department has a High Rate of Nondiagnostic Studies. *The Journal of emergency medicine* 2017, 52(6):833-38.

29. Gungor F, Kilic T, Akyol KC, Ayaz G, Cakir UC, Akcimen M, et al. Diagnostic Value and Effect of Bedside Ultrasound in Acute Appendicitis in the Emergency Department. *Academic emergency medicine : official journal of the Society for Academic Emergency Medicine* 2017, 24(5):578-86.

30. Hwang ME. Sonography and Computed Tomography in Diagnosing Acute Appendicitis. *Radiologic technology* 2018, 89(3):224-37.

31. Giljaca V, Nadarevic T, Poropat G, Nadarevic VS, Stimac D. Diagnostic Accuracy of Abdominal Ultrasound for Diagnosis of Acute Appendicitis: Systematic Review and Meta-analysis. *World journal of surgery* 2017, 41(3):693-700.

32. Zhang H, Liao M, Chen J, Zhu D, Byanju S. Ultrasound, computed tomography or magnetic resonance imaging - which is preferred for acute appendicitis in children? A Meta-analysis. *Pediatric radiology* 2017, 47(2):186-96.

33. Ferrarese A, Falcone A, Solej M, Bono D, Moretto P, Dervishi N, Andrea V, Enrico S, Nano M, Martino V: Surgeon's clinical valuation and accuracy of ultrasound in the diagnosis of acute appendicitis: A comparison with intraoperative evaluation. Five years experience. *International journal of surgery (London, England)* 2016, 33 Suppl 1:S45-50.

34. Koo HS, Kim HC, Yang DM, Kim SW, Park SJ, Ryu JK: Does computed tomography have any additional value after sonography in patients with suspected acute appendicitis? *Journal of ultrasound in medicine : official journal of the American Institute of Ultrasound in Medicine* 2013, 32(8):1397-1403.

35. Shirazi AS, Sametzadeh M, Kamankesh R, Rahim F: Accuracy of sonography in diagnosis of acute appendicitis running. *Pakistan journal of biological sciences : PJBS* 2010, 13(4):190-93.