

## H Syndrome Masquerade as Rheumatologic Disease

Mohammad Razmyar<sup>1</sup>, Zahra Rezaieyazdi<sup>2</sup>, Naser Tayebi Meibodi<sup>3</sup>, Zahra Fazel<sup>4</sup>, Poursan Layegh<sup>5</sup>

<sup>1</sup>Assistant of Dermatology, Cutaneous Leishmaniasis Research Center, Mashhad University of Medical Sciences, Mashhad, Iran.

<sup>2</sup>Professor of Rheumatology, Rheumatic Diseases Research Center, Mashhad University of Medical Sciences, Mashhad, Iran.

<sup>3</sup>Professor of Pathology, Fellowship in Dermatopathology, Cutaneous Leishmaniasis Research Center, Mashhad University of Medical Sciences, Mashhad, Iran.

<sup>4</sup>Dermatologist, Mashhad, Iran.

<sup>5</sup>Professor of Dermatology, Cutaneous Leishmaniasis Research Center, Mashhad University of Medical Sciences, Mashhad, Iran.

### Abstract

#### Background

H syndrome is an autosomal recessive genodermatosis with a low prevalence which is caused by a mutation in SLC29A3 gene. This disorder is characterized by sclerotic, hyperpigmented, hypertrichotic cutaneous plaques with systemic involvement including: hepatosplenomegaly, heart anomalies, hearing loss, hypogonadism, low height, and hyperglycemia.

#### Case Presentation

Here we have presented two cases of H syndrome that have been misdiagnosed and mismanaged as rheumatologic disease. The first case had been represented with sclerotic skin lesions and diagnosed as morphea, and second one with chronic and recalcitrant to treatment arthritis as juvenile idiopathic arthritis.

#### Conclusion

H syndrome is an autosomal recessive genodermatosis that has been recently recognized with a variety of manifestations and overlapping features with other diseases. Increase the knowledge of physicians for wide spectrum manifestations of this syndrome along with reporting the misdiagnosis of this condition can increase the accuracy of physicians for its better identification. This time our cases masquerade as rheumatologic diseases.

**Key Words:** Children, H syndrome, Genodermatosis, SLC29A3 gene mutation.

\*Please cite this article as: Razmyar M, Rezaieyazdi Z, Tayebi Meibodi N, Fazel Z, Layegh P. H Syndrome Masquerade as Rheumatologic Disease. Int J Pediatr 2018; 6(7): 7965-71. DOI: 10.22038/ijp.2018.29988.2638

#### \*Corresponding Author:

Poursan Layegh, Professor of Dermatology, Cutaneous Leishmaniasis Research Center, Mashhad University of Medical Sciences, Mashhad, Iran, Fax: +985138583845

Email: Layeghpo@mums.ac.ir

Received date: Mar.22, 2018; Accepted date: Apr.22, 2018

## 1- INTRODUCTION

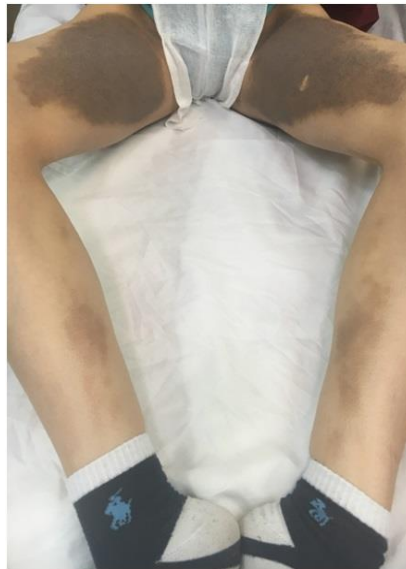H syndrome is a recently recognized (1) rare autosomal recessive genodermatosis which is characterized by sclerotic, hyperpigmented, hypertrichotic skin plaques with systemic manifestation including: hepatosplenomegaly, hearing loss, heart anomalies, hypogonadism, low height (short stature), hyperglycemia, and hallux valgus/ flexion contractures (2). Since this disease has recently been given a name and its overlapping features with other diseases, it could be easily misdiagnosed and mismanaged. In this article, we have studied two Iranian patients being misdiagnosed for years, one as morphea and the other as juvenile idiopathic arthritis.

## 2- CASE REPORT

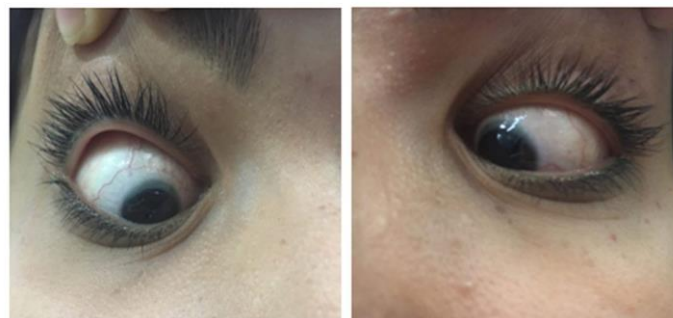### 2-1. CASE 1

A 19-year-old girl was referred to dermatology clinic of Imam Reza Hospital (Mashhad, Iran) with a 12-year history of sclerotic plaque on her thighs. She stated that these lesions first appeared on the inner sides of her thighs when she was 7 years old and then they gradually enlarged. She had never been referred to a doctor before in the last 5 years until a new lesion appeared on the lateral side of her left thigh. Clinico-pathologically she was diagnosed as morphea and first received topical and intralesional corticosteroid, but after no proper response, she was given systemic treatment with methotrexate and hydroxychloroquine. She was eventually referred to our clinic at the university hospital, because of the appearance of new tightness on the anterior side of her left thigh. During skin examination, large indurated hyperpigmented plaques and hypertrichosis with irregular borders and rough surface were seen on the medial aspect of both thighs and lateral aspect of left ones (**Figure.1**). Based on her medical Erythrocyte sedimentation rate (ESR) were in normal limit. We diagnosed her as H

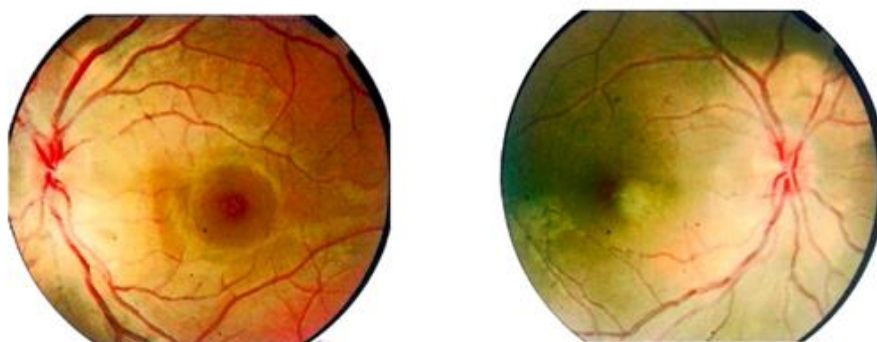
history, she has suffered from sensory neural hearing loss since she was 6 years old which was before the emergence of cutaneous lesions. She did not take any medication except aforementioned ones. Her parents had consanguineous marriage. She had a regular menstrual cycle. We have found out that she had bilateral arcus senilis and the proceeding ophthalmic examination proved bilateral choroid osteoma which is a rare benign ossifying tumor characterized by mature cancellous bone involving the choroid (**Figure 2a, b**). Other physical examinations were normal. Abdominal ultrasonography showed mild hepatosplenomegaly. In cardiac echocardiography, mild mitral valve regurgitation (MR) and prolapsed (MVP), tricuspid regurgitation (TR), and trivial pulmonary insufficiency (PI) were detected. The histopathology of an incisional skin biopsy showed hyperorthokeratosis, acanthosis, papillomatosis, spongiosis, and hyperpigmentation of basal layer with mild focal lymphomononuclear exocytosis in epidermis. In reticular dermis, mild fibrosis with relative increase in hair follicles and interstitial infiltration of histiocytic cells along with moderate perivascular infiltration of lymphoplasmocyte were reported. We have also observed; fibrotic and wide interlobular septa of hypoderm, infiltration of histiocytes and plasmocytes with scattered siderophages and nodular aggregations of lymphoid cells and the spread of lymphoplasmacytic cells into inter lipocytes adjacent to septa (**Figure 3 a, b, c**). Biochemical laboratory tests such as; fasting blood sugar (FBS), lipid profile, complete blood count (CBC), and serum level of follicle-stimulating hormone (FSH), luteinizing hormone (LH), and Thyroid-stimulating hormone (TSH), antibodies to nuclear antigen (ANA), C-reactive protein (CRP), syndrome with the constellation of clinical and paraclinical findings.



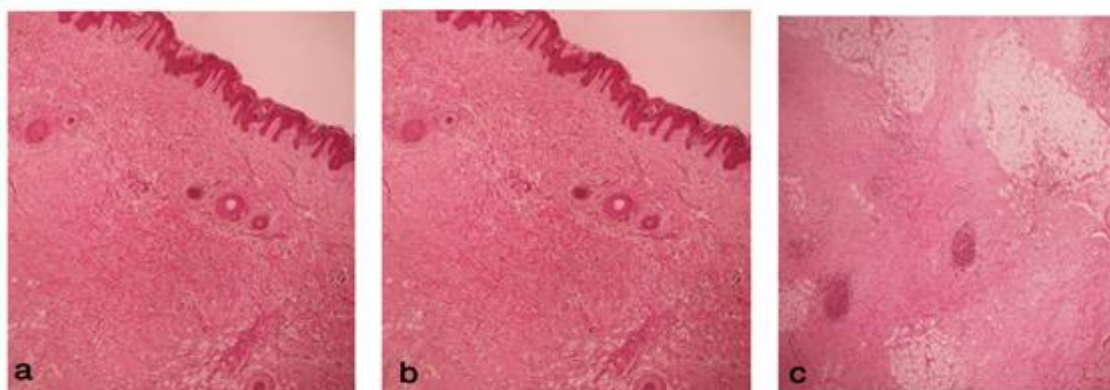
**Fig.1:** Large hyperpigmented plaques with hypertrichosis and induration, irregular border and rough surface in medial aspect of both thighs.



**Fig. 2a:** The bilateral arcus senilis.



**Fig. 2b:** The bilateral choroid osteoma characterized by mature cancellous bone involving the choroid.



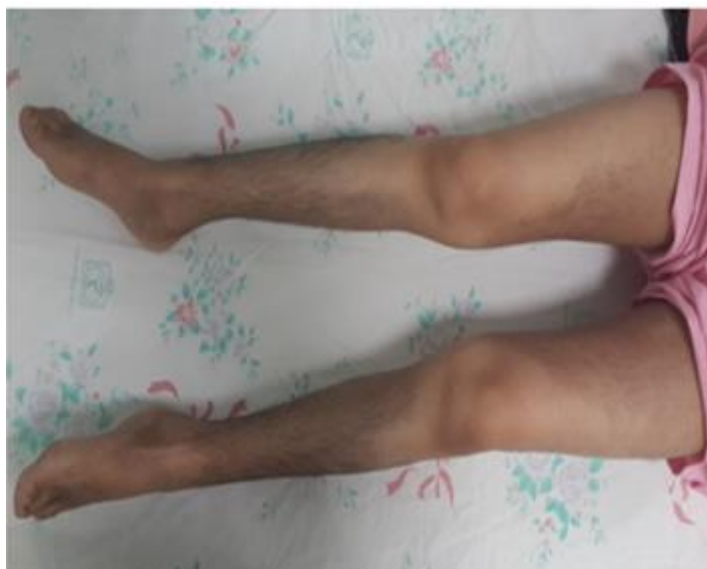**Fig.3 a, b, c:** Dermal and subcutaneous necrosis. Interstitial infiltration of lymphomononuclear cells (H and E  $\times 4$ ,  $\times 10$ ,  $\times 40$  magnification, respectively).

## 2-2. CASE 2

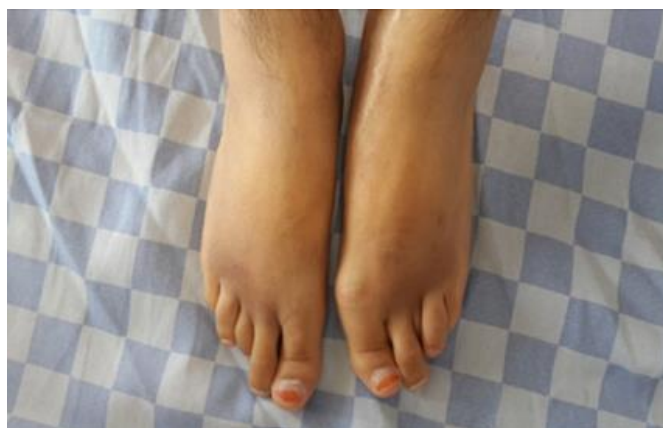While we were working on the former case, we have faced a surprising incident, another patient with similar symptoms came to us, after further inquiries, we have discovered that the latter and the former patients were cousins. She was a 15-year-old girl with symmetric mild stiffness, hyperpigmented, and hypertrichotic cutaneous changes on her inner aspects of thighs and shins which began to appear 4 months earlier. She has suffered from sensory neural hearing loss for 12 years. When she was 7 years old, she was diagnosed with juvenile idiopathic arthritis, because of swelling in bilateral ankles, right knee and second proximal interphalangeal joint of the right hand and the presence of other associated symptoms. Therefore she had received oral prednisolone and methotrexate for years with a complete remission period; however recently it relapsed again as intractable arthritis which was controlled by etanercept. She has not experienced menstrual cycles till this age.

On physical examination symmetric mild stiffness, hyperpigmented, hypertrichotic plaques on her thighs and shins with sparing of knees, left side hallux valgus

and also arcus senilis were detected (**Figure 4a, b**). In abdominal ultrasonography, splenomegaly was only detected. Echocardiography revealed mild mitral valve prolapse (MVP), mitral regurgitation (MR), tricuspid regurgitation (TR) and pericardial effusion. Bone marrow biopsy showed hypocellular marrow with iron depletion with no finding for any storage diseases. The CBC showed microcytic anemia, serum iron was  $46 \mu\text{g/dl}$  and Total iron-binding capacity (TIBC) was  $347 \mu\text{g/dl}$  which was compatible with iron deficiency anemia. The ESR was  $60 \text{ mm/h}$ , CRP:  $+3 \text{ mm}$ , rheumatoid factor (RF), Anti-cyclic citrullinated peptide (Anti-CCP), and antinuclear antibodies (ANA) profile were negative. All the other biochemical tests were in normal limit. The skin biopsy from indurated plaques confirmed hyperorthokeratosis with hyperpigmentation of basal layer. Derm was nonfibrotic with mild chronic perivascular inflammation. In Hypoderm, interlobular septa were wide and fibrotic with scattered lymphohistiocytic and multinuclear giant cells along with histiocytic cells infiltration in adipose lobules.



**Fig. 4a:** Symmetric mild stiffness, hyperpigmented hypertrichotic plaques on her thighs and shins with sparing of knees.



**Fig. 4b:** The left side hallux valgus and crossover of fourth toe.

### 3- DISCUSSION

The H syndrome which was named first in 2008 (1), is a new genodermatosis with autosomal recessive transmission due to the mutation in SLC29A3 gene. The H stands for the major clinical and laboratory findings of hyperpigmentation and hypertrichosis, hepatosplenomegaly, heart anomalies, hearing loss, hypogonadism, low height, and occasionally hyperglycemia (2). Not only this syndrome is more prevalent in men but also most of the reported cases were from south and west Asia (3). While here we have

reported the first two female cases from Northeast of Iran. Regarding our first case, the primary and prominent manifestation of the disease was dermatologic; in which morphea en plaque, smooth muscle hamartoma, and Becker's melanosis were considered as differential diagnosis based on cutaneous findings. Becker's nevus which is characterized by a circumscribed hyperpigmented patch with irregular edges, typically appears on the upper trunk, shoulders, or upper arms of adolescent males. The lesion gradually develops hypertrichosis (4). As mentioned

before this lesion which is usually acquired, is more common in men. Becker's nevus sometimes has some associated abnormalities, in this case it is being referred as Becker's nevus syndrome (5). The smooth muscle hamartoma which is a firm, skin-colored or hyperpigmented plaque, is most commonly located on the trunk, buttocks or proximal extremities, it can be either congenital or acquired. Lesions with hypertrichosis and hyperpigmentation overlap Becker's nevus. These hamartomas are most often solitary and are not associated with systemic involvement (6). Other differential diagnosis of skin lesions that has been reported in H syndrome cases, are: Winchester and Polyneuropathy, Organomegaly, Endocrinopathy, Monoclonal protein, Skin changes (POEM) syndromes which did not match our patient. Based on clinical features and primarily histopathology report, she had been diagnosed with morphea and later being treated for seven years with unremarkable response. Such diagnostic mistakes have already been reported for skin lesions of H syndrome (7); morphea and scleroderma are the most common differential diagnosis of H syndrome skin lesions which are easily mistakable.

About the second case, the predominant symptom was chronic arthritis with the tendency to wax and wane which had currently resisted the treatment. Although this case was diagnosed, treated and controlled as juvenile idiopathic arthritis for years, it had many unrelated signs and symptoms with arthritis setting. Additionally our rheumatologist colleagues were not satisfied with the patient's diagnosis, it was when H syndrome was diagnosed after several dermatology consultations and reconsidering all the clinico-laboratory findings. To the authors best knowledge, the description of arthritis in the H syndrome has never been reported, which

has made it difficult to decide whether this is a manifestation of H syndrome or is a related disease. Based on the patient's history and arthritis process, we believe that there is an association between juvenile idiopathic arthritis and genetic disease of H syndrome. On the other hand, arthritis has been reported as a symptom in some other histiocytosis such as; Langerhans cell histiocytosis and multicentric reticulohistiocytosis or even in a reported case of rheumatoid arthritis in Intravascular/Intralymphatic Histiocytosis (8). Since H syndrome has an immunohistochemistry very similar to Rosai-Dorfman disease (9), and since few cases of arthritis have also been reported in Rosai-Dorfman syndrome (10), it could be possible to assume that H syndrome manifested arthritis is similar to that of Rosai-Dorfman syndrome. Further investigations are required to provide a better explanation regarding arthritis as an associated symptom or a totally new manifestation of the disease.

#### **4- CONCLUSION**

Reports of H syndrome as a newly defined entity with different systemic manifestation are rare in the literatures and to the best of our knowledge, H syndrome masquerading rheumatologic disease especially arthritis has been reported very rare and one of our cases is the first case report from Iran. Familiarity of physicians with various manifestations of this syndrome can increase the accuracy of their diagnosis and prevention of mismanagement.

**5- CONFLICT OF INTEREST:** None.

#### **6- REFERENCES**

1. Molho-Pessach V, Agha Z, Aamar S, Glaser B, Doviner V, Hiller N, et al. The H syndrome: a genodermatosis characterized by indurated, hyperpigmented, and hypertrichotic skin with systemic manifestations. *J Am Acad Dermatol.* 2008; 59:79-85.

2. Molho-Pessach V, Lerer I, Abeliovich D, Agha Z, Libdeh AA, Broshtilova V, et al. The H syndrome is caused by mutations in the nucleoside transporter hENT3. *Am J Hum Genet.* 2008; 83: 529-34.
3. Mehta S, Masatkar V, Mittal A, Khare AK, Gupta LK. The H syndrome. *Indian J Paediatr Dermatol* 2015; 16: 102-4.
4. Sadlier M, O'Regan GM. Becker's Nevus. *N Engl J Med.* 2015; 372: 1249.
5. Rabinovitz HS, Barnhill RL. Benign melanocytic neoplasm. In: *Dermatology.* (Bolognia JL, Jorizzo JL, Schaffer JV, eds), 3rd edn. Philadelphia: Elsevier Saunders; 2012:1851-84.
6. Kaddu S, Kahler S. Muscle, adipose and cartilage neoplasm. In: *Dermatology.* (Bolognia JL, Jorizzo JL, Schaffer JV, eds), 3rd edn. Philadelphia: Elsevier Saunders; 2012:1979-92.
7. Tekin B, Atay Z, Ergun T, Can M, Tuney D, Babay S, et al. H Syndrome: A Multifaceted Histiocytic Disorder with Hyperpigmentation and Hypertrichosis. *Acta Derm Venereol.* 2015; 95: 1021-3.
8. Kaneko T, Takeuchi S, Nakano H, Sawamura D. Intralymphatic histiocytosis with rheumatoid arthritis: possible association with the joint involvement. *Case Reports in Clinical Medicine.* 2014; 3: 149-52.
9. Pessler F, Paessler ME, Lambert M, Dewitt EM, Sherry DD. Polyarthritis in a child with Rosai-Dorfman disease. *Clin Exp Rheumatol.* 2007; 25: 645-8.
10. Gupta S, Finzel KC, Grubber BL. Rosai-Dorfman disease masquerading as chronic ankle arthritis: a case report and review of the literature. *Rheumatology (Oxford).* 2004; 43: 811-2.