

Brain MRI Findings of Complicated Meningitis in Children: A Cross Sectional Study from Central Iraq

Muna AG. Zghair¹, *Qays A. Hassan², Hayder Y. Mohammed³

¹Assitant Professor, Section of Radiology, Department of Medicine, College of Medicine, Al-Mustansiriyah University, Baghdad, Iraq.

²Assitant Professor, Section of Radiology, Department of Surgery, Al-Kindy College of Medicine, University of Baghdad, Baghdad, Iraq.

³Radiologist Specialist, Department of Radiology, Al-Yarmook Teaching Hospital, Baghdad, Iraq.

Abstract

Background

Meningitis is a common neurological emergency and a leading cause of death and neurological disability worldwide. MRI is extremely useful for detecting and monitoring the complications of meningitis. The purpose of this study was to describe the brain MRI findings in children with complicated meningitis.

Materials and Methods

This cross-sectional study was conducted in Radiology Department at the Central Pediatric Teaching Hospital, Baghdad, Iraq between the period of October 2015 and August 2017. A total of 40 children who were known cases of meningitis that not respond to the conventional treatment and examined with MRI were included in this study. MRI protocols were achieved with Variable Echo Multiplanar sequences and all the images were interpreted by two qualified radiologists for any intracranial findings.

Results

The mean age of patients was 3.3 ± 3.2 years; 35% of them were infant age group. Females were more than males with a female to male ratio as 1.2:1. About half of children were diagnosed by MRI with necrosis, 30% of them with hydrocephalus, 15% of them with abscess and 7.5% of them with subdural effusion. The hydrocephalus was found among children with lower mean age and abscess was found among children with higher mean age children.

Conclusion

The main MRI findings of children with complicated meningitis were necrosis, hydrocephalus, abscess and subdural effusion.

Key Words: Children, Brain, Iraq, Meningitis, MRI.

*Please cite this article as: Zghair MAG, Hassan QA, Mohammed HY. Brain MRI Findings of Complicated Meningitis in Children: A Cross Sectional Study from Central Iraq. Int J Pediatr 2018; 6(5): 7595-7603. DOI: [10.22038/ijp.2018.30179.2655](https://doi.org/10.22038/ijp.2018.30179.2655)

*Corresponding Author:

Qays A. Hassan, University of Baghdad, Al-Kindy College of Medicine, Al-Nahdha square, Postal address: 10071 University of Baghdad, Baghdad, Iraq.

Email: qtimeme@yahoo.com

Received date: Feb.17, 2018; Accepted date: Mar.22, 2018

1- INTRODUCTION

Meningitis is a serious clinical condition which proceeds immediately and can lead to significant morbidity. Even with proper treatment, meningitis can damage the brain and cause long-term complications (1-3). A child's prognosis after an episode of meningitis, depends upon the cause (the type of bacterium or virus), the severity of the illness, the time taken in diagnosis, and initiation of treatment, and the age of the child (3, 4). In developed countries such as the United States, approximately 15% of children with bacterial meningitis develop complications (1, 5, 6). Complications are more common in children who live in developing countries (7, 8). Conventional contrast-enhanced brain Magnetic resonance imaging (MRI) is the most sensitive radiological investigation for the diagnosis of meningitis because it serves to recognize the appearance and degree of inflammatory changes in the meninges as well as complications. Fluid-attenuated inversion recovery (FLAIR), and contrast-enhanced MRIs serve to represent the complications of meningitis better than other images (9). These complications involve empyema, effusion, cerebritis, abscess, venous thrombosis, venous and arterial infarcts, ventriculitis, hydrocephalus, and edema (10). Distention of the subarachnoid space on MRI is the earliest finding in meningitis (9).

Several days after the onset of infection, the pia covering the brain and the arachnoid lining the dura mater develop vascular congestion; contrast injection may demonstrate enhancement of these meninges (9). Diffusion-weighted imaging (DWI) is used to characterize complications of meningitis such as cerebral infarction, purulent leptomeningitis, subdural empyema and cavernous sinus abscess formation (11). The purpose of the study was to describe

brain MRI findings in children with complicated meningitis.

2- MATERIALS AND METHODS

2-1. Study population

This cross-sectional study was conducted in Radiology Department at the Central Pediatric Teaching Hospital, Baghdad, Iraq, between the period of October 2015 and August 2017. The study included randomly 40 patients aged less than 10 years who were known cases of meningitis that not respond to the conventional treatment and referred to the Radiological Department with deteriorated clinical symptoms in spite of ongoing treatment medication. Ethical clearance for this study was obtained from the Central Pediatric Teaching Hospital Scientific and Ethics Committee (approval number 32 / 2015) before the commencement of the study. Informed consent for all patients' parents was obtained.

For descriptive purpose, the study groups regarding the age were divided into 4 categories (neonate, infant, less than 5 years, 5-10 years). The MRI was performed in a 1.5-Tesla MRI system (Magnetom Symphony, Siemens Medical Solutions, Erlangen, Germany). Sedation with oral chloral hydrate or ketamine (IV), 50mg/ml in a dose of 1-2 mg/kg was used in the young child who could not tolerate the examination study. Using head coils, imaging protocols include T1 weighted sagittal spine echo, axial T2 weighted turbo spine echo, coronal FLAIR, and Diffusion-weighted. All images were interpreted by two qualified radiologists for any intracranial findings. The radiologists used a high-resolution individual monitor for their interpretation of the MR images and a special formatting sheet for gathering the observed findings.

2.2. Statistical analysis

Every one of patients' information entered utilizing automated factual programming;

Statistical Package for Social Sciences (SPSS) form 21.0 was utilized. Engaging measurements displayed as (mean \pm standard deviation), and frequencies as rates. Kolmogorov Smirnov test checked the ordinarieness of the information set. Fisher's correct test utilized when the expected variable was fewer than 20%. One way ANOVA investigation was utilized to look at between more than two means. In all factual examination, level of criticalness (p-value) set at ≤ 0.05 and the outcome displayed as tables and additionally charts.

3- RESULTS

To describe brain MRI findings with complicated meningitis, a total of 40 children with meningitis were included in this study. The mean age of these children was 3.3 ± 3.2 years; 35% of them were infant age group, 27.5% were 5-10 years, 20% were less than 5 years age and 17.5% of them were in neonatal age group. Females were more than males with a female to male ratio as 1.2:1. All these findings were shown in **Table.1**.

Generally, about half of children were diagnosed by MRI with necrosis, 30% of them with hydrocephalus, 15% of them with abscess, and 7.5% of them with subdural effusion. All these findings were shown in **Table.2**. Three children were diagnosed by MRI with diffuse temporal-occipital restricted diffusion and 3 children were diagnosed with parietal necrosis (**Figure.1**). Two children were diagnosed with left temporal venous thrombosis, 2 children were diagnosed with ventriculitis

(**Figure.2**), 3 children were diagnosed with subdural effusion (**Figure.3**), 2 children were diagnosed with tuberous sclerosis, 2 children were diagnosed with multiple white matter necrosis and tuberous sclerosis, 2 children were diagnosed with thalamic and basal ganglia infarction, 2 children were diagnosed with bilateral basal ganglia infarction, 2 children were diagnosed with subdural empyema and triventricular hydrocephalus. MRI revealed that each one child had the following after meningitis; hemorrhagic necrosis, multiple bilateral basal ganglia ischemia, bilateral parieto-occipital white matter small vessel ischemia, bilateral non-symmetrical focal necrosis of white matter and basal ganglia, diffuse parieto-frontal necrosis, bilateral parietal necrosis, diffuse necrotic foci, tri hydrocephalus and cerebral necrosis, periventricular restricted edema, basal ganglia necrosis, diffuse bilateral cortical necrosis, temporal brain abscess, ventriculitis and triventricular hydrocephalus and cerebral abscess (**Figures 4 and 5**).

All these findings were shown in **Table.3**. No significant differences between children with different general diagnosis regarding their age and gender as shown in **Table.4** ($P > 0.05$). The results showed that there were no significant differences between age children with different general diagnosis regarding their mean age ($p = 0.8$). However, hydrocephalus was found among children with lower mean age and abscess was found among children with higher mean age children as revealed in **Figure.6**.

Table-1: Demographic characteristics of children included in the present study

| Variables | Number | Percent |
|--|--------|---------|
| Age, mean \pm SD (3.3 \pm 3.2 years) | | |
| Neonate | 7 | 17.5 |
| Infant | 14 | 35.0 |
| Less than 5 years children | 8 | 20.0 |
| 5-10 years children | 11 | 27.5 |
| Total | 40 | 100.0 |

| Gender | | |
|--------|----|-------|
| Male | 18 | 45.0 |
| Female | 22 | 55.0 |
| Total | 40 | 100.0 |

Table-2: The general diagnosis of children included in the present study

| General diagnosis | Number | Percent |
|-------------------|--------|---------|
| Hydrocephalus | 12 | 30.0 |
| Necrosis | 19 | 47.5 |
| Abscess | 6 | 15.0 |
| Subdural effusion | 3 | 7.5 |
| Total | 40 | 100.0 |

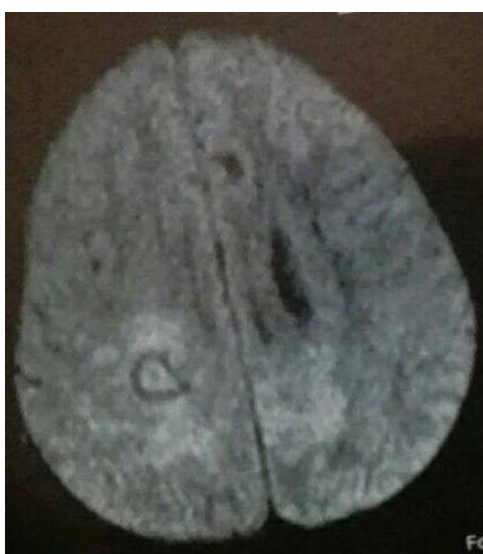

Fig.1: Axial DW image in a 7 years male patient shows right parietal white matter necrosis. DW: diffusion-weighted.

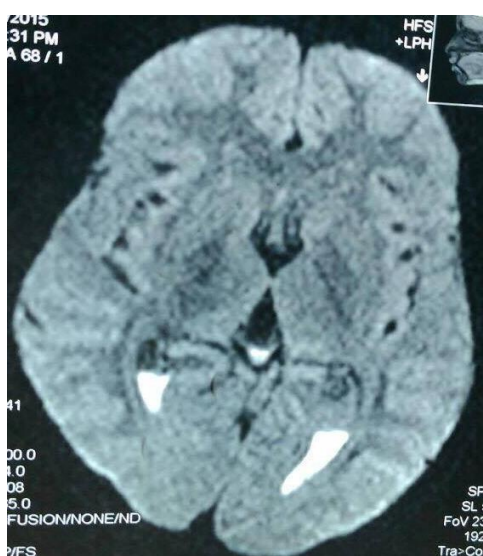

Fig.2: Axial DW image in a 9 years old female shows ventriculitis. DW: diffusion-weighted.

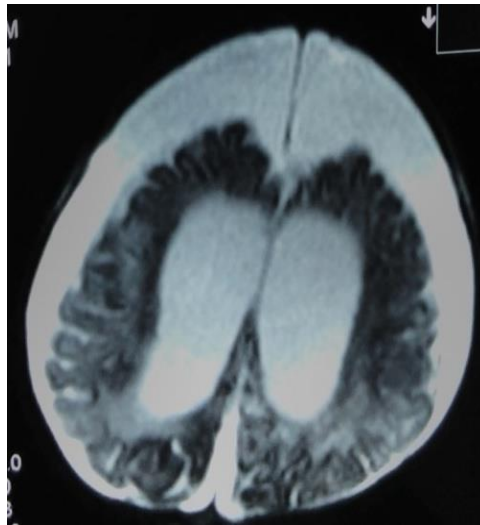


Fig.3: Axial T2 MRI image in a 7 months male patient shows bilateral moderate subdural effusion.

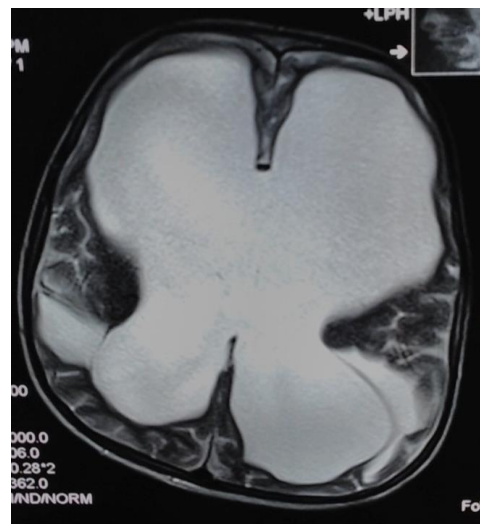

Fig.4: Axial T2 MRI image in a 10 years old male show massive hydrocephalus with periventricular edema.

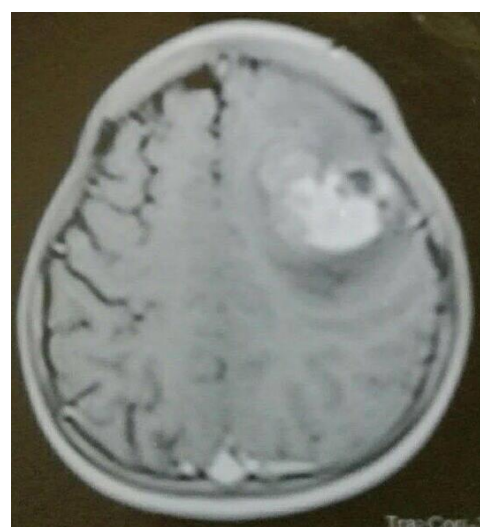

Fig.5: Axial T1 post-contrast MRI image in a 7 years female patient shows left-sided parietal abscess.

Table-3: Detailed diagnosis of children included in the present study

| Detailed diagnosis | Number | Percent |
|--|--------|---------|
| Left temporal venous thrombosis | 2 | 5.0 |
| Hemorrhagic necrosis | 1 | 2.5 |
| Multiple bilateral basal ganglia ischemic necrosis | 1 | 2.5 |
| Bilateral parieto-occipital white matter small vessel ischemia | 1 | 2.5 |
| Ventriculitis | 2 | 5.0 |
| Bilateral focal necrosis of white matter and basal ganglia | 1 | 2.5 |
| Bilateral periventricular deep white matter ischemia | 1 | 2.5 |
| Subdural effusion | 3 | 7.5 |
| Tuberous sclerosis | 2 | 5.0 |
| Multiple white matter necrosis & tuberous sclerosis | 2 | 5.0 |
| Thalamic and basal ganglia infarction | 2 | 5.0 |
| Diffuse temporo-occipital restricted diffusion | 3 | 7.5 |
| Bilateral basal ganglia infarction | 2 | 5.0 |
| Subdural empyema | 2 | 5.0 |
| Diffuse parieto-frontal necrosis | 1 | 2.5 |
| Bilateral parietal necrosis | 1 | 2.5 |
| Parietal necrosis | 3 | 7.5 |
| Diffuse necrotic foci | 1 | 2.5 |
| Tri hydrocephalus and cerebral necrosis | 1 | 2.5 |
| Periventricular restricted edema | 1 | 2.5 |
| Basal ganglia necrosis | 1 | 2.5 |
| Diffuse bilateral cortical necrosis | 1 | 2.5 |
| Temporal brain abscess | 1 | 2.5 |
| Tri ventricular hydrocephalus | 2 | 5.0 |
| Ventriculitis and triventricular hydrocephalus | 1 | 2.5 |
| Cerebral abscess | 1 | 2.5 |
| Total | 40 | 100.0 |

Table-4: Distribution of children' demographic characteristics according to general diagnosis.

| Variables | Hydrocephalus | | Necrosis | | Abscess | | Effusion | | *P-value |
|-------------------|---------------|---------|----------|---------|---------|---------|----------|---------|----------|
| | Number | Percent | Number | Percent | Number | Percent | Number | Percent | |
| Age | | | | | | | | | |
| Neonate | 1 | 8.3 | 5 | 26.3 | 1 | 16.7 | 0 | - | 0.4 |
| Infant | 7 | 58.3 | 4 | 21.1 | 1 | 16.7 | 2 | 66.7 | |
| Less than 5 years | 1 | 8.3 | 5 | 26.3 | 2 | 33.3 | 0 | - | |
| 5-10 years | 3 | 25.0 | 5 | 26.3 | 2 | 33.3 | 1 | 33.3 | |
| Gender | | | | | | | | | |
| Male | 7 | 58.3 | 8 | 42.1 | 2 | 33.3 | 1 | 33.3 | 0.7 |
| Female | 5 | 41.7 | 11 | 57.9 | 4 | 66.7 | 2 | 66.7 | |

*Fishers exact test.

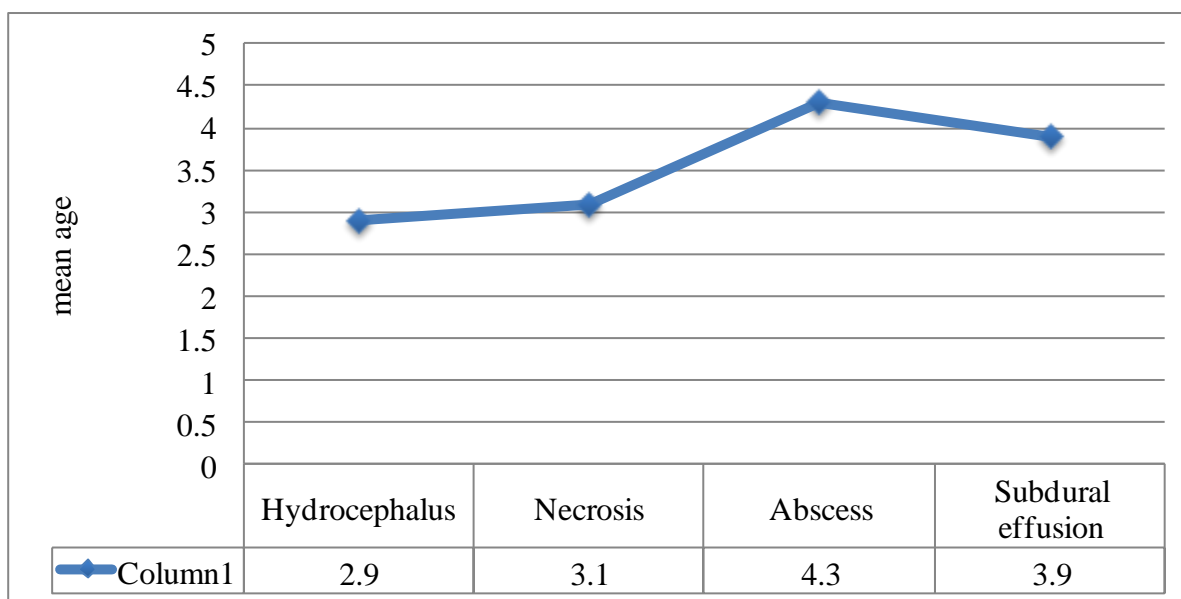


Fig.6: Mean age distribution according to general diagnosis.

4- DISCUSSION

Meningitis continues to be an important disease throughout the world and can be a life-threatening emergency if not suspected, appropriately diagnosed, and managed expeditiously (12). In children, MRI is widely accepted for its safety and high soft-tissue resolution. It is better than sonography in determining the presence of the complications, mainly in the posterior fossa. It has the additional benefit of not utilizing ionizing radiation (13). Imaging of brain used principally to recognize complications of meningitis and to eliminate focal brain lesions mimicking meningitis. The present study showed that necrosis was the main MRI finding for children with complicated meningitis, followed by hydrocephalus, abscess and subdural effusion. These findings are consistent with results of Dietemann et al. (14) study in Spain which stated that MRI is valuable to demonstrate the presence meningeal diseases, especially among children. The current study revealed that frequent MRI findings among children with meningitis were subdural effusion,

diffuse temporal-occipital restricted diffusion, and parietal necrosis. These findings are close to results of Kamra et al. (15) study in India which reported that MRI is an important technique for detection and characterization of infectious meningitis of different etiology. MRI is the best imaging tool to assess the intracranial and intraspinal meninges and meningitis (16). In one study designed and achieved by Appenzeller et al. (17) were presented a comparison between MRI and CT. MRI has been observed to be more useful than computed tomography (CT) in describing and outlining the lesions. In addition, it show pathologies not regularly detected on CT. Also, the appearance of focal findings on MRI indicates real cerebral disease, which is an essential feature in differentiating drug complicating effects or primary psychiatric disease. In the present study, the higher mean age of children was related with MRI brain abscess and lower mean age of them was related to MRI hydrocephalus. This is similar to results of Vaswani et al. (18) study in Pakistan. The common age groups of children with meningitis in our study were neonate and

newborn child age with slight female predilection. These results were in lining with reports of Brouwer et al. (19) considered in the Netherlands. There was a dramatic shift in the meantime of cases of bacterial meningitis, from 15 months of age in 1986 to 25 years old in 1995, in light of the fact that most cases of Haemophilus meningitis reported before immunization occurred in babies and children aged 6 to 12 months. This notice highlighted the importance of immunization and showed the necessity for the improvement of compelling conjugate antibodies against the other basic meningel pathogens (19).

4-1. Limitations of the study

There are some limitations in the present study such as loss of follow up in some cases; it was a single center study, infrequent availability of general anesthesia and motion artifacts in some cases. However the results of this study encouraging physicians and radiologists to apply MRI as a diagnostic choice of meningitis among children. Further national multi-center studies on MRI findings of childhood meningitis must be supported.

5- CONCLUSION

According to the results of this study, magnetic resonance imaging is a useful diagnostic tool for detection and characterization of childhood meningitis of different etiology. The main MRI findings of children with complicated meningitis were necrosis, hydrocephalus, abscess and subdural effusion. Age of children with meningitis increased with the brain abscess and decreased with hydrocephalus.

6- CONFLICT OF INTEREST: None.

7- REFERENCES

1. Pickering LK, Baker CJ, Kimberlin DW. Red book: 2012 report of the Committee

on Infectious Diseases. 29th ed. American Academy of Pediatrics; 2012:345–52.

2. Prober CG, Dyner L: Acute bacterial meningitis beyond the neonatal period. In Kliegman RM, Stanton BF, Schor NF, St. Geme JWIII, Behrman RE, eds. Nelson Textbook of pediatrics. 19thed. Philadelphia, PA: Elsevier Saunders; 2011: 2087–95.

3. Prober CG, Dyner L. Eosinophylic meningitis. In kliegman RM, Stanton BF, Schor NF, St. Geme JWIII, Behrman RE, eds. Nelson Text book of Pediatrics.19th ed. Philadelphia, PA: Elsevier Saunders; 2011: 2097–9.

4. Van de Beek D, de Gans J, Spanjaard L, Weisfelt M, Reitsma JB, Vermeulen M. Clinical features and prognostic factors in adults with bacterial meningitis. N Engl J Med 2004; 351(18):1849-59.

5. Heckenberg SG, de Gans J, Brouwer MC, Weisfelt M, Piet JR, Spanjaard L, et al. Clinical features, outcome, and meningococcal genotype in 258 adults with meningococcal meningitis: a prospective cohort study. Medicine. 2008; 87(4):185-92.

6. Dalal A, Ahmad H. Austrian syndrome (pneumococcal pneumonia, meningitis, and endocarditis): a case report. Am J Med Sci. 2008; 336(4): 354-5.

7. Hoffman O, Weber JR. Review: Pathophysiology and treatment of bacterial meningitis. Ther Adv Neurol Disord. 2009; 2(6):401-12.

8. Schmidt H, Heimann B, Djukic M, Mazurek C, Fels C, Wallesch CW, et al. Neuropsychological sequelae of bacterial and viral meningitis. Brain 2006; 129: 333-45.

9. Kastrup O, Wanke I, Maschke M. Neuroimaging of infections. NeuroRx 2005; 2(2): 324–32.

10. Grimwood K, Anderson P, Anderson V, Tan L, Nolan T. Twelve year outcomes following bacterial meningitis: further evidence for persisting effects. Arch Dis Child. 2000; 83(2):111-6.

11. Gaviani P, Schwartz RB, Hedley-Whyte ET, Ligon KL, Robicsek A, Schaefer P, et al. Diffusion-weighted imaging of fungal

cerebral infection. *AJNR Am J Neuroradiol* 2005; 26(5):1115–21.

12. Nudelman Y, Tunkel AR. Bacterial meningitis: epidemiology, pathogenesis and management update. *Drugs* 2009; 69 (18): 2577–96.

13. Yikilmaz A, Taylor GA. Sonographic findings in bacterial meningitis in neonates and young infants. *Pediatr Radiol* 2008; 38(2):129-37.

14. Dietemann JL, Correia Bernardo R, Bogorin A, Abu Eid M, Koob M, Nogueira T, et al. Normal and abnormal meningeal enhancement: MRI features. *J Radiol* 2005; 86(11):1659-83.

15. Kamra P, Azad R, Prasad KN, Jha S, Pradhan S, Gupta RK. Infectious meningitis: prospective evaluation with magnetization transfer MRI. *Br J Radiol* 2004; 77(917):387-94.

16. Meltzer CC, Fukui MB, Kanal E, Smirniotopoulos JG. MR imaging of the

meninges. Part I. Normal anatomic features and nonneoplastic disease. *Radiology* 1996; 201: 297-308.

17. Appenzeller S, Kobayashi E, Costallat LTL, Zanardi VDA, Neto JMR, Damasceno BP, et al. Magnetic resonance imaging in the evaluation of patients with aseptic meningoencephalitis and connective tissue disorders. *Arq. Neuro-Psiquiatr* 2000; 58 (1): 45-51.

18. Vaswani AK, Nizamani WM, Ali M, Aneel G, Shahani BK, Hussain S. Diagnostic Accuracy of Contrast-Enhanced FLAIR Magnetic Resonance Imaging in Diagnosis of Meningitis Correlated with CSF Analysis. *ISRN Radiology* 2014, Article ID 578986, 7 pages.

19. Brouwer MC, Tunkel AR, van de Beek D. Epidemiology, Diagnosis, and Antimicrobial Treatment of Acute Bacterial Meningitis. *Clin Microbiol Rev.* 2010; 23(3):467-92.