

The Study of *Lophomonas Blattarum* Infection in Children with Respiratory Symptoms: A Descriptive Clinical Study in North East of Iran

Nafise Ghaffarian¹, Elham Bakhtiari², Fariba Berenji³, Maryam Nakhaei⁴, Batool Nakhaei⁵, Faride Jamali-Behnam⁶, *Seyed Javad Sayedi¹

¹Departments of Pediatrics, Faculty of Medicine, Mashhad University of Medical Sciences, Mashhad, Iran. ²Eye Research Center, Mashhad University of Medical Sciences, Mashhad, Iran. ³Department of Parasitology, Faculty of Medicine, Mashhad University of Medical Sciences, Mashhad, Iran. ⁴Department of Parasitology, Student Research Committee, Faculty of Medicine, Mazandaran University of Medical Sciences, Sari, Iran. ⁵Inflammation and Inflammatory Diseases Research Center, Mashhad University of Medical Sciences, Mashhad, Iran. ⁶Surgical Oncology Research Center, Mashhad University of Medical Sciences, Mashhad, Iran.

Abstract

Background: *Lophomonas blattarum* is protozoan generally parasitizes in the intestinal tracts of some arthropods. It can infect adults and children with unspecific respiratory symptoms. We aimed to investigate the frequency of *Lophomonas blattarum* in children with respiratory symptoms in North East of Iran.

Materials and Methods: One hundred fifty-six children with respiratory symptoms were investigated in a descriptive-analytical study using Bronchoalveolar lavage (BAL) according to enumeration method in March 2016 to March 2017. Data was collected via a check list, prospectively. All had Bronchoscopy and chest X-ray. The data were analyzed using SPSS program.

Results: Of the 156 studied children, 40.4% (n=63) of patients with the average age of 5.11±2.9 years were positive for *L. blattarum* infection. In positive cases, 42.9% (n=27) were male. There was a significant relationship between gender and *Lophomonas* infection (p=0.0006). The most common respiratory symptoms were cough, fever, wheeze and tachypnea. Radiography of infected patients showed pulmonary infiltration (16.7%), unilateral lung hyperinflation (23.1%), consolidation (19.9%), and lung collapse (14.7%). Underlying diseases were detected in 4 infected patients. Bronchoscopy showed abnormal results in 22 patients (14.1%). Most common abnormalities were in order: mucus plaque (22.7%), left bronchomalacia (18.2%), left bronchial stenosis (18.2%) and foreign body aspiration (13.6%).

Conclusion: Generally, 40.4% of children with respiratory symptoms were positive for *L. blattarum* infection. It is suggested to consider *L. blattarum* as a cause of pulmonary infections in patients with pulmonary symptoms.

Key Words: Children, Bronchoalveolar Lavage, *Lophomonas Blattarum*, Iran.

*Please cite this article as: Ghaffarian N, Bakhtiari E, Berenji F, Nakhaei M, Nakhaei B, Jamali-Behnam F, et al. The Study of *Lophomonas Blattarum* Infection in Children with Respiratory Symptoms: A Descriptive Clinical Study in North East of Iran. *Int J Pediatr* 2018; 6(6): 7797-7802. DOI: **10.22038/ijp.2018.29199.2555**

*Corresponding Author:

Seyed Javad Sayedi (M.D), Assistant Professor of Pediatrics Pulmonology, Department of Pediatrics, Faculty of Medicine, Mashhad University of Medical Sciences, Mashhad, Iran.

Email: SayediJ@mums.ac.ir

Received date: Jan.13, 2018; Accepted date: Mar. 22, 2018

1- INTRODUCTION

Respiratory infections are one of the common infectious diseases in children. Millions of children suffer from respiratory infection with considerable rate of mortality. Parasitic infections are common in children aged less than 5 years. Many parasitic infections have unspecific symptoms (1). *Lophomonas blattarum* (*L. blattarum*) is single-cell protozoan that generally parasitizes in the intestinal tracts of some arthropods such as cockroaches and termites (2). It is a member of the order Hypermastigida in the Mastigophora protozoa (3). *L. blattarum* is a protozoa with 20-60 micrometers long and 12-20 micrometers wide. It has granular cytoplasm containing phagocytized material. *L. blattarum* has several flagellates with different rotation directions. In humans, *L. blattarum* can infect various tissues such as sinuses, reproductive system and respiratory system. The most common clinical symptoms in infected humans are fever, cough, and sputum expectoration (4).

Radiography may show pneumonia signs, bronchiectasis, pulmonary abscess, and pleural effusion. Because of the similar symptoms it is difficult to distinguish *L. blattarum* from other common infections. It has been concluded that microscopic examination of the respiratory secretions is essential for diagnosis of *L. blattarum* (5-7). So *L. blattarum* can be detected by bronchoscopic brush smears, bronchoscopic biopsy smears, or bronchoalveolar lavage (BAL). Pharmacotherapy which is used for other common infections is not effective for *L. blattarum* infection (8). Accurate and on-time diagnosis is very important for treatment of *L. blattarum* infection. Metronidazole or tinidazole are usually prescribed in infected patients and lead to good prognosis (9, 10). There is not any document about the prevalence of *L. blattarum* in Iranian children.

To offer new insight into the *L. blattarum* infection in children, the present study was carried out to estimate the prevalence of *L. blattarum* in children with respiratory symptoms as well as bronchoscopy indication.

2- MATERIALS AND METHODS

2-1. Method

This, 1-year, descriptive analytical study was performed in pulmonary clinic at Dr. Sheikh hospital, Mashhad University of Medical Sciences, Mashhad, Iran, from March 2016 to March 2017, prospectively. The study participants included were 156 children, aged between 1 month and 18 years with pulmonary symptoms including chronic wheezing, cough, asthma, chest pain, weight loss and sputum as well as bronchoscopy indication. The diagnosis of *L. blattarum* infection was documented based on a positive direct smear of BAL specimens. Alveolar contents of the patients were extracted after bronchoscopy and normal saline wash. At first, direct sample was obtained to evaluate the presence of *L. blattarum*. Giemsa staining was also performed on the smears (11). All BAL samples were sent to laboratory immediately. Antimicrobial therapy was initiated upon the diagnosis of *L. blattarum* infection. Present study was approved by Mashhad University of Medical Sciences Ethical committee (ID-code: IR.MUMS.fm.REC.1395.402). Written informed consent was obtained from parents of all included patients. Patients were excluded if BAL sample extraction was not possible.

2-2. Data analysis

Statistical analysis was performed using SPSS software version 16 (SPSS Institute, Inc., Chicago, IL, USA). All experimental values are presented as Means \pm standard deviation (SD). Chi-squared test was used to screen associations of qualitative

variables. P values less than 0.05 was considered significant.

3- RESULTS

Of the 156 children, 56.4% (n=88) were male. The average age of patients was 4.93 ± 0.26 years; 63 samples (40.4%) were positive for *L. blattarum* infection. Among positive BAL samples for *L. blattarum*, 42.9% (n=27) were male and 57.1% (n=36) were female. There was a significant relationship between gender and *L. blattarum* infection ($p=0.0006$). The average age of infected patients was 5.11 ± 2.9 years. Demographic characteristics of patients are shown in **Table.1**. Infected patients were classified in four age groups including: less than 4, 4-8, 8-12, and 12-16 years old. There was not any significant relationship between age and *L. blattarum* infection ($p>0.05$). Results are shown in **Figure.1**. The most common clinical symptoms in patients with positive *L. blattarum* were in order: cough (87.3%), fever (23.8%), tachypnea

(9.5%), and wheeze (6.3%). Radiography of infected patients showed other symptoms including pulmonary infiltration (19%), unilateral lung hyperinflation (19%), consolidation (17.5%), and lung collapse (15.9%). Among 63 infected patients with *L. blattarum* only 4 patients (6.34%) had underlying diseases including renal disease, cystic fibrosis, tuberculosis and William Campbell. There was not any significant relationship between underlying diseases and *L. blattarum* infection ($p>0.05$).

Bronchoscopy showed abnormal results in 22 patients (14.1%). Detected abnormality were in order: mucus plaque in 5 patients (22.7%), left bronchomalacia in 4 patients (18.2%), left bronchial stenosis in 4 patients (18.2%), foreign body aspiration in 3 patients (13.6%), polyp in 1 patient (4.5%), tracheomalacia in 1 patient (4.5%), bilateral bronchomalacia in 1 patient (4.5%), fistula in 1 patient (4.5%), truncus intermedius in 1 patient (4.5%), and bronchial displacement in 1 patient (4.5%).

Table-1: Demographic characteristics of children with respiratory symptoms

Variables	All population Mean \pm SD	Infected children Mean \pm SD
Age (year)	4.93 \pm 0.26	5.11 \pm 2.9
Gender		
Male	88 (56.4%)	27 (42.9%)
Female	68 (43.6%)	36 (57.1%)
Total	156	63

SD: Standard deviation.

Table-2: The relationship between demographic variables and *L. blattarum* infection

Demographic variables	Infection prevalence	P-value
Gender		
Male	27 (42.9%)	0.0006*
Female	36 (57.1%)	
Age (year)		
<4	26 (41.2%)	0.4
4-8	29 (46.03%)	
8-12	6 (9.5%)	
>12	2 (3.17%)	

* Chi square test.

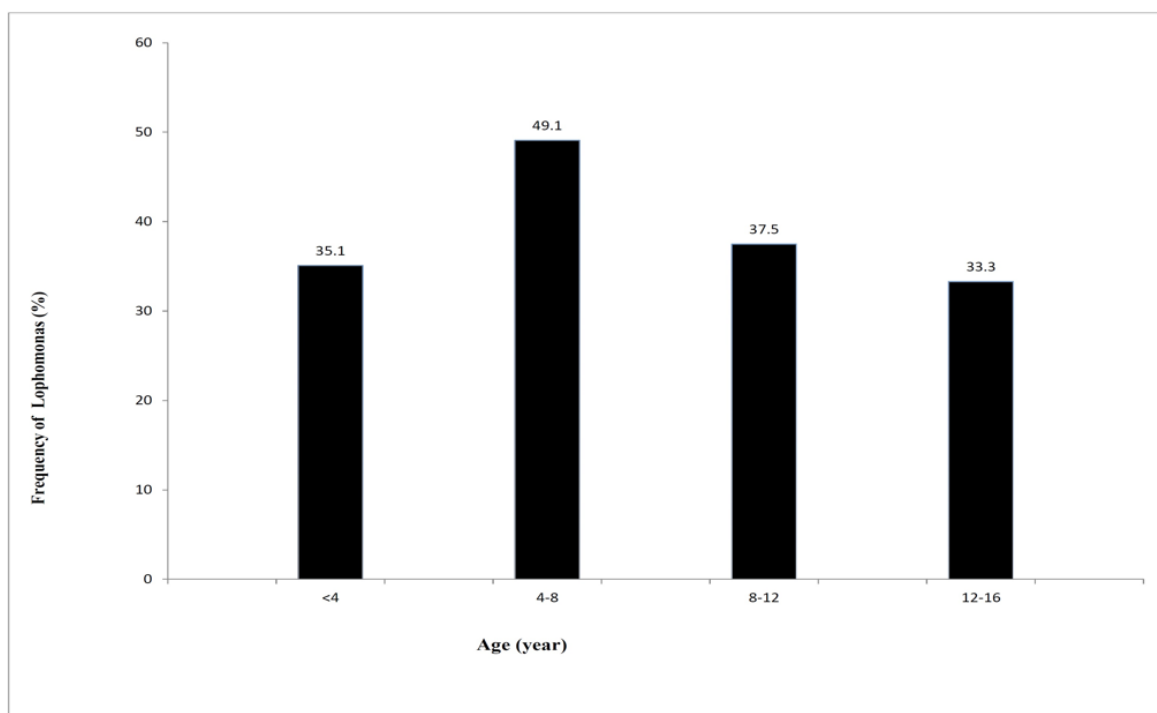


Fig.1: The frequency of *L. blattarum* in different age groups of children with respiratory symptoms (percentage).

4- DISCUSSION

One hundred fifty- six children with pulmonary symptoms were studied using BAL sample, for evaluation the frequency of *L. blattarum* in North East of Iran. Unexpectedly 40.4% of patients were positive for *L. blattarum* infection. Bronchoscopy showed abnormality in 14.1% of patients. Recently, the prevalence of pulmonary infections caused by protozoa has been increased in the worldwide. Overall, there are few studies reporting the prevalence of *L. blattarum* infection (4, 11). It has been reported that the prevalence of *L. blattarum* infection is between 8-37.5% depending on the geographical region (4, 11). To our knowledge, present study is the first report about the frequency of *L. blattarum* infection in Iranian Children. Only one study in Peru reported some cases of Lophomonas infection in pediatrics with no report of infection rate (12). Berenji et al. in a study on 133 patients with

pulmonary infections and sinusitis resistant to treatments reported that 50 patients were positive for *L. blattarum* infection (11). In another study in Turkey on 110 immunosuppressed patients using BAL samples, it was reported that 8.2% of patients were positive for flagellated protozoa including Lophomonas (4). According to another study in Spain, the rate of *L. blattarum* infection in HIV-positive patients was twice that of HIV-negative cases (6). *L. blattarum* infection almost pretended with non-specific symptoms, therefore *L. blattarum* infection should be considered in patients with pulmonary symptoms including pulmonary infection, asthma, fever, coughs and dyspnea (2, 4, 11). The frequency of infection in present study was rather high. It may be due to the specific condition of Mashhad city which is a crowded city and is an international center of religious tourism. Many researchers suggest that similarity of *L. blattarum* to bronchial

epithelial cells is one of the causes of parasite ignoring (5, 13-15). Therefore, the presence of flagellated protozoa in patients with pulmonary symptoms should be considered as *Lophomonas* infection.

4-1. Limitations of the study

Unfortunately there was not complete equipment in our center, therefore BAL samples were sent to another center for microscopic analysis. Also, because of operator dependency, there was the risk of misdiagnosis of *L. blattarum*.

5- CONCLUSION

Overall, the frequency of *L. blattarum* in children with pulmonary symptoms was 40.4%. The infection had more frequency in females. There is a possibility that many of the infected patients with *L. blattarum* were neglected and remained undiagnosed. It is necessary to consider *L. blattarum* as a cause of pulmonary infections. More studies with larger sample size in Iran and other countries are suggested.

6- ABBREVIATIONS

BAL: Bronchoalveolar lavage,
L blattarum: *Lophomonas blattarum*.

7- AUTHORS CONTRIBUTION

Seyed Javad Sayedi, Nafiseh Ghaffarian, Fariba Berenji: conception or design,

Elham Bakhtiari, Nafiseh Ghaffarian, Faride Jamali-Behnam: acquisition, analysis,

Elham Bakhtiari, Seyed Javad Sayedi, Nafiseh Ghaffarian, Fariba Berenji, Faride Jamali-Behnam: drafting the work.

Elham Bakhtiari, Seyed Javad Sayedi, Nafiseh Ghaffarian, Fariba Berenji, Faride Jamali-Behnam: final approval.

8- CONFLICT OF INTEREST: None.

9- ACKNOWLEDGMENT

This work was financially supported by a research grant (Grant No.950575) from Mashhad University of Medical Sciences, Mashhad, Iran.

10- REFERENCES

1. Ferkol T, Schraufnagel D. The global burden of respiratory disease. *Annals of the American Thoracic Society*. 2014;11(3):404-6.
2. Martinez-Giron R, van Woerden HC. *Lophomonas blattarum* and bronchopulmonary disease. *Journal of medical microbiology*. 2013;62(11):1641-48.
3. Gile GH, Slamovits CH. Phylogenetic position of *Lophomonas striata* Bütschli (Parabasalia) from the hindgut of the cockroach *Periplaneta americana*. *Protist*. 2012;163(2):274-83.
4. Kilimcioglu AA, Havlucu Y, Girginkardesler N, Çelik P, Yereli K, Özbilgin A. Putative bronchopulmonary flagellated protozoa in immunosuppressed patients. *BioMed research international*. 2014;2014: 1-5.
5. Yao G, Zhou B, Zeng L. Imaging characteristics of bronchopulmonary *Lophomonas blattarum* infection: case report and literature review. *Journal of thoracic imaging*. 2009;24(1):49-51.
6. Ribas A, Martínez-Girón R, Sánchez-Del-Río J, González-Alonso D. Protozoal forms in the sputum of immunocompromized patients. *Scandinavian journal of infectious diseases*. 2005;37(3):205-10.
7. Martínez-Girón R, van Woerden HC, Doganci L. *Lophomonas* misidentification in bronchoalveolar lavages. *Internal Medicine*. 2011;50(21):2721.
8. Wang Y, Tang Z, Ji S, Zhang Z, Chen J, Cheng Z, et al. Pulmonary *Lophomonas blattarum* infection in patients with kidney allograft transplantation. *Transplant international*. 2006;19(12):1006-13.
9. Martínez-Girón R, Esteban J, Ribas A, Doganci L. Protozoa in respiratory pathology: a review. *European Respiratory Journal*. 2008;32(5):1354-70.

10. Guozhong Y. Bronchopulmonary infection with *Lophomonas blattarum*: two cases report and literature review. *Journal of Medical Colleges of PLA*. 2008;23(3):176-82.
11. Berenji F, Fata A, Vakili V, Sayedi SJ, Abdollahi B, Imanfar H, et al. Unexpected high rate of *Lophomonas blattarum* in resistant experimental y salud pública. 2010;27(4):575-7.
13. Martínez-Girón R, Van Woerden HC. Bronchopulmonary lophomoniasis: emerging disease or unsubstantiated legend? *Parasites & vectors*. 2014;7(1):284.
14. Xue J, Li Y-L, Yu X-M, Li D-K, Liu M-F, Qiu J-F, et al. Bronchopulmonary upper and lower respiratory infection. *Health Sciences*. 2016;5(9):74-80.
12. Zerpa R, Ore E, Patiño L, Espinoza YA. *Lophomonas* sp. in respiratory tract secretions in hospitalized children with severe lung disease. *Revista peruana de medicina* infection of *Lophomonas blattarum*: a case and literature review. *The Korean journal of parasitology*. 2014;52(5):521.
15. Zhu Y-f, Wang C-b, Xie B-y, Chen S-x. A case of bronchopulmonary infection caused by hypermastigote. *Chinese Journal of Infection and Chemotherapy*. 2007;2:016.